

15th Yahya Cohen Memorial Lecture — The Relationship between the Air-bone Gap and the Size of Superior Semicircular Canal Dehiscence

Heng Wai Yuen,^{1,2}MRCSE, MMed(ORL), DOHNS, Rudolf Boeddinghaus,³FCRad(SA), FRANZCR, FRCR, Robert H Eikelboom,^{1,2}MAppSc, PhD, Marcus D Atlas,^{1,2}MBBS, FRACS

Abstract

Introduction: This study aimed to examine the relationship between the air-bone gap (ABG) and the size of the superior semicircular canal dehiscence (SSCD) as measured on a computed tomography (CT) scan. **Materials and Methods:** The study design was a case series with chart review. Twenty-three patients (28 ears) from a tertiary referral centre were diagnosed with SSCD. The size of the dehiscence on CT scans and the ABG on pure-tone audiometry were recorded. **Results:** The size of the dehiscence ranged from 1.0 to 6.0 mm (mean, 3.5 ± 1.6 mm). Six ears with a dehiscence measuring less than 3.0 mm did not have an ABG (0 dB). The remaining 18 ears showed an average ABG at 500, 1000, and 2000 Hz ($AvABG_{500-2000}$) ranging from 3.3 to 27.0 dB (mean, 11.6 ± 5.7 dB). The analysis of the relationship between the dehiscence size and $AvABG_{500-2000}$ revealed a correlation of $R^2 = 0.828$ ($P < 0.001$, quadratic fit) and $R^2 = 0.780$ ($P < 0.001$, linear fit). Therefore, the larger the dehiscence, the larger the ABG at lower frequencies on pure-tone audiometry. **Conclusion:** In SSCD patients, an ABG is consistently shown at the low frequency when the dehiscence is larger than 3 mm. The size of the average ABG correlates with the size of the dehiscence. These findings highlight the effect of the dehiscence size on conductive hearing loss in SSCD and contribute to a better understanding of the symptomatology of patients with SSCD.

Ann Acad Med Singapore 2011;40:59-64

Key words: CT scan, Hyperacusis, Tullio's phenomenon, Vertigo

Introduction

Superior semicircular canal dehiscence (SSCD) can result in a characteristic constellation of vestibular and auditory features, including autophony, oscillopsia, and vertigo, and characteristic eye movements induced by sound and pressure changes.¹⁻³ Patients with SSCD also show lowered thresholds for vestibular-evoked myogenic potentials (VEMPs) and a heightened sensitivity to bone-conducted sounds in the presence of normal middle ear function and intact acoustic reflexes.³⁻⁵ These patients can have conductive hearing loss and often show an air-bone gap (ABG) at the low frequency on pure-tone audiometry testing.^{6,7}

The hypothetical explanation for these signs and symptoms are based on the proposed mechanism that the dehiscence acts as a mobile third window into the inner ear, exposing the membranous semicircular canal to the

middle cranial fossa. This creates abnormal sound pathways and allows abnormal flow of endolymph in the superior canal in response to positive or negative pressures.^{1,8,9} At the same time, it is believed that dissipation of acoustic energy through the dehiscence creates an ABG and an apparent conductive hearing loss.⁶⁻⁸ However, not all patients with SSCD show an ABG on audiometry.^{2,10-12} The pathophysiologic mechanism underlying this conductive hearing loss has not been fully elucidated.

High-resolution computed tomography (CT) scans of the temporal bones, especially with collimation of about 0.5 mm and reformatted in the plane of the superior semicircular canal, are of proven value in the evaluation and diagnosis of SSCD.^{13,14} In this study, we examine the relationship between the dehiscence size as measured on CT scans and the ABG in our series of SSCD patients.

¹Ear Science Institute Australia, Ear Sciences Centre, School of Surgery, University of Western Australia, Nedlands, Western Australia, Australia

²Department of Otolaryngology – Head and Neck Surgery, Sir Charles Gairdner Hospital, Nedlands, Western Australia, Australia

³Perth Radiological Clinic, Subiaco, Western Australia, Australia

Address for Correspondence: Dr Heng Wai Yuen, Department of Otolaryngology-Head & Neck Surgery Changi General Hospital

2 Simei Street 3, Singapore 529889.

Email: heng_wai_yuen@cgh.com.sg

Materials and Methods

Only patients diagnosed with SSCD were included in the study (Table 1). The criteria for determining the presence of dehiscence in our patients were as follows: (i) a history typical of SSCD; (ii) the presence of at least one physiologic indicator of SSCD, especially three-dimensional eye movement recordings or VEMPs; and (iii) the observation of dehiscence on a multiplanar CT scan. The diagnosis was also confirmed in some patients who underwent surgery. Institutional review board approval was obtained for a retrospective chart review of the patients identified at Sir Charles Gairdner and St John of God Subiaco Hospitals

in Perth, Australia. Patients who had previous middle ear exploration or surgery and patients who had previous attempted repair were excluded. All patients underwent extensive preoperative testing of both auditory and vestibular function. Only auditory test results are discussed here.

Audiometry

Pure-tone audiometry was performed over the frequency ranges of 250 to 8000 Hz for air conduction and 500 to 4000 Hz for bone conduction. We are refining our techniques to distinguish vibrotactile responses from true bone conduction thresholds at 250 Hz. The ABG was calculated for the

Table 1. Patient Demographics and Details of Dehiscence (n = 28)

Patient no.	Sex	Age (y)	Clinical signs/symptoms	Dehiscence		AvABG ₅₀₀₋₂₀₀₀ (dB)	Surgical repair	Postop AvABG ₅₀₀₋₂₀₀₀ (dB)	Remarks
				Side	Size (mm)				
1	M	41	Ap, HA, TP, V, AEEM+	R	1.5	3.3	-	-	bilateral
				L	1.0	0.0	-	-	
2	M	43	Ap, HA, TP, HS, V, AEEM+	R	4.5	11.7	Yes	8.3	Recurrence
			TP, AEEM+	R	5.0	15.0	-	-	
3	M	53	TP, V, AEEM+	L	2.5	0.0	Yes	0.0	
4	F	42	HA, TP, V, AEEM+	R	3.0	5.0	Yes	13.3	
5	F	41	Ap, HA, TP, AEEM+	R	3.0	6.7	-	-	
6	F	52	Ap, TP, HS, AEEM+	L	3.0	8.3	Yes	11.7	
7	M	35	HA, TP, AEEM+	L	5.0	13.3	Yes	1.7	Recurrence
			HA, TP, HS, AEEM+	L	2.0	3.3	-	-	
8	F	42	HA, TP, V, AEEM+	R	6.0	22.0	-	-	
9	F	45	Ap, HA, AEEM+	R	5.5	11.7	Yes	8.3	Bilateral
				L	6.0	13.3	Yes	10.0	
10	F	40	TP, AEEM+	R	4.0	8.3	-	-	
11	M	50	TP, V, AEEM+	R	3.5	8.3	-	-	
12	M	52	Ap, TP, AEEM+	L	1.5	5.0	-	-	
13	F	35	HA, TP, AEEM+	R	1.0	0.0	-	-	
14	F	54	HA, AEEM+	L	5.5	13.3	Yes	15.0	
15	M	51	TP, AEEM+	L	5.0	10.0	-	-	
16	M	36	Ap, V, AEEM+	L	2.0	0.0	-	-	
17	F	55	Ap, HA, TP, AEEM+	L	2.0	0.0	-	-	
18	M	42	HA, TP, AEEM+	L	3.0	8.3	Yes	3.3	VEMP threshold: 70 db
19	F	70	TP, HS, AEEM+	L	6.0	27.0	-	-	
20	F	40	TP, AEEM+	L	5.5	13.3	-	-	
21	M	68	Ap, HA, TP, AEEM+	R	2.5	0.0	-	-	Bilateral, VEMP threshold: 70 db
				L	4.5	10.0	-	-	
22	F	53	HA, AEEM+	L	2.0	3.3	Yes	0.0	VEMP threshold: 65 db
23	F	53	HA, TP, HS, V, AEEM+	L	3.0	3.3	-	-	

Ap: autophony; HA: hyperacusis; TP: Tullio phenomenon; HS: Hennebert sign; V: Valsalva-induced dizziness; AEEM+: auditory-evoked eye movements consistent with SSCD at 110 dB at one or more frequencies (0.5, 1, or 2 kHz).

following frequencies: 500, 1000, and 2000 Hz. Testing was performed in a soundproof booth using standard clinical procedures. Appropriate masking was used for bone conduction and, when needed, for air conduction. Speech discrimination was also tested for all subjects. None of the patients had middle ear or ossicular abnormality. All the patients had intact acoustic reflexes and/or a response to VEMPs in the affected ear.

Temporal Bone CT Scan

All the patients underwent a high-resolution, multidetector CT temporal bone scan at 0.625-mm collimation with 50 percent overlap, reconstructed at 0.3-mm increments in the axial plane. Dedicated sagittal oblique reformats in the plane of the superior semicircular canal were made on a digital imaging and communications in medicine (DICOM) viewer, and measurements of the size of the dehiscence were made from these reconstructions using electronic callipers on the DICOM viewer. A straight line subtending the arc of the dehiscent segment was measured (Fig. 1). Measurements were corrected to the nearest 0.5 mm.

Postoperative CT scans were not routinely performed; repeat CT scans and audiometric testing were performed in patients with recurring symptoms after SSCD repair. The size of recurrence and pure-tone thresholds were compared with their initial presentation with patients without recurrence and with patients who elected conservative management.

Statistical Analysis

All data were statistically analysed by using SPSS software (SPSS Inc, Chicago, IL). A linear and quadratic curve was fitted for an ABG versus the size of dehiscence.

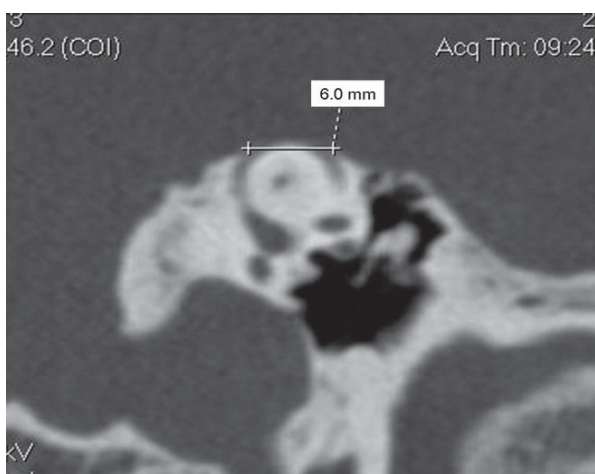


Fig. 1. A reformatted oblique sagittal CT scan image of patient number 8 showing a 6.0-mm dehiscence over the apex of the superior semicircular canal.

Results

Twenty-three patients met the criteria for this study. The patient demographics are shown in Table 1. Although all patients displayed positive auditory-evoked eye movements, VEMP threshold results were only available in 3 patients because this test was only recently introduced in the authors' department. Of the 23 subjects, 10 were male and 13 were female, with a mean age of 46 years (range, 35 to 70 years). The dehiscence was present only on the right side in seven cases, only on the left side in 13 cases, and bilaterally in 3 cases. The size of dehiscence ranged from 1.0 to 6.0 mm (mean, 3.5 ± 1.6 mm). Surgical repair was performed in 9 patients (10 ears), one of whom underwent bilateral repair. There were 2 patients with recurrent dehiscence, and they were included in the final analysis.

Six ears (21.4%) did not have an ABG (0 dB), whereas in 22 ears (78.6%), there was an average ABG at 500, 1000, and 2000 Hz ($AvABG_{500-2000}$) ranging from 3.3 to 27.0 dB (mean, 10.1 ± 6.0 dB) (Table 1). All 6 ears that did not have an ABG had a dehiscence smaller than 3.0 mm. In the remaining 18 ears (64.3%), the dehiscence measured 3.0 mm or larger; all showed an ABG on audiometry. The $AvABG_{500-2000}$ ranged from 3.3 to 27.0 dB (mean, 11.6 ± 5.7 dB). Figure 2 summarises the audiograms for the ears in this study. Of the 28 ears, 10 (36%) displayed bone-conduction thresholds that were negative or "better than 0" dB. All these ears had a dehiscence measuring larger than 3.0 mm.

Six of the ears had partial closure of the ABG after surgical repair. The mean ABG closure was 5.0 ± 3.3 dB. One ear had complete closure of the ABG. In contrast, 3 ears showed a mean increase in the ABG of 4.5 ± 3.4 dB postoperatively. One ear did not show any change in the ABG.

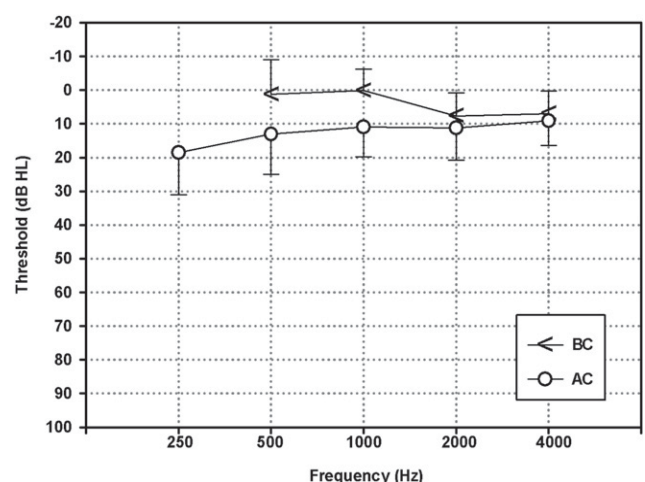


Fig. 2. An audiogram showing the mean hearing threshold responses for all ears at presentation. Results for air conduction (open circles) and bone conduction (right brackets) are shown with error bars showing standard deviation. The ABG was calculated for 500, 1000, and 2000 Hz as well as the average at these frequencies in each affected ear.

An analysis of the relationship between the size of the dehiscence and the $\text{AvABG}_{500-2000}$ using regression analysis (quadratic curve fit) showed a correlation coefficient (goodness of fit) of $R^2 < 0.828$ ($P < 0.001$) (Fig. 3A). A linear regression analysis also produced a significant relationship between the size of the dehiscence and $\text{AvABG}_{500-2000}$ with a coefficient of $R^2 = 0.780$ ($P < 0.001$) (Fig. 3B). These analyses suggest that the larger the dehiscence, the larger the ABG at the lower frequencies on pure-tone audiometry.

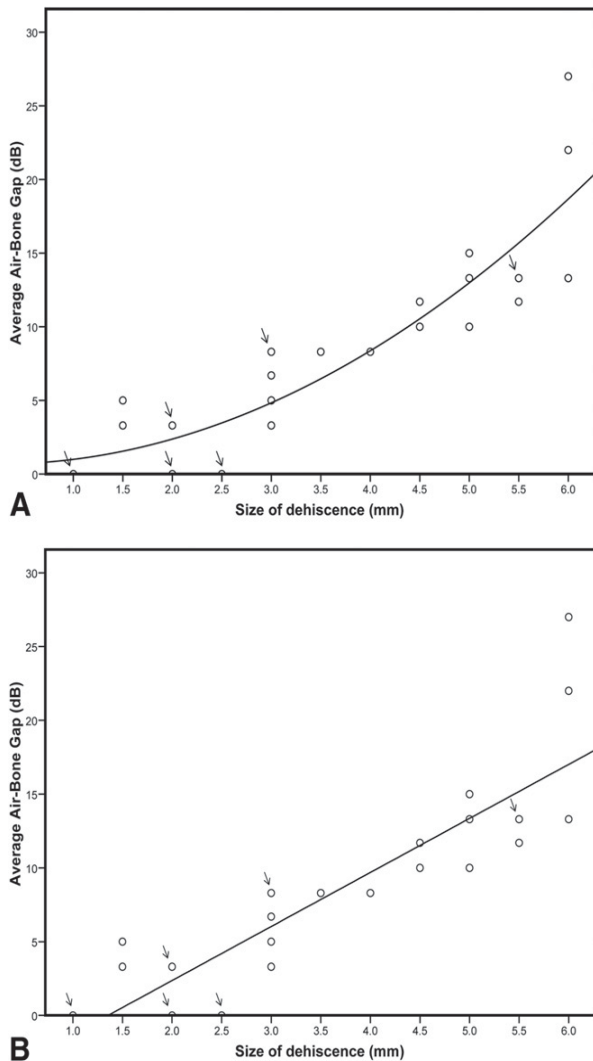


Fig. 3(A). The average ABG calculated at 500, 1000, and 2000 Hz is shown against the size of the dehiscence ($n = 28$). The line representing the best fit (quadratic regression) is shown ($y = 0.538x^2 - 0.235x + 0.694$, $R^2 = 0.828$). The arrows point to positions where there are dual data points. (B) The average ABG calculated at 500, 1000, and 2000 Hz is shown against the size of the dehiscence ($n = 28$). The line representing the best fit (linear regression) is shown ($y = 3.662x - 4.958$, $R^2 = 0.780$). The arrows point to positions where there are dual data points.

Discussion

In patients with SSCD, vertigo in association with sound and pressure changes is a major symptom.^{1,2} Vertigo and characteristic eye movements may be induced by loud noises (Tullio phenomenon) or by maneuvers that change middle ear (Hennebert sign) or intracranial pressure (Valsalva).¹⁵ Some patients with vestibular symptoms and signs indicative of SSCD have also noted auditory manifestations of the disorder. In a previous study, we found that the majority of patients with SSCD had auditory symptoms. However, there is no trend suggesting correlation of these auditory symptoms with the size of SSCD.¹⁶ These signs of “conductive hyperacusis” manifest on audiometry as boneconduction thresholds that are supranormal at frequencies below 2000 Hz (5 to 15 dB).^{4,7} An ABG can exist even when air-conduction thresholds are normal.³

The combination of increased air-conduction thresholds and decreased bone-conduction thresholds is believed to result in an ABG and conductive hearing loss in SSCD.^{8,17-19} Minor et al⁶ first described 4 patients with an ABG on audiometry caused by SSCD. The ABG averaged 24 dB from 250 to 4000 Hz, with normal middle ear function and intact bilateral acoustic reflexes. Three of these four patients had a dehiscence of larger than 3.0 mm.

Intuitively, it would seem logical that the larger the dehiscence, the more energy gets dissipated, resulting in a larger conductive hearing loss and larger ABG, but this phenomenon has not been addressed in the literature in a human clinical study. There have been preliminary suggestions that a very small dehiscence in chinchillas may not produce the same effect on hearing as a larger dehiscence, and experimental models suggest that large differences in hearing function can occur because of differences in the size of the dehiscence and the dimensions of the remnants of the semicircular canal on either side of the dehiscence.^{18,20}

In the 3 patients with bilateral SSCD, observation of a different ABG caused by different dehiscence sizes within the same patient provides strong evidence of the relationship between dehiscence size and ABG. Further evidence of the relationship between dehiscence size and the ABG is provided by the closure (at least partial) of the ABG when the dehiscence is repaired.^{6,10,21} In the study by Limb et al,¹⁰ 5 of 29 patients showed at least partial closure of the ABG after surgical repair of SSCD. Mikulec et al²¹ reported 4 out of 5 ears with improvement or resolution of conductive hearing loss after surgical repair of SSCD. Animal studies in chinchillas that showed reversibility of the conductive hearing loss created by the dehiscence¹⁸ also support the relationship between dehiscence size and ABG.

In the current study, of the 9 patients (10 ears) who underwent operative repair, 6 ears had partial closure of

the ABG, 3 ears showed an increase in the ABG, and one ear did not show any change in the ABG. One patient had complete closure of the ABG. We are unable to satisfactorily account for the increased ABG in the 3 patients. However, it is important to realise that the postoperative pure-tone thresholds may be influenced by surgical manipulation (especially canal plugging) and scarring or adhesions that may develop at the site of repair. Taken together, these results show that the ABG and conductive hearing loss could be at least partially reversed when the dehiscence is repaired.

In addition, the decrease in the ABG in the patients with recurrence of a dehiscence provides further evidence of a relationship between the size of the dehiscence and the average ABG on pure-tone audiometry. Of the 2 patients who had recurrences after surgical repair, one had a partial repair breakdown. The recurrent dehiscence was smaller than the initial one (2.0 mm vs 5.0 mm, respectively). The $\text{AvABG}_{500-2000}$ in this patient decreased from 13.3 dB at the initial presentation to 1.7 dB at 3 months postoperatively. This subsequently increased to 3.3 dB when the recurrence occurred after 6 months.

The other patient had a dehiscence measuring 4.5 mm at initial presentation, and the $\text{AvABG}_{500-2000}$ was 11.7 dB. After surgical repair, the $\text{AvABG}_{500-2000}$ decreased to 8.3 dB at 3 months. However, after 10 months, he developed recurrent symptoms. ACT scan showed complete material breakdown of the repair with a recurrent dehiscence measuring 5.0 mm. The $\text{AvABG}_{500-2000}$ at this time was 15.0 dB.

These 3 patients belonged to an earlier cohort whose repair consisted of canal resurfacing with only fascia and bone pate. Currently, we use bone wax for canal occlusion followed by fascia and bone substitute (hydroxyapatite) for repair. The subsequent cases have not had recurrences after a mean follow-up period of 51 months (range, 29 to 72 m).

From this study, we make the following conclusions: (i) in patients with a dehiscence smaller than 3.0 mm, there may not be a consistent ABG on audiometric testing; (ii) in patients with a dehiscence equal to or larger than 3.0 mm, there is a consistent ABG at the low frequencies of 500, 1000, and 2000 Hz; and (iii) the size of the ABG, when present, increases with the increasing size of the dehiscence.

High-resolution multiaxial reconstructed CT scans of the temporal bone have been shown to have high specificity and positive predictive value in the detection of SSCD.¹³ Nevertheless, different methods of measuring the size of the dehiscence are clearly being used in the literature, with a dehiscence size of up to 10.5 mm being reported.^{7,22} The method we used, measuring a straight line that subtends the arc of the dehiscence segment, is rapid and easily performed on most DICOM viewers, and is highly reproducible. However, there is inherent limitation in the spatial resolution of current

CT techniques. Our method will underestimate the size of the defect compared with a curvilinear measurement along the line of the semicircular canal. Nevertheless, alternative methods, such as measuring the angle subtended by the arc of the dehiscence segment or the curvilinear length along the segment of the circumference of the canal, are currently not practical. In addition, even with our largest dehiscence of 6.0 mm, the difference in measurement obtained by the different methods was negligible. Theoretically, this discrepancy will be larger for a large dehiscence. However, we did not encounter any dehiscence larger than 6.0 mm in our study. Given the implications of this study, it would be important to standardise measurement techniques in future studies.

It is agreed that a CT scan is not used as a screening tool for SSCD but rather as a corroborative tool to confirm a strong clinical suspicion of SSCD. All patients included in this study had other positive symptoms and signs indicative of SSCD apart from positive radiologic findings. Cloutier et al²³ recently reported that, in contrast to the findings of Belden et al,¹³ even thin-section CT scans and reformation in the plane of the superior semicircular canal may overestimate the prevalence of SSCD.

Very few of our patients with SSCD required surgery; surgery was only offered to severely affected patients. None of the patients were operated on for purely auditory symptoms. The decision to proceed with surgery was not related to the size of the dehiscence on preoperative CT scans. The surgical approach to repair of the dehiscence was via the middle fossa. The repairs were performed with canal plugging and resurfacing.

One criticism of our study would be the fact that no intraoperative measurement of the dehiscence was performed. However, we do not believe that this affects the validity of our results. First, all the patients in this study fulfilled the criteria for the diagnosis of SSCD; some of the patients went on to require surgical repair of the dehiscence. There was no negative exploration. In addition, although we could have measured the dehiscence with a small paper ruler, whether this would be more precise compared with CT measurements is open to question. Finally, although one could argue that some of the patients in this study, especially those with a small dehiscence, might have very thin bone beyond the resolution of CT scans covering the superior canal, no one could be absolutely sure unless every patient were surgically explored. Nevertheless, we do not believe that we could dismiss these patients who fulfil all the criteria for SSCD as not having the condition. The significance of any layer of very thin bone over the SSCD in these symptomatic patients is not known.

Obviously, other factors could also contribute to the conductive hearing loss observed in patients with SSCD, such as the position and location of the dehiscence.^{7,20,22} At

the same time, because the affected area over the superior canal is typically dumbbell shaped,⁴ we believe that the ideal method of measuring the size of the dehiscence would be using the surface area. The varying width (hence surface area) of the dehiscence will have an impact on the transfer of acoustic energy and hence the ABG.

It is anticipated that as imaging technology improves, more detailed measurement and evaluation of the dehiscence will be possible, providing further insight into the effect of the dehiscence size on conductive hearing loss.

Conclusion

Although patients with SSCDs that are smaller than 3.0 mm do not consistently show an ABG on audiometric testing, those with a dehiscence equal to or larger than 3.0 mm show a consistent ABG at low frequencies. The average ABG correlates with the size of the dehiscence as measured on CT scans. These findings may contribute to the understanding of symptom variability in SSCD. Future studies in human subjects or animal models will need to take this into consideration to match or standardise the sizes of the dehiscence.

REFERENCES

- Minor LB, Solomon D, Zinreich JS, Zee DS. Sound- and/or pressure-induced vertigo due to bone dehiscence of the superior semicircular canal. *Arch Otolaryngol Head Neck Surg* 1998;124:249–58.
- Minor LB. Clinical manifestations of superior semicircular canal dehiscence. *Laryngoscope* 2005;115:1717–27.
- Streubel SO, Cremer PD, Carey JP, Weg N, Minor LB. Vestibular-evoked myogenic potentials in the diagnosis of superior canal dehiscence syndrome. *Acta Otolaryngol* 2001;121(Suppl):41–9.
- Minor LB. Superior canal dehiscence syndrome. *Am J Otol* 2000;21:9–19.
- Watson SR, Halmagyi GM, Colebatch JG. Vestibular hypersensitivity to sound (Tullio phenomenon): structural and functional assessment. *Neurology* 2000;54:722–8.
- Minor LB, Carey JP, Cremer PD, Lustig LR, Streubel SO, Ruckenstein MJ. Dehiscence of bone overlying the superior canal as a cause of apparent conductive hearing loss. *Otol Neurotol* 2003;24:270–8.
- Mikulec AA, McKenna MJ, Ramsay MJ, Rosowski JJ, Herrmann BS, Rauch SD, et al. Superior semicircular canal dehiscence presenting as conductive hearing loss without vertigo. *Otol Neurotol* 2004;25:121–9.
- Rosowski JJ, Songer JE, Nakajima HH, Brinsko KM, Merchant SN. Clinical, experimental, and theoretical investigations of the effect of superior semicircular canal dehiscence on hearing mechanisms. *Otol Neurotol* 2004;25:323–32.
- Hirvonen TP, Carey JP, Liang CJ, Minor LB. Superior canal dehiscence: mechanisms of pressure sensitivity in a chinchilla model. *Arch Otolaryngol Head Neck Surg* 2001;127:1331–6.
- Limb CJ, Carey JP, Srireddy S, Minor LB. Auditory function in patients with surgically treated superior semicircular canal dehiscence. *Otol Neurotol* 2006;27:969–80.
- Zhou G, Gopen Q, Poe DS. Clinical and diagnostic characterization of canal dehiscence syndrome: a great otologic mimicker. *Otol Neurotol* 2007;28:920–6.
- Banerjee A, Whyte A, Atlas MD. Superior canal dehiscence: review of a new condition. *Clin Otolaryngol* 2005;30:9–15.
- Belden CJ, Weg N, Minor LB, Zinreich SJ. CT evaluation of bone dehiscence of the superior semicircular canal as a cause of sound- and/or pressure-induced vertigo. *Radiology* 2003;226:337–43.
- Curtin HD. Superior semicircular canal dehiscence syndrome and multi-detector row CT. *Radiology* 2003;226:312–4.
- Minor LB, Cremer PD, Carey JP, Della Santina CC, Streubel SO, Weg N. Symptoms and signs in superior canal dehiscence syndrome. *Ann N Y Acad Sci* 2001;942:259–73.
- Yuen HW, Eikelboom RH, Atlas MD. Auditory manifestations of superior semicircular canal dehiscence. *Otol Neurotol* 2009;30:280–5.
- Chien W, Ravicz ME, Rosowski JJ, et al. Measurements of human middle- and inner-ear mechanics with dehiscence of the superior semicircular canal. *Otol Neurotol* 2007;28:250–7.
- Songer JE, Rosowski JJ. The effect of superior canal dehiscence on cochlear potential in response to air-conducted stimuli in chinchilla. *Hear Res* 2005;210:53–62.
- Merchant SN, Rosowski JJ. Conductive hearing loss caused by third window lesions of the inner ear. *Otol Neurotol* 2008;29:282–9.
- Songer JE, Rosowski JJ. A mechano-acoustic model of the effect of superior canal dehiscence on hearing in chinchilla. *J Acoust Soc Am* 2007;122:943–51.
- Mikulec AA, Poe DS, McKenna MJ. Operative management of superior semicircular canal dehiscence. *Laryngoscope* 2005;115:501–7.
- Crane BT, Minor LB, Carey JP. Superior canal dehiscence plugging reduces dizziness handicap. *Laryngoscope* 2008;118:1809–13.
- Cloutier JF, Belair M, Saliba I. Superior semicircular canal dehiscence: positive predictive value of high-resolution CT scanning. *Eur Arch Otorhinolaryngol* 2008;265:1455–60.