

Neonatal Priapism Associated With Spontaneous Bilateral Pyocavernositis

Rajeev Sood,¹*MS, MCh*, Surender Nath Wadhwa,²*MS, MCh*, Vikas Jain,¹*MS*

Abstract

Introduction: Neonatal priapism is known to be associated with a wide range of aetiologies, but an association with spontaneous purulent cavernositis has not been reported in the paediatric literature. We report the first of such case. **Clinical Picture:** A 24-day-old neonate was brought with the history of persistent erection of penis since day 4 of life and swollen penis of 4 days' duration, which revealed frank pus on cavernosal aspiration bilaterally. **Treatment:** The child was treated with closed aspiration drainage; cross-irrigation with antibiotic solution under systemic antibiotic cover helped in achieving complete detumescence. **Outcome:** On follow-up, child demonstrated normal full bladder tumescence and colour doppler revealed bilateral normal corporo-cavernosal appearance and blood flow, indicating good functional and anatomical recovery. **Conclusion:** This case report describes the presentation, successful management and excellent functional and anatomical outcome, on follow-up, of this rare association of neonatal priapism with spontaneous bilateral pyocavernositis. An attempt has been made to describe the underlying pathophysiology.

Ann Acad Med Singapore 2006;35:425-7

Key words: Corporeal abscess, Erectile dysfunction, Persistent penile erection of newborn

Introduction

Priapism is a pathological state of prolonged, generally painful erection, unassociated with sexual desire and not ending in ejaculation. Rare before the 1980s, this entity became more frequent after the introduction of vasoactive drugs for intracavernosal injections. Idiopathic priapism accounts for one-third of these cases but in paediatric age it is an exceptional disease, with a paucity of reports in neonates.^{1,2} The incidence of primary infection of corpora cavernosa also increased after the introduction of intracavernosal injections, shunts and prostheses. However, spontaneous infection and abscesses of corpora cavernosa are still rarer and have not been reported in a neonate before. We report a case of neonatal priapism associated with spontaneous bilateral pyocavernositis, the first case in the world literature.

Case Report

A 24-day-old neonate was brought to the Emergency Urological Services in August 2004 with a history of erect penis and misdirected urinary stream for 20 days and swollen penis for 4 days. The infant had also been having

mild fever over the last 4 days. His feeding, general activities and sleep were normal. This child was a full-term lower segment caesarean section delivery with prior induction with oxytocin. Birth weight was 3500 g and APGAR score was 9/10. There was no neonatal jaundice. He was born out of a non-consanguineous marriage; his mother had had regular antenatal check-ups and absolutely no antenatal complications. His elder sister had been born with cleft lip and palate 15 years earlier. The mother had taken phenytoin for grand-mal epilepsy for 12 years and had been off drugs for the last 6 years.

Examination revealed a regular pulse rate of 120/min and an abdominothoracic respiration rate of 28/min. His scalp, chest, abdomen and nervous system were unremarkable on examination. Local inspection disclosed 5 x 2 cm, erect, warm, erythematous penis with a hump at the base (Fig. 1). Gonads were normally descended. There was no evidence of any vascular malformation.

Urine was normal on routine and microscopic examination and culture was sterile. Blood profile revealed Hb 13 g/dL, total counts 15,800/mm³, with 79% polymorphs, 18% lymphocytes and 3% eosinophils. Peripheral blood smear

¹ Division of Urology, Department of Surgery
Dr Ram Manohar Lohia Hospital, New Delhi, India

² Department of Urology

Sir Ganga Ram Hospital, New Delhi, India

Address for Reprints: Dr Vikas Jain, Magan Kunj BE/2 (West), Shalimar Bagh, New Delhi-110088, India.

Email: dr_vikasin@yahoo.co.in

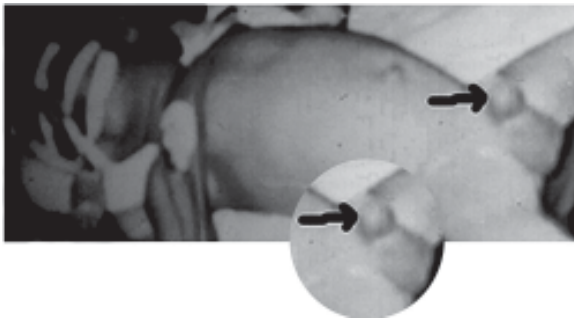


Fig.1. Local examination under anaesthesia disclosed erect penis with a hump at the base (arrow).

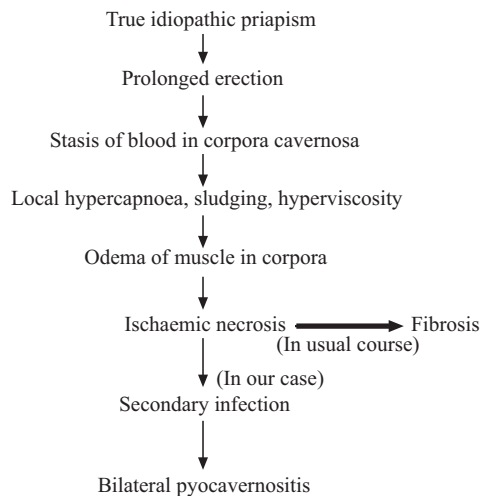


Fig. 3. Possible pathophysiology in the present case.

was normal. Coagulation studies, including prothrombin time, partial thromboplastin time, thrombin time and platelet counts, were normal. There was nothing to suggest sickle cell disease.

In view of the presentation, a preoperative diagnosis of idiopathic neonatal priapism was contemplated and the patient was proposed and prepared for Winter’s glandulo-cavernosum shunt procedure. To our surprise, aspiration under general anaesthesia revealed frank pus, hence aspiration was continued from both corpora cavernosa by introducing two 22G venflon cannulae and cross-irrigation with antibiotic (gentamycin saline) solution continued until detumescence was achieved. Per-urethral 6F feeding tube was indwelled for 24 hours and gentle compression bandage was applied.

Mild fever (37.5°C to 38°C) persisted for 3 days. The penis remained supple but distorted due to oedema for 1 week and assumed near-normal shape thereafter. Pus cultured for aerobes, anaerobes, fungi and acid-fast bacilli grew only *Klebsiella* moderately sensitive to cefotaxime and netilmycin and highly sensitive to quinolones. Blood

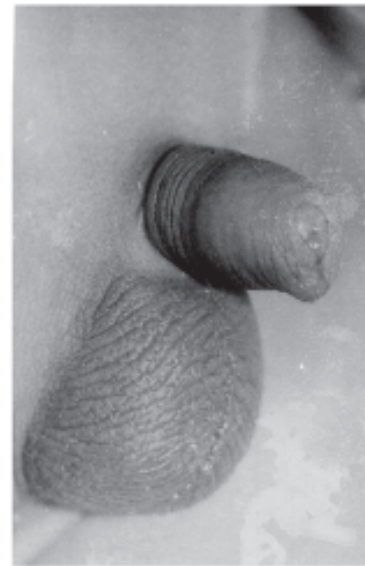

Fig. 2. Full bladder photograph, on follow-up, showed normal shape of penis and normal tumescence.

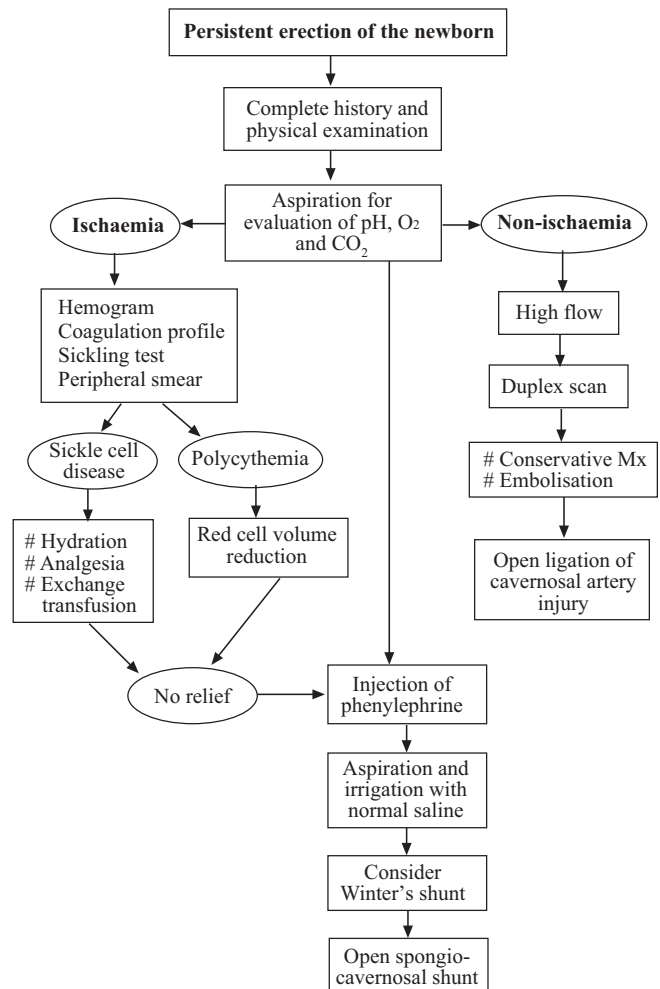


Fig. 4. Management algorithm for persistent penile erection of the newborn.

culture and postoperative urine culture remained sterile.

At 9 months' follow-up, the penis had assumed absolutely normal shape and with full bladder, having normal tumescence (Fig. 2). The colour Doppler revealed normal cavernosal appearance and normal cavernosal arteries bilaterally, with blood flow of 18 to 20 mL/s.⁵ No vasoactive drug was used to conduct further studies, considering the age of the patient. Thus, the child achieved successful functional and anatomical recovery and there is no indication that the patient has a risk for later impotence.

Discussion

Priapism was rare before the 1980s, until the advent of intracavernosal injections for erectile dysfunction. In a review of 170 scientific reports comprising 1400 cases of priapism from the world literature, which included 230 complete single case reports, only 9 of 230 were below 10 years of age.³ There were 38 different aetiological factors and still one-third of patients labelled idiopathic. Primary priapism (idiopathic) is more common in adults while secondary priapism (cause known) is more common in children. In the neonatal age group, full bladder or an irritative focus in the urethra can be the cause of false priapism and true idiopathic priapism is extremely rare. In the literature, the first case of true idiopathic priapism was reported in 1914, followed by 2 more such reports in a 3-day-old and a 4-day-old neonate.¹ In these cases, priapism recovered spontaneously, while waiting for surgery, after long hours of erection, without subsequent loss of function. Hence, these authors recommended that in idiopathic neonatal priapism, one must not rush for surgery while most others declared priapism as an emergency and demanded an immediate specific therapy.⁴ Pohl and colleagues³ in their studies advocated that a delay of 5 days in surgical intervention may be acceptable while trying conservative methods with no effect on end results in the three-phase concept of management. In our case, the remarkable recovery of erectile function observed in spite of pyocavernositis endorses the recovery potential of corporal tissues in neonates. Unlike adults, cavernosal smooth muscle cells are not activated in neonates under hypoxic low-flow environment to get converted into more resistant fibroblast-like cells, which are capable of collagen and elastic fibre synthesis, thereby causing postpriapic erectile tissue fibrosis and later impotence.⁵

The corpora cavernosa rarely serve as the primary site of infection. A number of cases of corporal infection, however, have been described in adults in association with local precipitating factors, such as gonorrhoea,⁶ trauma,⁷ priapism,⁸ foreign body,⁹ intracavernosal injection¹⁰ and cavernosonography.¹¹ Spontaneous corporal infection,

however, are exceptional. There are only 3 case reports of corporal purulent infections (but without priapism) in adults, comprising 1 of tubercular cold abscess¹² and 2 other of spontaneous bacterial abscesses.^{13,14} Pyocavernositis with priapism in a diabetic following intracavernosal injection has also been reported.¹⁵ Neonatal pyocavernositis in isolation or with priapism has not been reported in the world literature. We hypothesise the following sequence of events in the present case (Fig. 3).

Conclusion

The first case report of neonatal priapism with bilateral pyocavernositis is presented. Possible pathophysiology is postulated. The delay in the definitive surgical intervention and bilateral purulent cavernositis has not affected the long-term outcome in the form of good functional and anatomical recovery. This exemplifies the great recovery potential of corporal tissues in the neonate. We also propose the management algorithm for this rare entity (Fig. 4).

REFERENCES

1. Walker JR, Casale AJ. Prolonged penile erection in the newborn. *Urology* 1997;50:796-9.
2. Devoldere G, Ricard J, Canarelli JP. Case report of priapism in a 4 year old child (French). *Prog Urol* 1991;1:1039-41.
3. Pohl J, Pott B, Kleinhans G. Priapism: a three-phase concept of management according to aetiology and prognosis. *Br J Urol* 1986;58:113-8.
4. Reif R, Vyborny K. Priapism: a urological emergency. *Acta Univ Palacki Olomuc Fac Med* 1993;135:59-63.
5. Spycher MA, Hauri D. The ultrastructure of the erectile tissue in priapism. *J Urol* 1986;135:142-7.
6. Rosen T. Unusual presentations of Gonorrhoea. *J Am Acad Dermatol* 1982;6:369-72.
7. Neidrach WL, Lerner RM, Linke CA. Penile abscess involving the corpus cavernosum: a case report. *J Urol* 1989;141:374-5.
8. Schwarzer JU, Hofmann R. Purulent corporal cavernositis secondary to papaverine-induced priapism. *J Urol* 1991;146:845.
9. Peppas DS, Moul JW, McLeod DG. *Candida albicans* corporal abscess following penile prosthesis placement. *J Urol* 1988;140:1541-2.
10. Orvis BR, Lue TF. New therapy for impotence. *Urol Clin N Am* 1987;14:569-81.
11. Velcek D, Evans JA. Cavernosography. *Radiology* 1982;144:781-5.
12. Yachia D, Friedman M, Auslaender L. Tuberculous cold abscess of the corpus cavernosum: a case report. *J Urol* 1990;144:351-2.
13. Sater AA, Vandendris M. Abscess of corpus cavernosum. *J Urol* 1989;141:949.
14. Pearle MS, Wendel EF. Necrotizing cavernositis secondary to periodontal abscess. *J Urol* 1993;149:1137-8.
15. Parfitt VJ, Wong R, Dobbie A, Hartog M, Gingell JC. Staphylococcal septicaemia complicating intracavernosal autoinjection therapy for impotence in a man with diabetes. *Diabet Med* 1992;9:947-9.