

## Facial Palsy from Temporal Bone Lesions

EH Chan,<sup>1</sup>MBBS, HM Tan,<sup>2</sup>MBBS, FRCR, TY Tan,<sup>1</sup>FAMS, MBBS, FRCR

### Abstract

**Introduction:** Facial nerve palsy results in the loss of facial expression and is most commonly caused by a benign self-limiting inflammatory condition, known as Bell's palsy. However, there are other conditions which may result in injury of the seventh cranial nerve and the radiologist should be familiar with their imaging appearances. **Materials and Methods:** The relevant anatomy of the facial nerve and pathology which may affect the intratemporal portion of the nerve is described. The role of imaging and choice of imaging modality is also reviewed. **Results:** High-resolution computer tomography (HRCT) images of the temporal bone and magnetic resonance (MR) images of the facial nerve from 11 patients who presented with facial nerve palsy were used to illustrate how intratemporal facial nerve injury of other aetiologies can mimic Bell's palsy. The typical imaging appearance of Bell's palsy was also presented. **Conclusions:** Most patients with suspected Bell's palsy do not require radiologic imaging. However, when symptoms progress, persist or when there is multiple cranial nerve involvement, recurrent symptoms or subacute onset of facial nerve palsy, causes other than Bell's palsy should be considered.

Ann Acad Med Singapore 2005;34:322-9

**Key words:** Facial nerve, Haemangioma, Palsy, Schwannoma, Temporal bone

### Introduction

#### Clinical Relevance of the Facial Nerve Anatomy

The facial nerve is traditionally divided into the following parts for discussion: supranuclear, nucleus and tracts, cisternal segment, intratemporal segment and the peripheral segment. For the purposes of this paper, only the cisternal and intratemporal segments are considered.

The facial nerve root exit zone is at the lower border of the pons at the recess between the olive and superior cerebellar peduncle. From this point the cisternal segment of the facial nerve courses through the cerebellopontine angle cistern over a short length of 20 mm to 25 mm, before entering the porus acusticus of the internal auditory canal (IAC). Due to the proximity of the vestibulocochlear nerve, lesions affecting the cisternal segment of the facial nerve are often associated with eighth nerve symptomatology. Similarly, within the IAC, the seventh roots are slightly anterior to and superior to the vestibulocochlear nerve. The

sensory root tends to be more susceptible than the motor root to injury, disease, or compromise in the cisternal segment.<sup>1</sup> This fact can be clinically useful to localise the segment of the nerve affected, and help direct the most appropriate imaging methods to this anatomical region of interest.

Within the IAC (Figs. 1a and 1b), the facial nerve is separated from the cochlear nerve inferiorly by a stubby transverse bony ridge known as the crista falciformis. A ventral ridge referred to as Bill's bar, together with the intermediate nerve, separates the facial nerve from the superior vestibular nerve posteriorly. Thus, the facial nerve is located in the anterior superior quadrant of the IAC.

The course of the facial nerve through the temporal bone is familiar to most neuroradiologists because it has been extensively studied via computed tomography (CT). The intratemporal segment of nerve VII is further subdivided into 3 segments: labyrinthine, tympanic, and mastoid.

<sup>1</sup> Department of Radiology  
Changi General Hospital, Singapore

<sup>2</sup> Department of Radiology  
Singapore General Hospital, Singapore

Address for Reprints: Dr Elizabeth Chan, Department of Radiology, Changi General Hospital, 2 Simei Street 3, Singapore 529889.

The labyrinthine segment (Fig. 1) is the shortest of the intratemporal segments, usually 3 mm to 5 mm in length. However, the facial nerve is particularly vulnerable in this location and is subject to compromise or complete transection by temporal bone fractures, particularly transverse fractures.<sup>1,2</sup> The labyrinthine segment courses anterolaterally from the fundus of the IAC to terminate at the geniculate ganglion. Due to the presence of the vertical bony crest, the aperture leading to the labyrinthine segment is particularly narrow. The greater superficial petrosal nerve (GSPN), containing preganglionic parasympathetic fibres to the lacrimal gland, is the first major branch of the facial nerve. It arises from the geniculate ganglion and exits the petrous temporal bone via the greater petrosal foramen to enter the middle cranial fossa. Therefore, interruption of the facial nerve prior to the exit of this nerve results in deficiencies of lacrimation.

The facial canal forms an inverted “V” near the top of the cochlea, known as the anterior genu (Fig. 2). This is the location of the geniculate ganglion, where there is a crossroad of 4 nerve canals: the labyrinthine segment of the facial nerve canal, the tympanic segment of the facial nerve canal, the accessory facial hiatus (containing the lesser petrosal nerve) and the facial hiatus (containing the GSPN). The latter 2 canals may be imaged on routine CT or magnetic resonance imaging (MRI) but are better appreciated when enlarged or prominently enhanced in pathologic states, such as antegrade or retrograde tumour spread.<sup>1</sup>

The proximal tympanic segment (Fig. 3) lies along the medial wall of the anterior epitympanic recess, which is separated from the anterior portion of the epitympanum by a vertically oriented, often ossified bony septum referred to as the cog. Epitympanic cholesteatomas eroding the cog and extending into the anterior epitympanic recess are therefore in direct apposition to the proximal tympanic segment of the facial nerve.<sup>3</sup> The mid-tympanic segment of the facial nerve lies immediately underneath the lateral semicircular canal (Fig. 4), and as such is immediately superior to the oval window. Dehiscences are especially common in this location, rendering the facial nerve vulnerable to injury during middle ear surgical procedures. Occasionally, the nerve may actually protrude through the dehiscence and lie within the oval window niche, causing conductive hearing deficit. These are also of interest to the otologic surgeon because their presence complicates prosthetic stapedectomy.<sup>4</sup> The distal tympanic segment is found within the pyramidal eminence beneath the short process of the incus.

The second (posterior) genu of the facial nerve connects the tympanic and mastoid segment of the facial nerve. From here, the mastoid segment (Fig. 5) courses inferiorly, lateral to the jugular fossa. When the jugular fossa is large,

the facial nerve is in very close apposition and the facial canal possibly even dehiscence. Lesions originating within the jugular foramen, such as glomus jugulare tumours (paraganglioma), commonly involve the facial nerve at this point. The other relationship of clinical importance is the extreme proximity of the mastoid segment of the facial nerve to the posterior tympanic annulus (site of attachment of the tympanic membrane).

Two major intratympanic branches of the facial nerve arise from the mastoid segment; proximally, the stapedius nerve and more distally, the chorda tympani. The nerve may move slightly laterally as it approaches the stylomastoid foramen, whereupon it exits from the temporal bone and continues its peripheral course.

### Clinical Findings and Implication for Imaging

The presence of relevant clinical deficits can greatly assist in narrowing the search for pathology and tailoring the imaging protocol. Knowledge of origins of the branches of the facial nerve which are responsible for 3 special functions can often localise the site of facial nerve injury. As mentioned above, the first main branch of the facial nerve is the GSPN, which arises from the geniculate ganglion and supplies the lacrimal glands. The next branch of the facial nerve originates from the mastoid segment, and is the stapedius nerve which controls the stapedius reflex. The third special sensation is that of taste in the anterior two-thirds of the tongue. This is supplied by the lingual nerve, via the chorda tympani nerve, also a branch of the mastoid segment of the facial nerve. Finally, the muscles controlling facial expression are innervated by the extracranial motor component of the facial nerve, damage to which would result in facial nerve palsy.

A lower pontine lesion is suspected if all 3 special functions are absent and there is associated abducens nerve (VI) palsy as the facial nerve fibres circle the abducens nucleus on their way out of the brainstem. Absence of all 3 special functions with vestibulocochlear neuropathy points to a cerebellopontine angle or intracanalicular pathology. Temporal bone pathology gives rise to variable involvement of the 3 special functions with peripheral facial nerve palsy. If, however, lacrimation, stapedius reflexes and taste sensation are all preserved in the presence of facial asymmetry, an extracranial facial nerve injury is likely.

The value of topographic localisation lies in tailoring management and the selection of the most appropriate imaging modality.

### Imaging Methods of the Facial Nerve

The choice of imaging modality depends on 2 main factors: the portion of the facial nerve being studied, and the clinical indication for imaging. As discussed above,

topographical localisation would help determine which segment of the facial nerve has been injured. If the pathology is localised to the brainstem nuclei, the cisternal segment or the intracanalicular portion of the nerve, MRI is superior to high resolution computed tomography (HRCT). The tympanic portion of the facial nerve is best imaged with HRCT. Although the mastoid portion may be imaged with either modality, MRI is favoured as lack of mastoid pneumatisation may limit the use of HRCT.<sup>3</sup>

The clinical indication also affects the choice of imaging modality. HRCT is preferred in the setting of trauma, with complementary MRI if indicated. In the setting of hemifacial spasm, MRI is the modality of choice.

Protocols for MRI of the facial nerve vary from institution to institution. However, most would include the following sequences: pre-gadolinium axial and coronal T1W images (3 mm with a 10% interslice gap, and a small field of view), post-gadolinium fat-suppressed axial and coronal T1W images with similar parameters, and a 3-dimensional constructive interference in the steady state (CISS) sequence, acquired as axial 0.7-mm sections that may be reformatted in multiple planes. For HRCT images, 0.8-mm thick slices are acquired in the axial plane with coronal image reconstruction with current multi-detector scanners, multi-planar reformatting being especially useful.

On MRI, the normal facial nerve shows slightly low or intermediate intensity on T1W. The presence of a circumneural venous plexus surrounding the intratemporal facial nerve results in normal enhancement of at least 1 segment in 76% to 98% of the population.<sup>5,6</sup> This is particularly noticeable in the region of the geniculate ganglion.<sup>5</sup> The enhancement may be intense and is often asymmetric, with no correlation between degree of enhancement and symptomatology.<sup>7</sup> Given this degree of variation in normal enhancement pattern, MRI diagnosis of facial nerve pathology is not possible based on enhancement, unless there is concurrent nodularity or obvious expansion of the nerve. The only segments in which enhancement may indicate pathology, is in the distal intracanalicular segment, where physiological enhancement is almost never seen, and the labyrinthine portion, where normal enhancement is rarely seen (Figs. 6a and 6b). This is attributed to the absence of the perineural arteriovenous plexus in these portions.<sup>8</sup> Thus, the criteria for defining pathological enhancement of the facial nerve have not been fully determined.<sup>8</sup>

## Aetiology of Facial Nerve Injury

### *Inflammatory Conditions of the Facial Nerve*

Inflammatory disease is by far the more common cause of facial paralysis. The classic inflammatory neuropathy of the facial nerve, known as Bell's palsy, is responsible for

approximately half of all facial palsies seen in the clinical setting. The diagnosis of Bell's palsy is a clinical one, with a subacute to acute onset of facial nerve weakness, progressing to paralysis in several days. The disease is usually unilateral, with associated loss of taste, hyperacusis, and ipsilateral loss of lacrimation. The facial paralysis is often preceded by a viral prodrome and complete resolution of symptoms within 1 month is typical.

There are numerous misconceptions regarding the ability of MRI to diagnose Bell's palsy. Early reports indicated that pathologic enhancement of a normal or mildly enlarged facial nerve was diagnostic. However, as previously indicated, diagnosis of Bell's palsy on the basis of enhancement is probably not possible,<sup>5</sup> unless there is enhancement of the intracanalicular or cisternal segments (Fig. 7). Despite this, the classical description on MRI of Bell's palsy is uniform enhancement of the intratemporal facial nerve, with little or no enlargement and no focal nodularity.<sup>9</sup> In any case, most patients with suspected Bell's palsy do not require radiologic evaluation. MRI is only indicated in atypical Bell's palsy: when there are features of progressive or prolonged palsy persisting for more than 4 months, multiple cranial nerve involvement, recurrent symptomatology or subacute onset.<sup>10</sup>

There has been recent evidence of a strong association between the herpes simplex virus and Bell's palsy, implicating viral reactivation as the pathogenesis.<sup>11</sup> Neural entrapment due to interstitial oedema and swelling is the presumed aetiology of the facial nerve dysfunction. Interruption of vascular supply also plays a role in the pathophysiology.

Herpes zoster oticus (or Ramsay Hunt syndrome) is often indistinguishable from Bell's palsy, unless there are concomitant findings. Clinically, in addition to facial nerve palsy, there are painful vesicles within the external auditory canal and eighth cranial nerve involvement (vertigo, hearing loss) is common. This is seen on MRI as simultaneous enhancement of the acoustic nerve and membranous labyrinth, thus allowing precise diagnosis.

Basal meningitides, such as tuberculosis or sarcoidosis, may on occasion involve the facial nerve, mainly the cisternal and intracanalicular segments. This is reflected in enhancement of the nerve itself, or of the adjacent dura and subarachnoid space. Similarly, inflammatory or infectious disease of the middle ear, petrous apex, or of the skull base may also result in secondary involvement of the facial nerve.

### *Neoplastic Conditions of the Facial Nerve*

Neoplasm is a relatively uncommon cause of peripheral facial palsy.<sup>12</sup> As with all neoplastic conditions, possibilities include primary tumours or metastatic disease. The 2 well-known, albeit uncommon, primary neoplasms of the facial nerve are schwannoma and haemangioma.

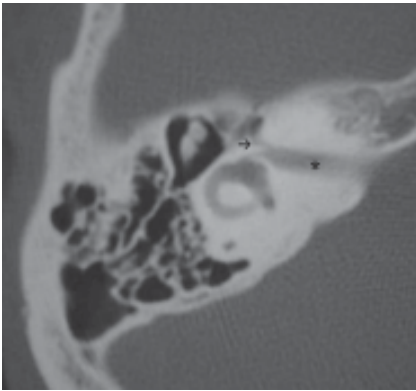


Fig. 1a

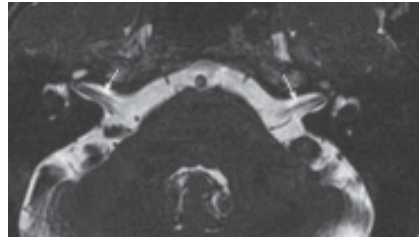


Fig. 1b

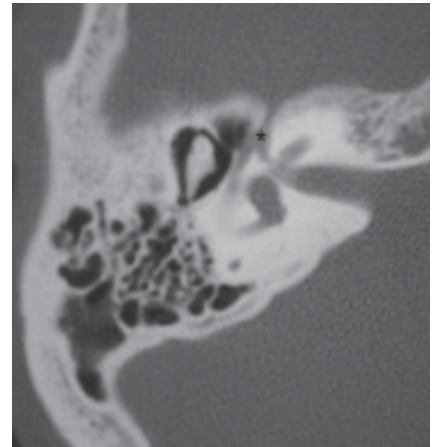


Fig. 2

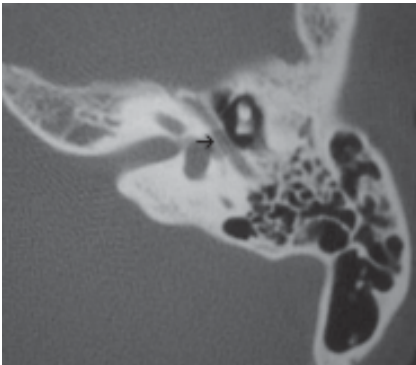


Fig. 3

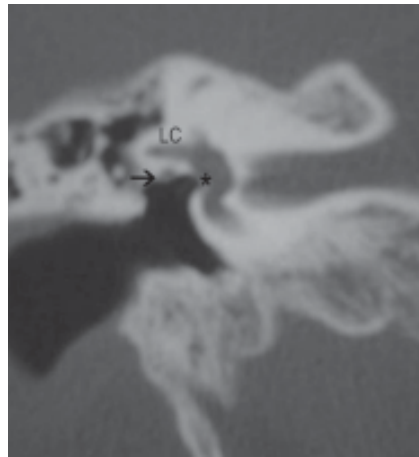


Fig. 4

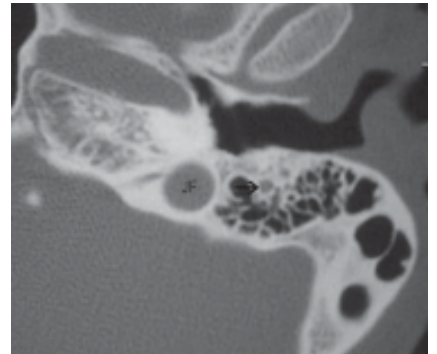


Fig. 5

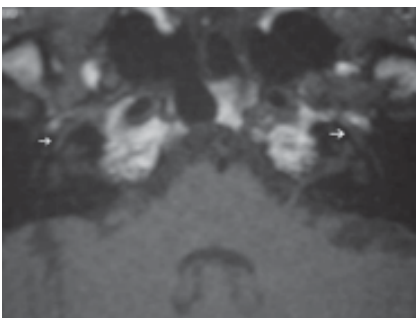


Fig. 6a

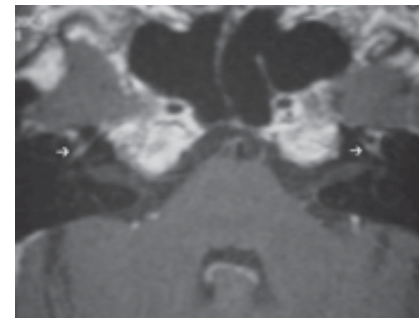


Fig. 6b

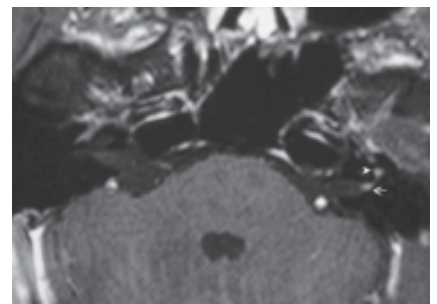


Fig. 7

Fig. 1a. Axial CT image of the right temporal bone demonstrating the normal anatomy of the internal auditory canal (\*) and the labyrinthine portion of the facial canal (arrow).

Fig. 1b. Axial MR CISS image of the internal auditory canals demonstrating the normal course of the intracanalicular portion of the facial nerve (arrows).

Fig. 2. Axial CT image of the right temporal bone demonstrating the normal anatomy of the anterior genu of the facial canal (\*), where the geniculate ganglion is situated.

Fig. 3. Axial CT image of the left temporal bone demonstrating the normal anatomy of the tympanic portion of the facial canal (arrow).

Fig. 4. Coronal CT image of the right temporal bone demonstrating the normal anatomical relationship of the tympanic portion of the facial

canal (arrow) and the lateral semicircular canal (LC) and the oval window (\*).

Fig. 5. Axial CT image of the right temporal bone illustrating the normal anatomical mastoid segment (arrow) of the facial canal lateral to the jugular foramen (JF).

Figs. 6a and 6b. Pre- and post-gadolinium MR images of the same patient demonstrating symmetrical physiological enhancement (arrows) of the tympanic portion of the facial nerves.

Fig. 7. Pathological enhancement is seen in the distal intra-canalicular segment (arrow) of the left facial nerve in a patient presenting with Bell's palsy. Note also the enhancement of the labyrinthine portion, which is almost always pathological. Enhancement of the geniculate ganglion (arrowhead) may be a normal finding.

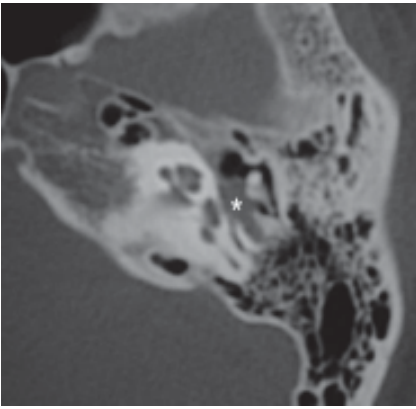


Fig. 8a

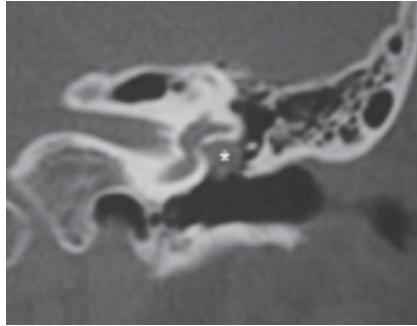


Fig. 8b




Fig. 9

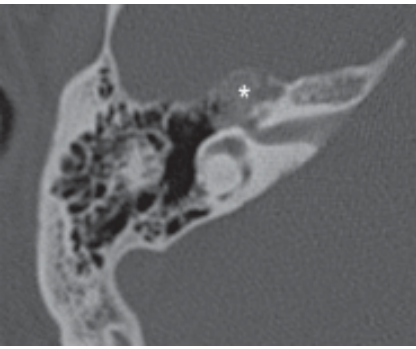


Fig. 10a

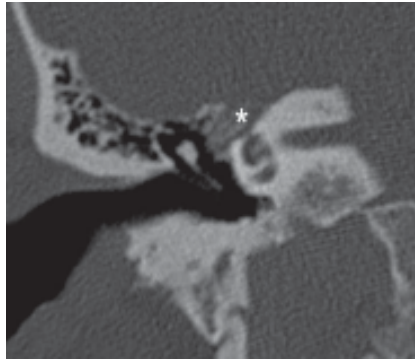


Fig. 10b

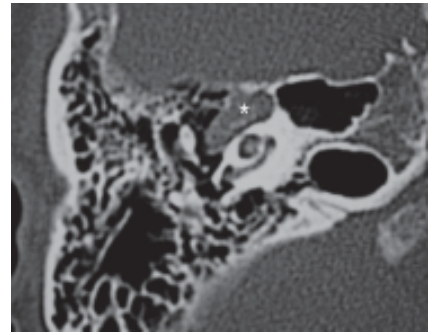


Fig. 11a

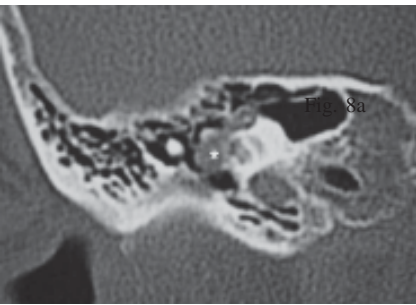


Fig. 11b

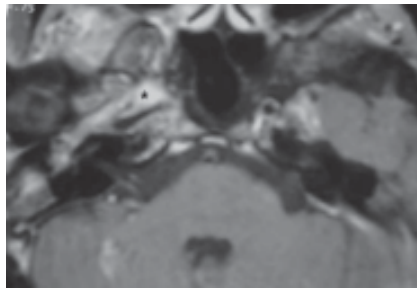


Fig. 12

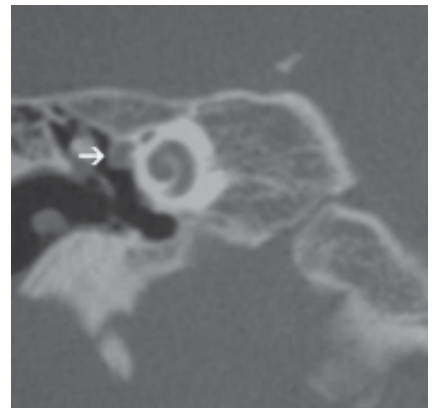


Fig. 13

Figs 8a (axial) and 8b (coronal). Lobulated mass involving the tympanic portion of the facial nerve in a patient with facial nerve palsy. Histologically proven schwannoma.

Fig. 9. T1-weighted axial MR image of the same patient as Figures 8a and 8b, demonstrating an enhancing lobulated mass (\*) involving the tympanic portion of the facial nerve.

Figs 10a (axial) and 10b (coronal). Geniculate ganglion mass (\*) with internal bony spicules characteristic of an ossifying haemangioma.

Figs 11a (axial) and 11b (coronal). Mass (\*) enlarging the geniculate ganglion and tympanic portion of the facial canal. Note the irregular bony margin which distinguishes non-ossifying haemangioma from schwannoma of the facial nerve.

Fig. 12. Nasopharyngeal carcinoma (\*) extending into the middle ear cavity, involving the geniculate ganglion and tympanic portion of the right facial nerve, resulting in facial nerve palsy.

Fig. 13. Perineural haematoma (arrow) compressing the tympanic portion of the right facial nerve.

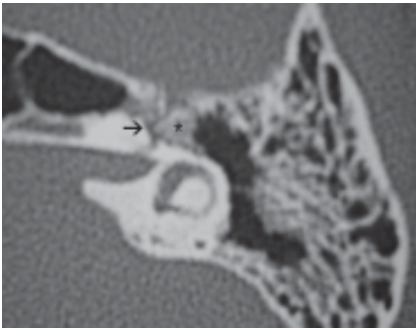


Fig. 14

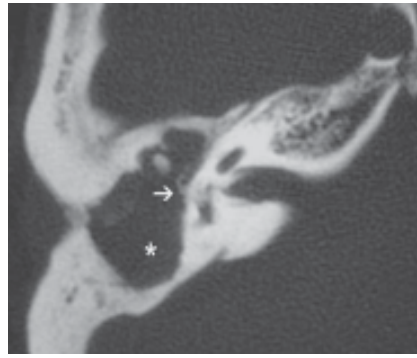


Fig. 15

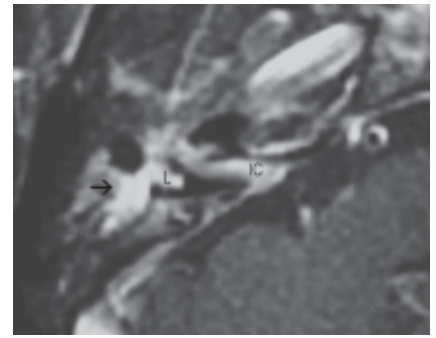


Fig. 16

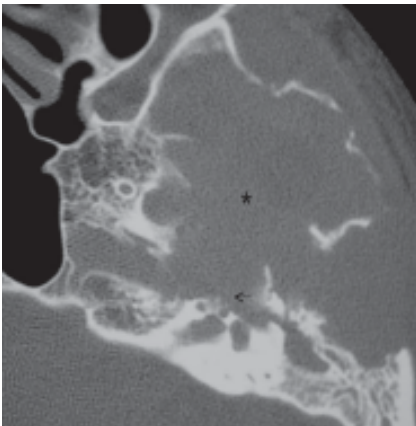


Fig. 17

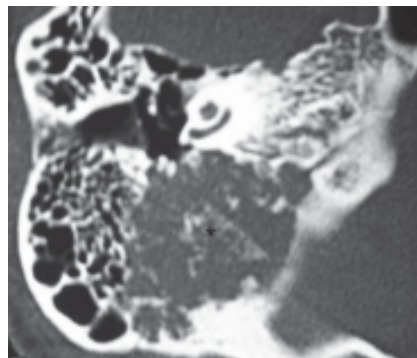


Fig. 18

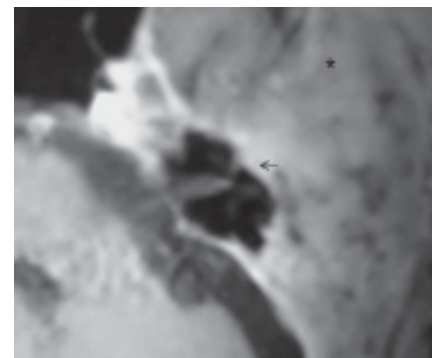


Fig. 19

Fig. 14. Patient with temporal bone trauma showing a triangular bony fragment (\*) impinging on the geniculate ganglion (arrow) of the left facial nerve.

Fig. 15. Cholesteatoma expanding the mastoid antrum and middle ear cavity (\*). Arrow indicates the region where the cholesteatoma erodes into the tympanic portion of the right facial nerve causing facial nerve paralysis.

Fig. 16. Otitis media (arrow) by *Enterobacter species*, spreading along the course of the right facial nerve into the intracanalicular segment (IC). Note also pathological enhancement of the labyrinth (L) indicating inner ear inflammation.

Fig. 17. Giant cell tumour of the temporal bone (\*), with its typical soap bubble appearance, compressing the geniculate ganglion (arrow) of the left facial nerve.

Fig. 18. Chondrosarcoma of the right temporal bone (\*) compressing the mastoid portion of the facial nerve.

Fig. 19. Breast carcinoma with metastasis to temporal bone (\*). Note involvement of the tympanic portion (arrow) of the left facial nerve with pathological enhancement of the labyrinthine portion and the distal intra-canalicular segments.

Facial nerve schwannoma is the most common neoplasm to cause facial nerve palsy<sup>3</sup> but is responsible for less than 5% of all facial nerve palsies.<sup>13</sup> Schwannomas may involve the facial nerve at any location from its brainstem origin to the parotid gland, with geniculate ganglion (first genu) involvement being the most common.<sup>14</sup> As with eighth nerve schwannomas, they arise from the outer layer (nerve sheath) and expand eccentrically. Importantly, fewer than half of these lesions present with facial paralysis. Hearing loss is commonly associated with facial nerve schwannomas. This can be sensorineural, from compression of the adjacent vestibulocochlear nerve, if the cisternal and/or intracanalicular segments are involved; or conductive, as with involvement of the intratympanic segment of the facial nerve. Intratympanic masses may

also erode or mechanically impede ossicular movement, producing conductive hearing deficit.

Facial nerve schwannomas are homogeneous lesions of intermediate T1W signal intensity that enhance intensely with gadolinium. As such, intracanalicular and cisternal facial nerve schwannomas appear identical to those originating from the eighth nerve. On the basis of imaging, a superior and anterior location within the cistern and internal auditory canal may be of value in distinguishing between facial and vestibular schwannomas. However, this can only be done with certainty if extension along the intratemporal course of the facial nerve is demonstrated.<sup>2</sup> Enhancement may become more heterogeneous with increasing size, along with a tendency to develop rounded areas of cystic change.<sup>1</sup> On CT, the lesion is seen as a

lobulated mass along the course of the facial nerve associated with expansion of the facial canal and sharply defined bony margins (Figs. 8a, 8b and 9).

Facial nerve haemangiomas, which are benign vascular tumours, were previously considered rare, but recently have been recognised as frequently as facial nerve schwannomas.<sup>15</sup> Clinically, haemangiomas present with facial palsy and hemifacial spasm at an earlier stage than schwannoma, because they invade the nerve rather than simply compress it.<sup>9</sup> Thus, a small haemangioma will cause severe symptoms, whilst a schwannoma may be of considerable size with minimum symptomatology.

Haemangiomas occur predominantly at the geniculate ganglion and the pyramidal (distal) turn of the facial nerve.<sup>15,16</sup> They vary in size but most are approximately 1 cm in diameter at presentation. These lesions expand the affected portion of the facial canal and are associated with indistinct margins, which differentiates them from the usual sharply marginated appearance of schwannomas.<sup>15</sup> Ossifying haemangiomas typically have a distinctive spoke-wheel pattern secondary to the presence of internal bony spicules (Figs. 10a and 10b). On MRI, these lesions are somewhat heterogeneous in signal intensity on T1W and T2W images but appearances are otherwise non-specific.<sup>17</sup> There is also a subtype of haemangiomas not associated with intratumoural bone known as non-ossifying haemangiomas (Figs. 11a and 11b). These are often indistinguishable from schwannomas.<sup>17</sup>

Malignant involvement of the intratemporal portion of the facial nerve canal from head and neck malignancies may occur. A common primary site is the parotid gland. Hence, parotid gland imaging is essential as perineural spread to the mastoid segment of the facial nerve via the stylomastoid foramen may be demonstrated (Fig. 12). Long segments of the nerve can be involved and extension of the tumour from this foramen to the level of the IAC has been reported. Skip lesions are also possible. Approximately 50% of these cases are due to adenoid cystic carcinoma of the parotid gland<sup>2</sup> and approximately 50% of adenoid cystic carcinoma show perineural tumour involvement.<sup>18</sup> The tumour is noted on histopathologic sections to travel in the perineurium of the facial nerve, and can move in an antegrade or retrograde fashion. Careful review of the parotid gland is important in all patients with facial palsy of unknown origin, particularly when diffuse expansion of the intratemporal facial nerve canal is diagnosed. Rarely, involvement of the facial nerve is spread via the GSPN from lesions that have extended to the pterygopalatine fossa.<sup>19</sup> Numerous primary sites of origin need to be considered in this circumstance.

Other neoplasms to consider include paraganglioma, lymphoma, and endolymphatic sac tumours. Glomus formations may occur along the course of the facial nerve,

especially in the region of the first genu. Paragangliomas arising from these specific glomus formations are referred to as glomus faciale, and are extraordinarily rare lesions.<sup>3</sup>

#### *Traumatic Conditions of the Facial Nerve*

Fractures of the temporal bone are a well-known cause of facial nerve palsy and are often categorised according to their relation to the long axis of the petrous segment: transverse (10% to 20%), longitudinal (80% to 90%), or a mixed pattern. Facial nerve paralysis is associated with 25% to 70% of temporal bone fractures,<sup>20</sup> and is more commonly associated with transverse fractures than with longitudinal fractures (50% versus 15% respectively).<sup>18</sup> The incidence and morbidity is also greater with the transverse variety.<sup>20</sup> This may be related to the different mechanisms of facial nerve injury associated with transverse and longitudinal fractures.

There are several established mechanisms for post-traumatic facial nerve damage. The injury may consist of a true sectioning of the nerve, compression of the nerve trunk by a contiguous haematoma (Fig. 13) and/or by adjacent bony fragments (Fig. 14), or the nerve may be stretched by the separation of 2 fracture fragments with the formation of intraneural haematoma or oedema.<sup>18</sup> The last situation leads to the compression of the facial nerve at the meatal foramen (entrance of the distal intracanalicular segment into the labyrinthine segment), where the nerve is relatively immobile, leading to secondary ischaemia and nerve degeneration. Occasionally, nerve regeneration via a pathogenic mechanism similar to that of inflammatory palsy has been described. With a longitudinal fracture, the most common lesion is that of an intraneural haematoma at the level of the geniculate ganglion. However, transverse fractures are associated with more proximal nerve lesions, predominantly affecting the labyrinthine segment, from compression of the facial nerve at the meatal foramen.<sup>21</sup>

HRCT scans can show the exact course of the fracture line in relation to the bony facial nerve canal as well as associated injuries (i.e., disruption of the ossicular chain, haematotympanum, the site of leakage of cerebrospinal fluid in patients with otorhino-liquorrhea, and injury of the temporomandibular joint).<sup>18</sup> However, the facial nerve itself is not visible on HRCT.

The advantage of MRI is visualisation of the nerve itself, allowing assessment of its size and enhancement pattern. Given the pathogenesis of post-traumatic facial nerve palsy, identical enhancement patterns of the different facial nerve segments can be assumed in patients with inflammatory and post-traumatic facial nerve palsy. Identical enhancement pattern is observed independent of the exact site of facial nerve lesion.<sup>11</sup> Abnormal nerve enhancement is always or nearly always observed in the distal intrameatal segment and is commonly seen in the labyrinthine segment,

the proximal tympanic segment and the geniculate ganglion.

As is the case of inflammatory facial nerve palsy,<sup>7</sup> there is no correlation between nerve enhancement and the degree of nerve fibre degeneration at electroneurography.<sup>18</sup> There is also no correlation between severity or duration of clinical symptoms and imaging characteristics. Prolonged, abnormal enhancement of the facial nerve, especially the distal intrameatal segment, may persist for up to 2 years after trauma.<sup>18</sup>

Even when a fracture cannot be identified radiologically on HRCT, a fracture of the temporal bone must be assumed in patients with post-traumatic facial nerve palsy. On MRI, dural enhancement along the rostral border of the temporal bone is commonly observed in patients with post-traumatic palsy, even in patients without temporal bone fractures. These findings may be due to radiologically invisible microfractures of the temporal bone, associated with microtears of the adjacent dura;<sup>18</sup> hence, CT and MRI are highly complementary in the investigation of post-traumatic facial palsy.

#### *Temporal Bone Lesions Involving the Facial Nerve*

Finally, any lesion of the temporal bone adjacent to the facial canal may erode the bone and damage the facial nerve, causing palsy. These include inflammatory conditions such as mastoiditis, acquired and congenital cholesteatomas (Fig. 15) and bacterial otitis media (Fig. 16). Primary pathology of the bone affecting the temporal bone may also damage the facial nerve. These include sclerosing conditions such as Paget's disease and primary tumours such as giant cell tumour (Fig. 17) or chondrosarcoma (Fig. 18). As mentioned above, metastatic disease to the temporal bone may also injure the facial nerve (Fig. 19).

#### **Conclusion**

Approximately half of facial nerve palsies are due to typical Bell's palsy, and the patients do not require radiologic imaging. However, when the facial palsy is progressive, or prolonged, persists for more than 4 months, is associated with multiple cranial nerve involvement, has recurrent symptomatology or subacute onset, imaging is indicated. The choice of imaging modality, either HRCT or MRI, should be guided by topographical localisation of the facial nerve segment that is involved, and the clinical presentation, e.g., trauma. The spectrum of diseases affecting the facial nerve is extensive. More common lesions include inflammatory conditions such as herpes zoster oticus, primary neoplasms of the facial nerve (namely schwannoma and haemangioma), secondary tumours of the facial nerve (predominantly perineural spread from adenoid cystic carcinoma of the parotid gland) and temporal bone fractures. Furthermore, any temporal bone lesion in close proximity to the facial nerve may damage the nerve, and common

diseases such as cholesteatomas also cause facial nerve palsy.

#### REFERENCES

1. Phillips CD, Bubash LA. The facial nerve: anatomy and common pathology. *Semin Ultrasound CT MR* 2002;23:202-17.
2. Swartz JD, Harnsberger HR, editors. *Imaging of the Temporal Bone*, 3rd edition. New York; Thieme Medical Publishers, 1998:192.
3. Swartz JD, Harnsberger HR, Mukherji SK. The temporal bone. Contemporary diagnostic dilemmas. *Radiol Clin North Am* 1998;36:819-53.
4. Swartz JD. The facial nerve canal: CT analysis of the protruding tympanic segment. *Radiology* 1984;153:443-7.
5. Gebarski SS, Telian SA, Niparko JK. Enhancement along the normal facial nerve and facial canal: MR imaging and anatomic correlation. *Radiology* 1992;183:391-384.
6. Martin-Duverneuil N, Sola-Martinez MT, Miaux Y, Cognard C, Weil A, Mompoin D, et al. Contrast enhancement of the facial nerve on MRI: normal or pathological? *Neuroradiology* 1997;39:207-12.
7. Sartoretti-Schefer S, Brandt P, Wichmann W, Valavanis A. Intensity of MR contrast enhancement does not correspond to clinical and electroneurographic findings in acute inflammatory facial nerve palsy. *AJNR Am J Neuroradiol* 1996;17:1229-36.
8. Kinoshita T, Ishii K, Okitsu T, Oudera T, Ogawa T. Facial nerve palsy: evaluation by contrast-enhanced MR imaging. *Clin Radiol* 2001;56:926-32.
9. Davidson HC. Imaging of the temporal bone. *Magn Reson Imaging Clin N Am* 2002;10:573-613.
10. Smouha EE, Coyle K, Shkri S. Facial nerve palsy in Lyme disease: evaluation of clinical diagnostic criteria. *Am J Otol* 1997;18:257-61.
11. Sartoretti-Schefer S, Wichmann W, Valavanis A. Idiopathic, herpetic, and HIV-associated facial nerve palsies: abnormal MR enhancement patterns. *AJNR Am J Neuroradiol* 1994;15:479-85.
12. Fagan PA, Misra SN, Doust B. Facial neuroma of the cerebellopontine angle and the internal auditory canal. *Laryngoscope* 1993;103:442-6.
13. Latack JT, Gabrielson TO, Knake JE, Kemink JL, Graham MD, Gebarski SS, et al. Facial nerve neuromas: radiologic evaluation. *Radiology* 1983;149:731-9.
14. McMenomey SO, Glasscock ME 3rd, Minor LB, Jackson CG, Strasnick B. Facial nerve neuromas presenting as acoustic tumors. *Am J Otol* 1994;15:307-12.
15. Curtin HD, Jensen JE, Barnes L Jr, May M. "Ossifying" hemangiomas of the temporal bone: evaluation with CT. *Radiology* 1987;164:831-5.
16. Lo WW, Shelton C, Waluch V, Solti-Bohman LG, Carberry JN, Brackmann DE, et al. Intratemporal vascular tumors: detection with CT and MR imaging. *Radiology* 1989;171:443-8.
17. Salib RJ, Tziambazis E, McDermott AL, Chavda SV, Irving RM. The crucial role of imaging in detection of facial nerve haemangiomas. *J Laryngol Otol* 2001;115:510-13.
18. Sartoretti-Schefer S, Scherler M, Wichmann W, Valavanis A. Contrast-enhancement MR of the facial nerve in patients with posttraumatic peripheral facial nerve palsy. *AJNR Am J Neuroradiol* 1997;18:1115-25.
19. Ginsberg LE, De Monte F, Gillenwater AM. Greater superficial petrosal nerve: anatomy and MR findings in perineural tumor spread. *AJNR Am J Neuroradiol* 1996;17:389-93.
20. Brodie HA, Thompson TC. Management of complications from 820 temporal bone fractures. *Am J Otol* 1997;18:188-97.
21. Fisch U. Management of intratemporal facial nerve injuries. *J Laryngol Otol* 1980;94:129-34.