

Craniofacial Anomalies: Clinical and Molecular Perspectives

M Michael Cohen Jr,**DMD, PhD, FCCMG*

Abstract

The first three disorders discussed are abnormalities of bone: too little bone in cleidocranial dysplasia caused by mutations in RUNX2; too much bone in fibrodysplasia ossificans progressiva with overexpression of BMP4; and abnormal bone in McCune-Albright syndrome and fibrous dysplasia caused by mutations in GNAS1. Disorders of the sonic hedgehog signaling network are discussed next, including holoprosencephaly and the nevoid basal cell carcinoma syndrome, the former being caused by sonic hedgehog (SHH) mutations and the latter being caused by patched mutations (PTCH).

Ann Acad Med Singapore 2003; 32:244-51

Key words: Osteogenesis, Osteosarcoma, Pituitary adenoma, Dispatched, Tumor suppressor gene

Cleidocranial Dysplasia and RUNX2 Mutations

Cleidocranial dysplasia is an autosomal dominant skeletal disorder characterized by short stature, brachycephaly, delayed closure of the fontanelles and sutures, Wormian bones, midface hypoplasia, unerupted teeth, supernumerary permanent teeth, aplasia or hypoplasia of the clavicles, and other skeletal anomalies, such as hypoplastic iliac wings and brachydactyly.^{1,2}

Cleidocranial dysplasia is caused by mutations in *RUNX2*. These mutations result in haploinsufficiency and may be of the deletion, insertion, missense, or nonsense types.³ A clustering of missense mutations involving Arg225 indicates that this amino acid residue is critical for *RUNX2* function.²

RUNX2 plays a fundamental role in osteogenesis and also regulates many osteoblast genes, such as osteocalcin, osteopontin, bone sialoprotein, collagenase-3, and osteoprotegerin. *RUNX2* also regulates chondrocyte differentiation, as well as differentiation of precursor cells of the clavicular anlage (Fig. 1). *Runx2*^{-/-} null mutant mice show complete lack of endochondral and membranous ossification. Heterozygous mice (*Runx2*^{+/-}) have cleidocranial dysplasia.^{2,4}

Fibrodysplasia Ossificans Progressiva and BMP4

Fibrodysplasia ossificans progressiva (FOP) is characterized by progressive ectopic ossification, abnormal halluces, various other bone defects, and, in some cases

hearing deficit and diffuse thinning of the hair. Inheritance is autosomal dominant with most cases occurring sporadically.⁵

Progressive heterotopic ossification begins during the first decade of life and appears in predictable temporal and spatial patterns, heralded by large painful fibroproliferative nodules in tendons, ligaments, and skeletal muscles. The early lesions are indistinguishable from juvenile fibromatosis. The nodules mature to form lamellar bone that bridges and immobilizes the joints of the axial and appendicular skeleton. Bone formation occurs spontaneously, but can also be triggered by trauma. Thus, surgical excision of bone is futile because trauma inevitably stimulates bone formation at the surgical site.^{1,5-9}

Bone morphogenetic protein 4 (BMP4), which maps to 14q22-q23, is overexpressed in fibrodysplasia ossificans progressiva, although no mutations have been identified.^{10,11} Thus, BMP4 overexpression may be a secondary response to some other basic defect.

Feldman et al¹² studied four affected families and established linkage to 4q27-q31. They suggested that SMAD1, a BMP pathway specific gene, and possibly several other candidate genes in the linkage region warrant further investigation.

Lucotte et al¹³ and Sémonin et al¹⁴ reported *NOGGIN* (*NOG*) mutations for FOP. However, these are probably PCR errors, as noted by Xu et al.¹⁵ The FOP patient with the

* Professor Emeritus

Departments of Oral & Maxillofacial Sciences, Pediatrics, Community Health & Epidemiology, Health Services Administration, and Sociology & Social Anthropology, Dalhousie University, Halifax, Nova Scotia, Canada

Address of Correspondence: Dr M Michael Cohen Jr, Dalhousie University, Halifax, Nova Scotia, Canada B3H 3J5.

E-mail: r.macleam@dal.ca

$\Delta 42G260-C301$ mutation reported by Lucotte et al¹⁵ was examined independently by the International FOP Research Consortium who failed to detect the presence of the reported 42-bp deletion.¹⁵ *NOG* is an unusual gene. It has a single exon with no introns. Its coding region is extremely GC-rich (67%), suggesting that the gene may be highly methylated and/or susceptible to secondary structure formation that could interfere with PCR amplification fidelity. The amplification error rate in *NOGGIN* product subclones is high in both FOP patients and controls.¹⁵

McCune-Albright Syndrome, Fibrous Dysplasia, and *GNAS1* Mutations

McCune-Albright syndrome (MAS), polyostotic fibrous dysplasia (PFD), monostotic fibrous dysplasia (MFD), and pituitary adenoma (PA) have the same etiology – a ligand-independent, activating *GNAS1* mutation in the α subunit of stimulatory G protein ($G_s\alpha$). Mutations are located near the site which interacts with the γ -phosphate of GTP, thus interfering with hydrolysis of GTP to GDP. Because $G_s\alpha$ cannot dissociate from adenylyl cyclase and bind to $G_{\beta\gamma}$, adenylyl cyclase remains active, producing increased cAMP activity which results in the pathology of MAS, PFD, MFD and PA^{16,17} (Fig. 2).

McCune-Albright syndrome (MAS) is characterized by polyostotic fibrous dysplasia, café-au-lait spots, and multiple endocrinopathies, including sexual precocity, pituitary adenoma, and hyperthyroidism. All cases occur sporadically, and the disorder is caused by somatic mosaicism, lethal in the non-mosaic state.^{16,17}

With somatic mosaicism, a mutation occurs post-zygotically in a somatic cell rather than in a germ cell. All cells descended from the mutated cell can manifest MAS features. Cells descended from non-mutated cells develop into normal tissues. Thus, the clinical pattern is mosaic in distribution and variable in appearance. Severe versus mild manifestations and more generalized versus more localized expression depend on (a) how small or how large the cell mass is during embryogenesis when the mutation occurs and (b) where in the cell mass the mutation occurs.¹⁶⁻¹⁸

The same two *GNAS1* mutations found in MAS also occur in polyostotic fibrous dysplasia (PFD), monostotic fibrous dysplasia (MFD), and isolated pituitary adenoma (PA) of the growth hormone secreting type, less commonly of the ACTH secreting type. How the mutations cause these disorders separately depends on when during embryonic development or during postnatal life the mutation occurs (Fig. 3). A somatic mutation in a small cell mass is

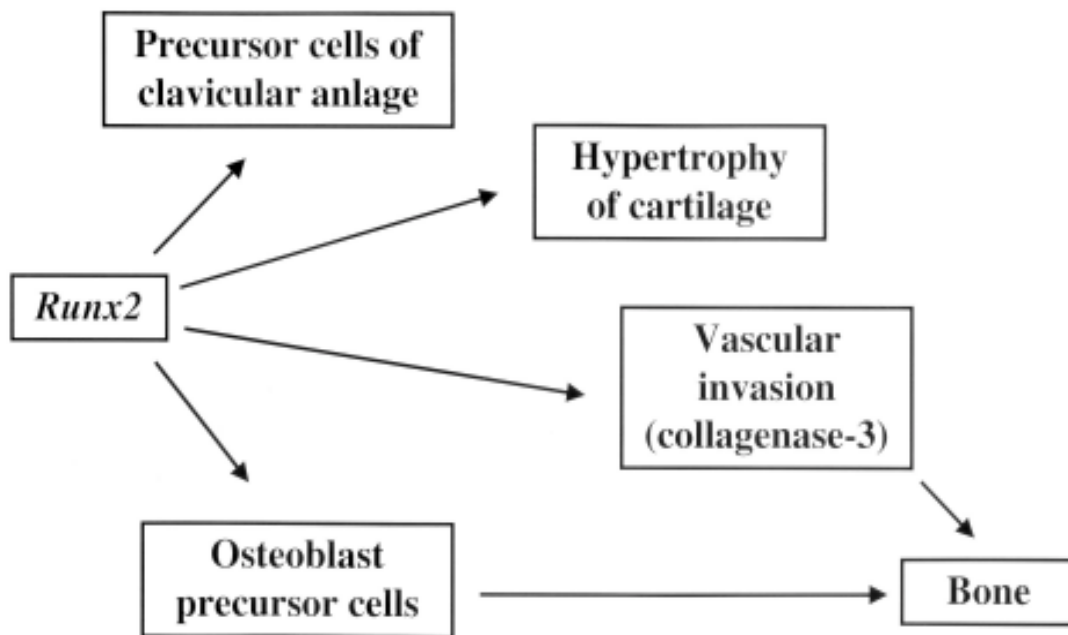


Fig. 1. *Runx2* controls differentiation of precursor cells into osteoblasts, regulates chondrocyte differentiation towards hypertrophy, may cause vascular invasion of cartilage by regulating collagenase-3, and controls differentiation of precursor cells of clavicular anlage. Modified from Mundlos.³

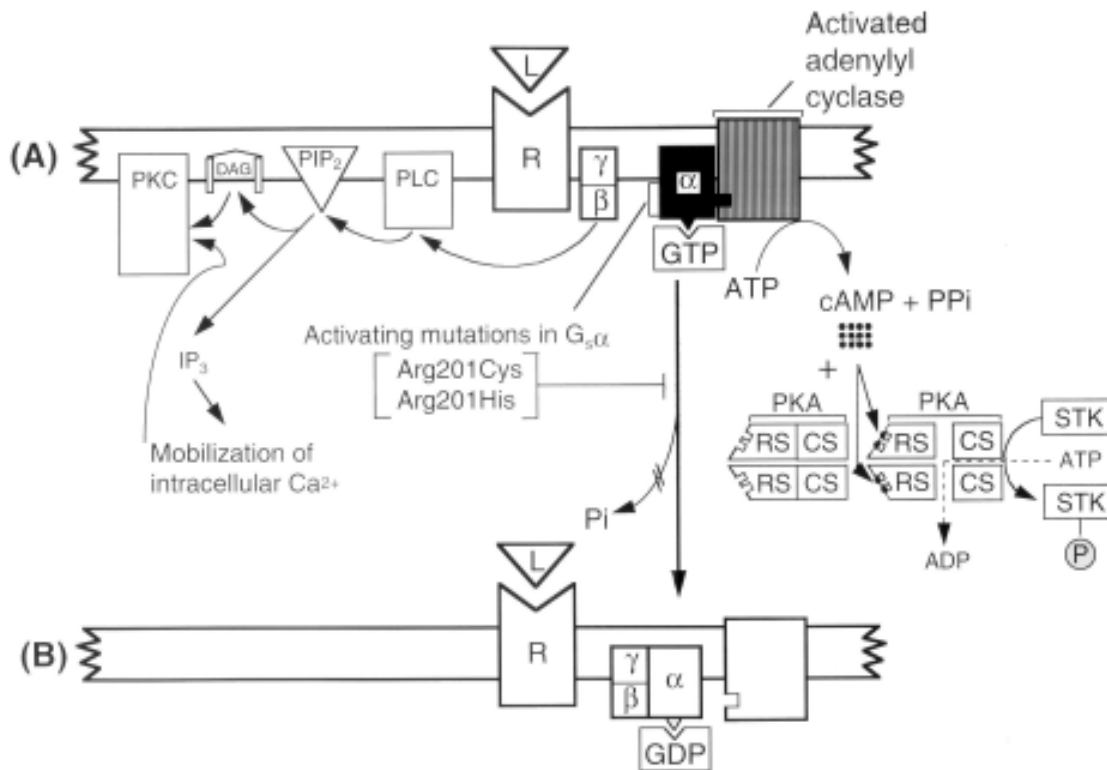


Fig. 2. Activating mutations (Arg201Cys or Arg201His) in the gene encoding the α subunit of stimulatory G protein ($G_s\alpha$). **A:** Ligand-independent persistent activation of $G_s\alpha$. There is inappropriate stimulation of adenylyl cyclase. The mutations are located adjacent to the γ -phosphate of GTP, thus interfering with hydrolysis of GTP by GTPase to GDP. **B:** Therefore, the subunit ($G_s\alpha$) cannot dissociate from adenylyl cyclase and bind to the $\beta\gamma$ subunit ($G_{\beta\gamma}$). Two downstream pathways are shown in A. The PKA pathway (protein kinase A or cAMP-dependent protein kinase pathway) is shown on the right. The PKC pathway (protein kinase C pathway) is shown on the left. Both pathways are present with normal functioning as well as with mutations. Because the subunit ($G_s\alpha$) cannot dissociate from adenylyl cyclase, cAMP is overproduced which, in turn, overactivates the PKA pathway. PKA is composed of two regulatory subunits (RS) that have binding sites for cAMP, and two catalytic subunits (CS) that, when dissociated, phosphorylate serine/threonine kinases (STK). The dissociated $\beta\gamma$ subunit overactivates the PKC pathway. PLC (phospholipase C) cleaves PIP_2 (phosphatidylinositol bisphosphate) into two intracellular messengers: DAG (diacylglycerol) and IP_3 (inositol trisphosphate). The latter triggers the release of sequestered calcium ions (Ca^{2+}) which together with DAG activate PKC.¹⁷

likely to result in MAS. A mutation in a larger cell mass may result in PFD. A mutation in postnatal life, during infancy, childhood, or adult life may result in MFD (Fig. 3) or in PA, depending on the anatomic location of the mutation. All of these disorders are components of MAS.¹⁶⁻¹⁸

Cohen and Howell¹⁶ suggested that fibrous dysplasia is a neoplasm. Traditionally, fibrous dysplasia has been considered to be a bone disorder. However, it is well known that, in a few instances, lesions in fibrous dysplasia behave more aggressively than in most cases. The same activating mutation that causes fibrous dysplasia also causes pituitary adenoma, which is a neoplasm. The mutation may be found in an isolated pituitary adenoma and in McCune-Albright syndrome which is often associated with pituitary adenoma.

Candeliere et al¹⁹ found high levels of c-fos proto-oncogene expression in cells populating the bone marrow spaces in eight patients with fibrous dysplasia. In contrast,

very low levels of c-fos expression were detected in other bone disorders such as vitamin D-resistant rickets and osteogenesis imperfecta, suggesting that increased expression of c-fos may be specific for fibrous dysplasia. If so, activating mutations in *GNAS1*, which cause fibrous dysplasia, may increase c-fos expression by increased adenylyl cyclase activity.¹⁶

In studies of transgenic mice, overexpression of c-fos results in bone lesions that closely resemble fibrous dysplasia²⁰ and osteosarcomas develop in some cases.²¹ In studies of human osteosarcomas, c-fos expression is increased. Osteosarcomas are known to develop in about 4% of patients with McCune-Albright syndrome and in about 0.5% of patients with fibrous dysplasia.²²

In addition to the links of activating *GNAS1* mutations with c-fos, MAS, PFD, MFD, PA, and osteosarcoma, several other neoplasms with the same mutations have occurred sporadically or in association with MAS. For

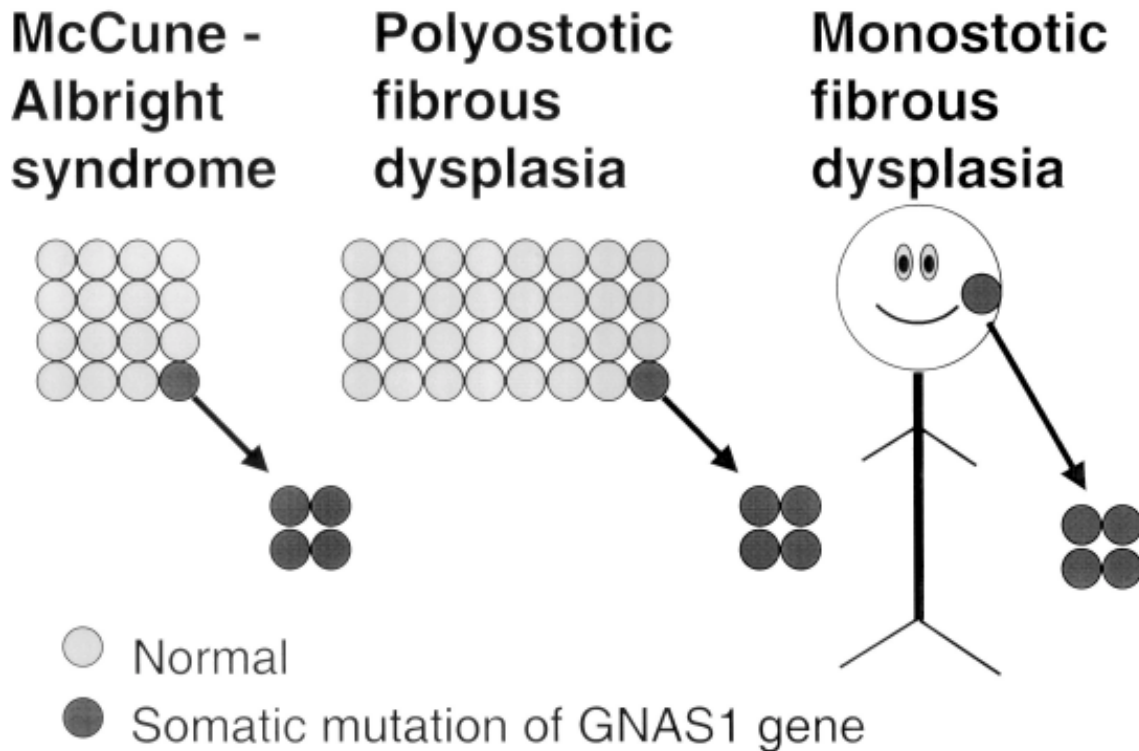


Fig. 3. How mutations cause McCune-Albright syndrome, polyostotic fibrous dysplasia, and monostotic fibrous dysplasia depend on when during embryonic development or during postnatal life the mutation occurs. A somatic mutation in a small cell mass is likely to result in McCune-Albright syndrome. A mutation in a larger cell mass may result in polyostotic fibrous dysplasia. A mutation in postnatal life, during infancy, childhood, or adult life may result in monostotic fibrous dysplasia.¹⁸

example, *GNAS1* mutations have been reported in isolated thyroid tumors, ovarian cysts, and Leydig cell tumors. MAS can be associated with ovarian cysts and with low frequency neoplasms such as thyroid tumors, parathyroid adenomas, intramuscular myxomas, and carcinomas of the breast.²³

Holoprosencephaly, Nevroid Basal Cell Carcinoma Syndrome, and the Sonic Hedgehog Signaling Network

The sonic hedgehog signaling network (Fig. 4) has mutations in specific genes that can cause holoprosencephaly and the nevoid basal cell carcinoma syndrome. Mutations in sonic hedgehog (*SHH*) cause holoprosencephaly and mutations in *Patched* (*PTCH*) cause the nevoid basal cell carcinoma syndrome.

Holoprosencephaly is a developmental field defect of impaired midline cleavage of the embryonic forebrain. In alobar holoprosencephaly, the prosencephalon fails to cleave sagittally into cerebral hemispheres, transversely into telencephalon and diencephalon, and horizontally into olfactory tracts and bulbs. Although the classic definition is unambiguous, problems are encountered at the less severe end of the phenotypic spectrum. The classic anatomic definition of holoprosencephaly and the variable definitions

used in genetics are both valid and depend on the context in which they are used.²⁴

In a classic article, DeMyer et al²⁵ discussed a graded series of facial anomalies that occur with holoprosencephaly (Table I). The face predicts the brain approximately 80% of the time; the other 20% of the time, the facial features are nondiagnostic.^{26,27} Barr and Cohen²⁸ reported essentially normal faces in some autosomal recessive cases of holoprosencephaly.

Identifiable genetic causes account for about 15-20% of all cases of holoprosencephaly. Monogenic inheritance has been reported, including autosomal dominant transmission with wide expressivity and incomplete penetrance,^{29,30} autosomal recessive transmission,^{31,32} and X-linked transmission.^{33,34} Molecularly defined holoprosencephaly only accounts for a very small percentage of all cases of holoprosencephaly: *SHH*,³⁵⁻³⁷ *TGIF*,³⁸ *ZIC2*,^{39,40} *SIX3*,⁴¹ *PTCH*,⁴² *GLI2*,⁴³ *TDGF1*,⁴⁴ *FAST1*,⁴⁵ and *DHCR7*.⁴⁶

SHH mutations account for about 17% of familial cases and about 3.7% of sporadic cases.⁴⁷ *SHH* has an N-terminal signaling domain (*SHH-N*) and a C-terminal catalytic domain (*SHH-C*) that causes autocleavage of the protein, resulting in an ester-linked cholesterol moiety at the carboxy-

TABLE I: HOLOPROSENCEPHALIC FACES^a

Facial type ^b	Main facial features	Brain
Cyclopia	Median monophthalmia, synophthalmia, or anophthalmia. Proboscis may be single or absent. Hypognathism in some cases.	Alobar holoprosencephaly
Ethmocephaly	Ocular hypotelorism with proboscis.	Alobar holoprosencephaly
Cebocephaly	Ocular hypotelorism and blind-ended, single-nostril nose.	Usually alobar holoprosencephaly
Median cleft lip	Ocular hypotelorism, flat nose, and median cleft lip.	Usually alobar holoprosencephaly
Less severe facial dysmorphism	Variable features including ocular hypotelorism or hypertelorism, flat nose, unilateral or bilateral cleft lip, iris coloboma, or other anomalies. Minimal facial dysmorphism in some cases. ^c	Semilobar or lobar holoprosencephaly

a. Modified after DeMyer et al.²⁵

b. Transitional facial forms are known to occur.

c. Autosomal recessive alobar holoprosencephaly with an essentially normal face has been reported.²⁸

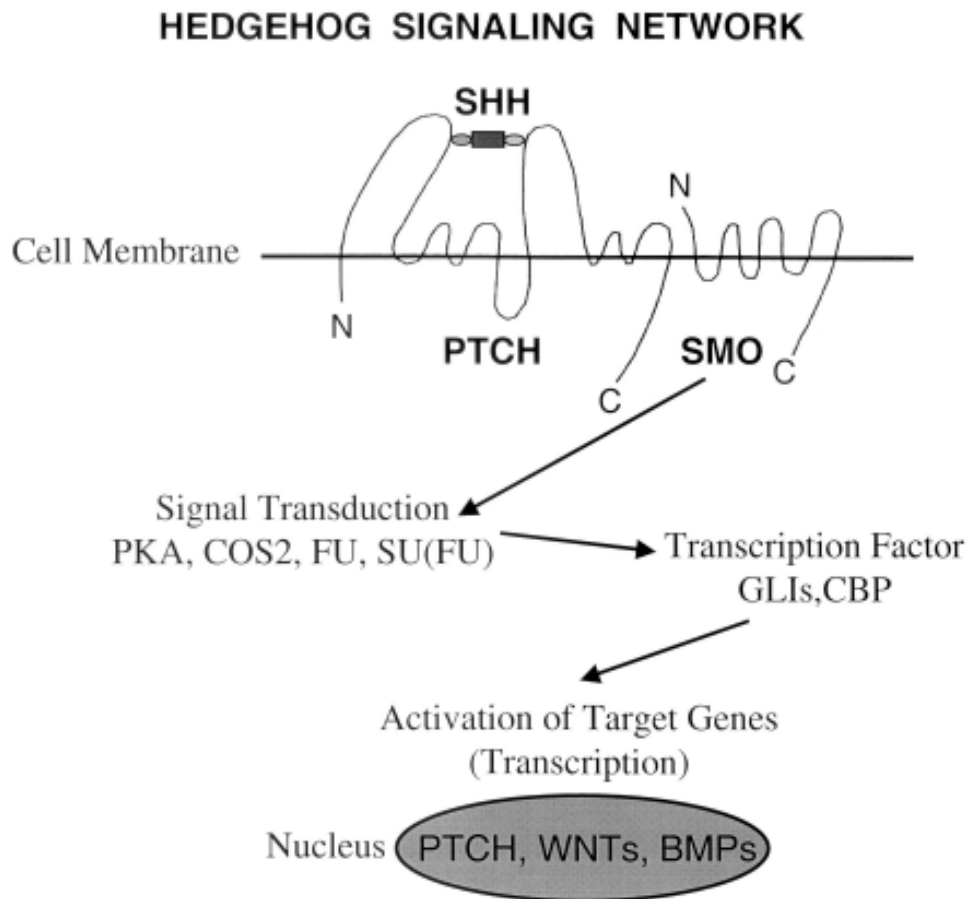


Fig. 4. Hedgehog signaling network, SHH = Sonic Hedgehog N-terminal signaling domain with an amide-linked amino-terminal palmitate and an ester-linked cholesterol moiety, a ligand for Patched (PTCH). PTCH = transmembrane protein with 12 hydrophobic membrane-spanning domains, intracellular amino- and carboxy terminal regions, and two large extracellular loops where sonic hedgehog ligand binding occurs. SMO = Smoothened, a transmembrane protein with seven hydrophobic membrane-spanning domains, an extracellular amino-terminal region, and an intracellular carboxy-terminal region. PKA = Protein kinase A. COS2 = Kinesin-related protein. FU = Fused, a serine/threonine kinase. SU(FU) = Suppressor of fused. GLIs = GLI1, GLI2, and GLI3, transcription activators and repressors. CBP = transcription coactivator. WNTs = WNT genes. BMPs = bone morphogenetic proteins.⁴⁷

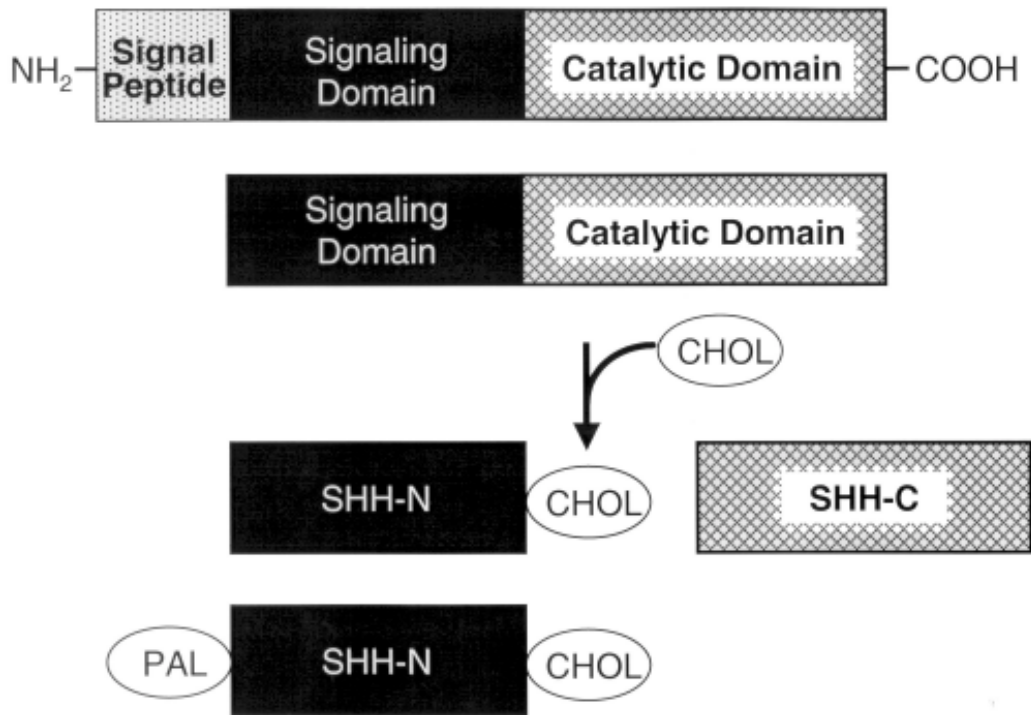


Fig. 5. Sonic Hedgehog (SHH) has an N-terminal signaling domain (SHH-N), and a C-terminal catalytic domain (SHH-C) that causes autocleavage of the protein, resulting in an ester-linked cholesterol moiety (CHOL) at the carboxy-terminal end of the signaling portion; the catalytic portion diffuses away. An amide-linked amino-terminal palmitate (PAL) is critical for signaling activity. Following the addition of the carboxy-terminal cholesterol adduct, palmitoylation requires the action of Skinny hedgehog (Ski) acyltransferase.⁴⁷

terminal end of SHH-N. The autocleavage of SHH proceeds via a thioester intermediate that undergoes a nucleophilic attack by cholesterol, resulting in a covalently-linked cholesterol adduct and activation of the SHH-N signaling protein. The SHH-C catalytic portion diffuses away⁴⁸ (Fig. 5).

Following the autoprocessing reaction, palmitoylation of the most amino-terminal cysteine of the SHH-N signaling portion takes place, requiring the action of Skinny hedgehog (Ski) acyltransferase^{49,50} (Fig. 5). The ester-linked cholesterol moiety and the amide-linked palmitate might be expected to anchor the SHH-signaling portion to the membranes of the producing cells. However, signaling extends many cells beyond its source, and long range action of SHH depends on Dispatched (DISP), which releases SHH from the cell membranes.⁵¹⁻⁵³

The clinical findings of the nevoid basal cell carcinoma syndrome are summarized in Table II. Systems affected include the skin, skeletal system, and central nervous system.

The nevoid basal cell carcinoma syndrome is caused by mutations in *Patched* (*PTCH*). *PTCH* is a tumor suppressor gene located at 9q22.3. It functions as a cell cycle regulator,

stopping cell division in the absence of ligand and permitting cell division when ligand binding occurs.⁵⁴

Generally, for a tumor suppressor gene to be activated, two hits are required. The first hit involves a mutation in one allele, which can be dominantly inherited if present in a germ cell, but which is classically considered to have no phenotypic effect. The second hit involves loss of the other allele, known as loss of heterozygosity (LOH). There are three ways in which the second allele can be lost: (a) deletion; (b) mitotic nondisjunction; and (c) mitotic recombination. When both alleles are inactivated, tumor growth occurs. LOH has been demonstrated in basal cell carcinomas, odontogenic keratocysts, and medulloblastoma – three features of the nevoid basal cell carcinoma syndrome.⁵⁴

PTCH is probably not a classic tumor suppressor gene because the first (germ cell) hit alone may account for the malformations and their variability in patients with the nevoid basal cell carcinoma syndrome. Features such as Marfanoid habitus, macrocephaly relative mandibular prognathism, and possibly spina bifida, bifid ribs, postaxial polydactyly, and cleft lip palate (Table II) do not seem to require two hits. The single germ cell hit, resulting in the

TABLE II: SOME FEATURES OF THE NEVOID BASAL CELL CARCINOMA SYNDROME

Skin	
Multiple basal cell carcinomas (~90%)	
Epidermal cysts	
Palmar/plantar pits	
Skeletal/Radiographic	
Bifid ribs	
Spina bifida occulta	
Kyphoscoliosis	
Pectus excavatum	
Short fourth metacarpals	
Postaxial polydactyly (~4%)	
Lymphomesenteric cysts	
CNS	
Medulloblastoma (~3-5%)	
Calcified falx cerebri	
Bridged sella turcica	
Meningioma (~1% or less)	
Craniofacial	
Large head circumference	
Mild hypertelorism	
Well developed supraorbital ridges	
Cleft lip/palate (~5%)	
Oral	
Odontogenic keratocysts of the jaws (~90%)	
Other tumors	
Ovarian fibroma (~15%)	
Cardiac fibroma (~3%)	
Many other features	

malformations of the nevoid basal cell carcinoma syndrome apparently behaves like any other gene producing an autosomal dominant malformation syndrome with variability in expression. For basal cell carcinomas, medulloblastoma, and keratocysts, however, two hits are required.⁵⁴

REFERENCES

- Cohen M M Jr. Merging the old skeletal biology with the new. II. Molecular aspects of bone formation and growth. *J Craniofac Genet Dev Biol* 2000; 20:94-106.
- Cohen M M Jr. Editorial comment: *RUNX* genes, neoplasia, and cleidocranial dysplasia. *Am J Med Genet* 2001; 104:185-8.
- Mundlos S. Cleidocranial dysplasia: clinical and molecular genetics. *J Med Genet* 1999; 36:177-82.
- Mundlos A, Otto F, Mundlos C, Mulliken J B, Aylsworth A S, Albright S, et al. Mutations involving the transcription factor *CBFA1* cause cleidocranial dysplasia. *Cell* 1997; 89:773-9.
- Cole D E C, Cohen M M Jr. Mutations affecting bone-forming cells. In: Hall BK, editor. *Bone: the Osteoblast and Osteocyte*. Caldwell, NJ: Telford Press, 1990;1:431-87.
- Connor J M, Evans D A P. Genetic aspects of fibrodysplasia ossificans progressiva. *J Med Genet* 1982; 19:35-9.
- Cohen R B, Hahn G V, Tabas J A, Peeper J, Levitz C L, Sando A, et al. The natural history of heterotopic ossification in patients who have fibrodysplasia ossificans progressiva: a study of 45 patients. *J Bone Joint Surg* 1993; 75A:215-9.
- Connor J M, Skirton H, Lunt P W. A three-generation family with fibrodysplasia ossificans progressiva. *J Med Genet* 1993; 30:687-9.
- Kaplan F S, Tabas J A, Gannon F H, Finkel G, Hahn G V, Zasloff M. The histopathology of fibrodysplasia ossificans progressiva: an endochondral process. *J Bone Joint Surg* 1993; 75A:220-30.
- Shafritz A B, Shore E M, Gannon F H, Zasloff M A, Taub R, Muenke M, et al. Overexpression of an osteogenic morphogen in fibrodysplasia ossificans progressiva. *N Engl J Med* 1996; 335:555-61.
- Xu M, Shore E M. Mutational screening of the bone morphogenetic protein 4 gene in a family with fibrodysplasia ossificans progressiva. *Clin Orthop* 1998; 34:53-8.
- Feldman G, Li M, Martin S, Urbanek M, Urtizberea J A, Fardeau M, et al. Fibrodysplasia ossificans progressiva, a heritable disorder of severe heterotopic ossification, maps to human chromosome 4q27-31. *Am J Hum Genet* 2000; 66:128-35.
- Lucotte G, Sémonin O, Lut P. Letter to the editor. A de novo heterozygous deletion of 42 base-pairs in the *noggin* gene of a fibrodysplasia ossificans progressiva patient. *Clin Genet* 1999; 56:469-70.
- Sémonin O, Fontaine K, Daviaud C, Ayuso C, Lucotte G. Identification of three novel mutations of the *Noggin* gene in patients with fibrodysplasia ossificans progressiva. *Am J Med Genet* 2001; 102:314-7.
- Xu M Q, Feldman G, Le Merrer M, Shugart Y Y, Glaser D L, Utizberea J A, et al. Linkage exclusion and mutational analysis of the *noggin* gene in patients with fibrodysplasia ossificans progressiva (FOP). *Clin Genet* 2000; 58:291-8.
- Cohen M M Jr, Howell R E. Etiology of fibrous dysplasia and McCune-Albright syndrome. *Int J Oral Maxillofac Surg* 1999; 28:366-71.
- Cohen M M Jr. Editorial comment: Fibrous dysplasia is a neoplasm. *Am J Med Genet* 2001; 98:290-3.
- Cohen M M Jr. Asymmetry: molecular, biologic, embryopathic, and clinical perspectives. *Am J Med Genet* 2001; 101:292-314.
- Candelieri G A, Glorieux F H, Prud'Homme J. Increased expression of the *c-fos* proto-oncogene in bone from patients with fibrous dysplasia. *N Engl J Med* 1995; 332:1546-51.
- Ruther U, Garber C, Komitowski D. Deregulated *c-fos* expression interferes with normal bone development in transgenic mice. *Nature* 1987; 325:412-6.
- Ruther U, Komitowski D, Schubert F R. *C-fos* expression induces bone tumors in transgenic mice. *Oncogene* 1989; 4:861-5.
- Yabut S M Jr, Kenan S, Sissons H A. Malignant transformation of fibrous dysplasia: a case report and review of the literature. *Clin Orthop* 1988; 228:281-8.
- Collins M T, Shenker A. McCune-Albright syndrome: new insights. *Endocrinol Diabetes* 1999; 6:119-25.
- Cohen M M Jr. On the definition of holoprosencephaly. *Am J Med Genet* 2001; 103:183-7.
- DeMyer W E, Zeman W, Palmer C G. The face predicts the brain: diagnostic significance of median facial anomalies for holoprosencephaly (arhinencephaly). *Pediatrics* 1964; 3:256-63.
- DeMyer W E. Holoprosencephaly (cyclopia-arhinencephaly). In: Vinken P J, Bruyn G W, editors. *Handbook of Clinical Neurology*. Amsterdam: North-Holland Publishing Co, 1977:431-78.
- Cohen M M Jr. Perspectives on holoprosencephaly. Part III. Spectra, distinctions, continuities, and discontinuities. *Am J Med Genet* 1989; 34:271-88.
- Barr M Jr, Cohen M M Jr. Autosomal recessive alobar holoprosencephaly

- with essentially normal faces. *Am J Med Genet* 2002; 112:28-30.
29. Benke P J, Cohen M M Jr. Recurrence of holoprosencephaly in families with a positive history. *Clin Genet* 1983; 24:324-8.
 30. Cohen M M Jr. Perspectives on holoprosencephaly. Part I. Epidemiology, genetics, and syndromology. *Teratology* 1989; 40:211-35.
 31. Cohen M M Jr, Gorlin R J. Genetic considerations in a sibship of cyclopia and clefts. *Birth Defects* 1969; 5(2):113-8.
 32. Cohen M M Jr, Jirásek J E, Guzman R T, Gorlin R J, Peterson M Q. Holoprosencephaly and facial dysmorphism: nosology, etiology and pathogenesis. *Birth Defects* 1971; 7(7):125-35.
 33. Morse R P, Rawnsley E, Sargent S K, Graham J M Jr. Prenatal diagnosis of a new syndrome: holoprosencephaly with hypokinesia. *Prenat Diagn* 1987; 7:631-8.
 34. Hockey A, Crowhurst J, Cullity G. Microcephaly, holoprosencephaly, hypokinesia – second report of a new syndrome. *Prenat Diagn* 1988; 8:683-6.
 35. Roessler E, Belloni E, Gaudenz K, Jay P, Berta P, Scherer S W, et al. Mutations in the human *Sonic Hedgehog* gene cause holoprosencephaly. *Nat Genet* 1996; 14:357-60.
 36. Roessler E, Belloni E, Gaudenz K, Vargas F, Scherer S W, Tsui L-C, et al. Mutations in the C-terminal domain of *Sonic Hedgehog* cause holoprosencephaly. *Hum Mol Genet* 1997; 6:1847-53.
 37. Nanni L, Ming J E, Bocian M, Steinhaus K, Bianchi D W, Die-Smulders C, et al. The mutational spectrum of the *Sonic Hedgehog* gene in holoprosencephaly: *SHH* mutations cause a significant proportion of autosomal dominant holoprosencephaly. *Hum Mol Genet* 1999; 8: 2479-88.
 38. Gripp K W, Wotton D, Edwards M C, Roessler E, Adès L, Meinecke P, et al. Mutations in *TGIF* cause holoprosencephaly and link NODAL signaling to human neural axis determination. *Nat Genet* 2000; 25: 205-8.
 39. Brown S A, Warburton D, Brown L Y, Yu C-Y, Roeder E R, Stengel-Kutkowski S, et al. Holoprosencephaly due to mutations in *ZIC2*, a homologue of *Drosophila* odd-paired. *Nat Genet* 1998; 20:180-3.
 40. Brown L Y, Odent S, David V, Glayau M, Dubourg C, Apacik C, et al. Holoprosencephaly due to mutations in *ZIC2*: alanine tract expansion mutations may be caused by parental somatic recombination. *Hum Mol Genet* 2001; 10:791-6.
 41. Wallis D E, Roessler E, Hehr U, Nanni L, Wiltshire T, Richieri-Costa A, et al. Mutations in the homeodomain of the human *SIX3* gene cause holoprosencephaly. *Nat Genet* 1999; 22:196-8.
 42. Ming J E, Kaupas M E, Roessler E, Brunner H G, Nance W E, Stratton R F, et al. Mutations of *PATCHED* in holoprosencephaly. *Am J Hum Genet* 1998; 63:A27.
 43. Roessler E, Du Y, Mullor J L, Casas E, Allen W P, Ellis I, et al. Loss-of-function mutations in the human *GLI2* gene cause holoprosencephaly and familial pan-hypopituitarism. American Society of Human Genetics 52nd Annual Meeting, October 15-19, 2002 Baltimore, Maryland, Abstract No. 132, p. 190.
 44. de la Cruz J M, Bamford R N, Burdine R D, Roessler E, Barkovitch A J, Donnai D, et al. A loss-of-function mutation in the CFC domain of *TDGF1* is associated with human forebrain defects. *Hum Genet* 2002; 110:422-8.
 45. Ouspenskaia M V, Karkera J D, Roessler E, Shen M M, Goldmuntz E, Bowers P, et al. Role of *FAST1* gene in the development of holoprosencephaly (HPE) and congenital cardiac malformations in humans. American Society of Human Genetics 52nd Annual Meeting, October 15-19, 2002 Baltimore, Maryland, Abstract No. 822, p. 313.
 46. Kelley R I, Roessler E, Hennekam R C M, Feldman G L, Kosaki K, Jones M C, et al. Holoprosencephaly in RSH/Smith-Lemli-Opitz syndrome: does abnormal cholesterol metabolism affect the function of *Sonic Hedgehog*? *Am J Med Genet* 1996; 66:478-84.
 47. Cohen M M Jr, Shiota K. Teratogenesis of holoprosencephaly. *Am J Med Genet* 2002; 109:1-15.
 48. Porter J A, Young K E, Beachy P A. Cholesterol modification of hedgehog signaling proteins in animal development. *Science* 1996; 274:255-9.
 49. Pepinsky R B, Zeng C, Wen D, Rayhom P, Baker D P, Williams K P, et al. Identification of a palmitic acid-modified form of human sonic hedgehog. *J Biol Chem* 1998; 273:14037-45.
 50. Chamoun Z, Mann R K, Nellen D, von Kessler D P, Bellotto M, Beachy P A, et al. Skinny hedgehog, an acyltransferase required for palmitoylation and activity of hedgehog signal. *Science* 2001; 293:2080-4.
 51. Burke R, Nellen D, Bellotto M, Hafen E, Senti K-A, Dickson B J, et al. Dispatched, a novel sterol-sensing domain protein dedicated to the release of cholesterol-modified hedgehog from signaling cells. *Cell* 1999; 99:803-15.
 52. Ingham P W, McMahon A P. Hedgehog signaling in animal development: Paradigms and principles. *Genes Dev* 2001; 15:3059-87.
 53. Ma Y, Erkner A, Gong R, Yao S, Taipale J, Basler K, et al. Hedgehog-mediated patterning of the mammalian embryo requires transporter-like function of dispatched. *Cell* 2002; 111:63-75.
 54. Cohen M M Jr. Nevroid basal cell carcinoma syndrome: molecular biology and new hypotheses. *Int J Oral Maxillofac Surg* 1999; 28: 216-23.