

## Clinico-Pathological Conference 2002

EW Odell,<sup>1</sup>FDSRCS, PhD, FRCPath, M Aldred,<sup>2</sup>PhD, FRCPath, FFOP, R Carlos,<sup>3</sup>DDS, A Curran,<sup>4</sup>DMD, K Heikinheimo,<sup>5</sup>DDS, MS, PhD, J Hille,<sup>6</sup>DDS, M Dent, FCPATH (SA), KH Ho,<sup>7</sup>BDS, FDSRCS, FAMS, FJ Kratochvil,<sup>8</sup>DDS, SH Lau,<sup>9</sup>BDS, FDSRCS, MSc, V Murrah,<sup>10</sup>MA, DMD, MS, P Reichart,<sup>11</sup>Dr med dent, FDSRCS, A Sood,<sup>12</sup>BDS, MFDSRCS, Y Tanaka,<sup>13</sup>DDS, PhD, WM Tilakaratne,<sup>14</sup>MS, FDSRCS, MRCPATH, WY Yih,<sup>15</sup>DDS

### Abstract

**Introduction:** Six cases are reported, each presented at the 11th Biennial Congress of the International Association of Oral Pathologists as an instructive case for differential diagnosis on the basis of clinical, imaging or histological features. **Clinical Picture:** Case diagnoses included a large, possibly intraosseous, myofibroma presenting with an oral mass; Langerhans cell histiocytosis with facial skin lesions; an intraosseous vascular hamartoma of the maxilla with worrying radiological features; an unusual mixed radiolucency of the jaw caused by cemento-ossifying fibroma; an osteosarcoma of the posterior mandible causing a well-defined radiolucency and an intraoral squamous cell carcinoma in a child.

Ann Acad Med Singapore 2004;33(Suppl):53S-58S

**Key words:** Fibroma; Haemangioma, Intraosseous; Histiocytosis, Langerhans cell; Myofibroma; Osteosarcoma

### Introduction

Six patients with unusual presentations of head and neck disease were presented for diagnosis by discussants at the conference. Images were accompanied by brief details and the differential diagnosis was explored by the discussants. The final diagnoses are presented in this paper with a short commentary on useful aspects of the process of differential diagnosis.

### Case 1: A Large Painless Intraoral Mass

Case submitted by Professor Jos Hille, Cape Town, South Africa and discussed by Dr Roman Carlos, Guatemala City, Guatemala

A 10-year-old boy presented with a rapidly growing painless intraoral soft tissue mass of 4 to 6 weeks' duration. No paraesthesia was reported. Figure 1a shows a broadly exophytic mass arising from alveolar ridge in the right mandibular premolar/molar area and expanding buccally and lingually. The occlusal aspect of the mass has been indented by the upper teeth. The lack of ulceration despite occlusal trauma is surprising given the short history and suggests both that the clinical course is longer than reported and that the lesion is benign. It appears relatively pale and thus seems not to be inflammatory or vascular in origin. The teeth visible anterior to the lesion do not appear to be displaced.

<sup>1</sup> GKT Dental Institute, Guy's Hospital, London, United Kingdom (Session Chairman)

<sup>2</sup> Mayne Health Dorevitch Pathology, Melbourne, Australia

<sup>3</sup> Servicio de Diagnostico Clinico y Patologico Guatemala City, Guatemala

<sup>4</sup> University of Mississippi, School of Dentistry, Jackson, Mississippi, USA

<sup>5</sup> University of Turku, Finland

<sup>6</sup> University of Cape Town, Cape Town, South Africa

<sup>7</sup> National University of Singapore, Singapore

<sup>8</sup> School of Dentistry, Oregon Health & Science University, Portland, Oregon, USA

<sup>9</sup> Institute for Medical Research, Kuala Lumpur, Malaysia

<sup>10</sup> University of North Carolina School of Dentistry, Chapel Hill, N. Carolina, USA

<sup>11</sup> Charite, Universitaetsmedizin Berlin, Germany

<sup>12</sup> GKT Dental Institute, Guy's Hospital, London, United Kingdom

<sup>13</sup> Ichikawa General Hospital, Tokyo Dental College, Tokyo, Japan

<sup>14</sup> University of Peradeniya, Sri Lanka

<sup>15</sup> School of Dentistry Oregon Health & Science University, Portland, Oregon, USA

Presented at the 11<sup>th</sup> Biennial Meeting of the International Association of Oral Pathologists and International Congress on Oral Pathology and Medicine in Singapore in August 2002.

Address for Reprints: Professor EW Odell, Department of Oral Pathology, GKT Dental Institute Guy's Hospital, Floor 28 Tower, Guy's Hospital, London SE1 9RT, United Kingdom.

Email: edward.odell@kcl.ac.uk

The differential diagnosis based on this information alone is broad and would have to include localised fibrous overgrowths, hyperplastic gingival lesions and fibrous neoplasms. Hamartomatous lesions of fibrous and vascular tissue are common in children and need to be included.

Figures 1b and 1c show a poorly-defined lesion with an epicenter at approximately the crest of the alveolus but probably within bone. The lesion extends from the surface to the level of the inferior dental canal and is uniformly radiolucent with an indistinct margin, possibly with small separate locules or extensions around the apex of the first premolar. The teeth are not resorbed but the cortical bone of the lamina dura has been resorbed from the first molar and both premolars and the alveolar cortex is breached without any periosteal new bone layer visible in or around the soft tissue mass. The second premolar is displaced downwards though its follicle appears intact and covered by a layer of cortical bone. There is possible widening of the periodontal ligament on the lower first premolar mesially that would be suspicious of malignancy. There is a suggestion of a periosteal reaction at the lower border.

Malignancy cannot be excluded and low-grade lesions such as fibromatoses would appear to be more likely than primary malignancy, metastasis from a childhood tumour such as Ewing's sarcoma or Burkitt lymphoma, the latter bearing in mind the geographical origin of the case. Further questioning revealed a history of fever, night sweats, weight loss and regional lymphadenopathy so that these possibilities must remain in the differential diagnosis.

#### *Diagnosis and Discussion*

Biopsy revealed the typical appearances of myofibroma with long, somewhat interdigitating fascicles of cellular fibrous tissue, whose myofibroblasts had no significant cytological atypia, relatively few mitoses and a prominent haemangiopericytomatous vascular pattern. The cells were typically broad spindled with prominent eosinophilic cytoplasm and were positive for desmin immunocytochemically; a slightly unusual pattern as smooth muscle actin is more frequently positive.

This lesion was a large but typical myofibroma. Of interest is the question whether the lesion had originated in the alveolar bone or from the gingival soft tissues. Because of the extensive intrabony component, it is the contributor's opinion that the tumour had most likely arisen from bone near the alveolar crest.

The patient was treated with a full thickness mandibular resection and reconstruction. At the time of presentation, the patient was alive and well.

#### REFERENCES

1. Foss RD, Ellis GL. Myofibromas and myofibromatosis of the oral region: a clinicopathological analysis of 79 cases. *Oral Surg* 2000;89:57-65.

2. Inwards CY, Unni KK, Beabout JW, Shives TC. Solitary congenital fibromatosis (infantile myofibromatosis) of bone. *Am J Surg Pathol* 1991;15:935-41.
3. Deutsch M, Wollman NR. Radiotherapy for metastasis to the mandible in children. *J Oral Maxillofac Surg* 2002;60:269-71.

#### **Case 2: Multiple Skin Lesions**

*Case submitted by Drs F James Kratochvil and Wei-Yung Yih, Portland, USA and discussed by Dr Lau Shin Hin, Kuala Lumpur, Malaysia*

A 12-month-old male baby presented to the paediatric dental department. Multiple skin lesions had been present for 6 months and affected the scalp, face, extremities, trunk and genital area. He had recently developed an ear discharge.

Figure 2 shows multiple glossy haemorrhagic papules, particularly around the lips, nose and eyes. These appear soft and exudative rather than dry, scaly or hard and may be ulcerated. The gingival margin is just visible around the lower incisors and this appears to be ulcerated.

The differential diagnosis must include infectious conditions, possibly associated with a primary or acquired immunodeficiency, purpura and haemorrhagic conditions, haemangiomas, Kaposi sarcoma and blistering conditions with blood-filled vesicles. These cannot be easily distinguished on the basis of the photograph alone. Further information required includes the possible presence of failure to thrive, bleeding problems, signs or symptoms of infection, sites of predilection of lesions elsewhere on the body, tests for immunoglobulin levels and neutrophil and cell-mediated immune function. However, although the features are relatively non-specific, the association of gingival lesions and skin lesions raises the possibility of infection associated with a neutrophil defect, Langerhans cell histiocytosis or a haematological malignancy.

#### *Diagnosis and Discussion*

Biopsies were obtained from skin lesions and diagnosis of Langerhans cell histiocytosis was made with the help of immunohistochemistry and transmission electron microscopy. The early onset and extensive involvement of skin, soft tissue and bone makes this an example of the acute disseminated form and suggests a more aggressive clinical course.

#### **Case 3: Multilocular Maxillary Radiolucency**

*Case submitted by Dr Alice Curran, Jackson, Mississippi, USA and discussed by Dr Youichi Tanaka, Tokyo, Japan*

A 33-year-old Caucasian man presented to his general dentist with pain and mild buccal expansion in the upper right quadrant. The teeth were not mobile and the patient had no lesions elsewhere. Plain radiographs, which were



Fig. 1. Case 1.

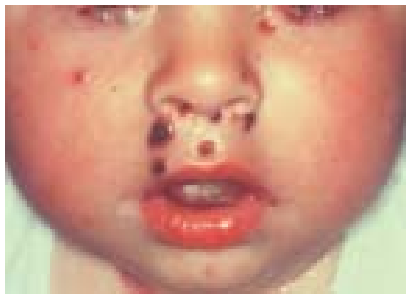


Fig. 2. Case 2.

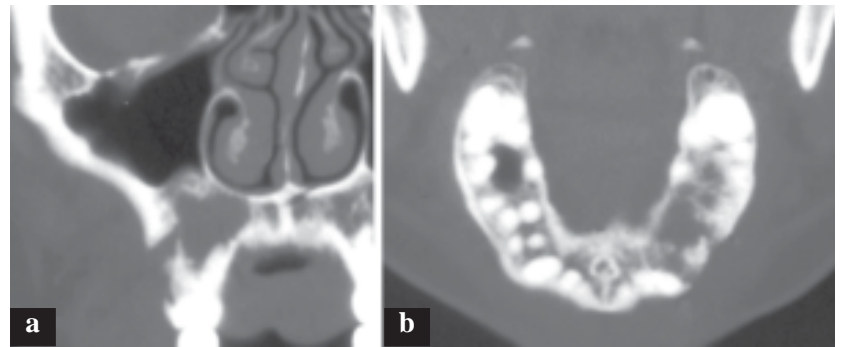


Fig. 3. Case 3.

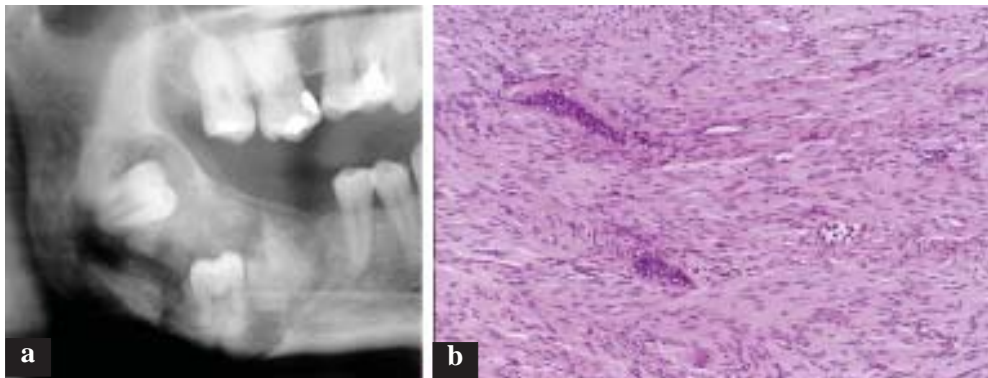


Fig. 4. Case 4.

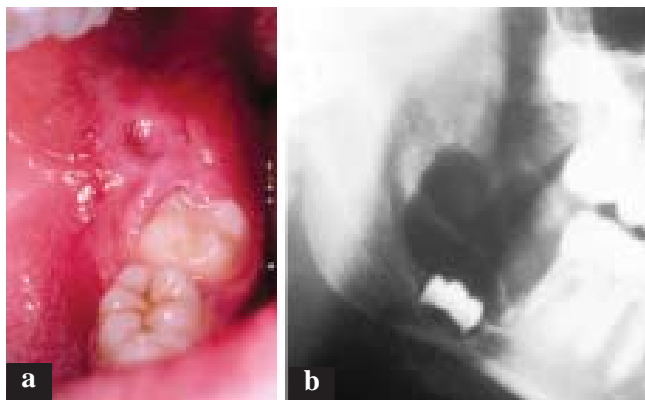


Fig. 5. Case 5.

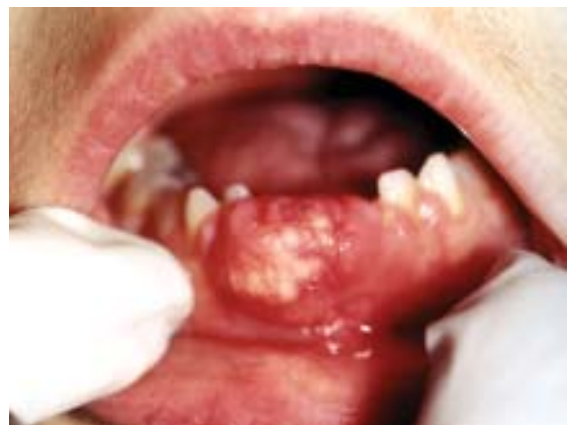

Fig. 6. Case 6.

not shown, were described as showing a ground glass or moth-eaten appearance and a biopsy was performed.

The surgeon indicated that the tooth roots appeared resorbed and that the bone appeared honeycombed, with total destruction of the cortex in a fashion resembling fibrous dysplasia or a malignant neoplasm with numerous internal voids. The CT scans shown (Figs. 3a & 3b) were taken after the incisional biopsy and showed the buccal access for biopsy. An extensive single radiolucent lesion with poorly-defined borders fills the alveolar process and body of the maxilla, extending around tooth roots from the lateral incisor to second molar region. Resorption of the roots was evident but there was little or no expansion for the size of the lesion, either into the floor of the antrum, palate or lateral wall of the maxilla.

The initial differential diagnosis would include primarily destructive benign and low-grade malignant lesions including haemangiomas, primary bone sarcomas and odontogenic tumours. Fibrous dysplasia might also be considered, except that the lesion is not sufficiently expansile and would have a late onset. The initial biopsy showed numerous large muscular arteries lying in the fibrous tissue between essentially normal trabeculae of lamellar bone. No bleeding problem was noted. An arteriogram was suggested but never performed.

#### *Diagnosis and Discussion*

On the basis of the radiological features, malignancy was felt to remain a possibility and the remaining lesion was curetted without bleeding problems. Histological examination again revealed typical features of an intraosseous vascular hamartoma, with some features of an arteriovenous malformation but apparently without its high vascular throughflow. This case serves to remind how the radiological and clinical features of intraosseous vascular lesions are very varied and may simulate malignancy.

#### REFERENCE

1. Langlais RP, Langland OE, Nortjé CJ. Multilocular radiolucencies. In: Langlais RP, Langland OE, Nortjé CJ, editors. *Diagnostic Imaging of the Jaws*. Malvern, PA: Williams & Wilkins, 1995:360-4.

#### **Case 4: A Mixed Radiolucency**

*Case submitted by Professor Michael Aldred, Melbourne, Australia and discussed by Dr WM Tilakaratne, Peradeniya, Sri Lanka*

A 32-year-old woman presented with a swelling of the right posterior mandible. Figure 4a shows a mixed radiolucent/radiopaque lesion extending from the mid ramus to the lower first molar region and from the lower border to the alveolar crest and anterior ramus. The lesion has a smooth outline with cortication and appears unilocular with some scalloping of the border. No first molar is

present in either arch; the lower second molar is displaced to the lower border and has a stunted root, the third molar is displaced slightly posteriorly. The radiolucency encloses both teeth. Mineralisation of approximately bone density lies in the radiolucent area, particularly around the second molar crown and between the molar crowns. The inferior dental canal is displaced downwards and the alveolar crest is expanded slightly.

The appearance is of a benign mixed radiolucent/radiopaque lesion and the age of the patient and relationship to the teeth make an odontogenic tumour highly likely. The differential diagnosis includes ameloblastic fibro-odontome, ameloblastic fibrodentinoma, a calcifying odontogenic cyst and odontome. A calcifying epithelial odontogenic tumour is possible but less likely. Odontogenic fibroma with mineralisation would be a remote possibility. Alternatively, a cemento-ossifying fibroma is possible but appears excluded by the histology.

A single histological image (Fig. 4b) provided from the incisional biopsy showed a bland fibrous spindle cell lesion of moderate cellularity and apparently without atypia or mitotic activity. Two islands of epithelium are included. Both are long and narrow and show no palisading of the basal cells or stellate reticulum centrally, but there is some vacuolation and juxta-epithelial hyalinisation. The epithelium appears odontogenic but relatively inactive though the islands are rather large for 'rests'. The pattern of spindle cells is not suggestive of a primarily fibrous or myofibromatous lesion such as desmoplastic fibroma, myofibroma, low-grade fibrosarcoma or myofibroblastic sarcoma, all of which may appear well-defined radiographically.

Taken together, the appearances would seem to indicate an odontogenic tumour and the histological appearances are those of odontogenic fibroma. Mineralisation may be seen in a minority of odontogenic fibromas but it is usually small in amount and either associated with the epithelium or forms small discrete islands of cementum-like bone. However, occasional cases with extensive bone formation have been reported and this seems the most likely diagnosis on the evidence available.

#### *Diagnosis and Discussion*

The histological appearances are misleading and result from incisional biopsy of the superficial part of the lesion. The odontogenic epithelium was very prominent but present only around the teeth and may have been hyperplastic perifollicular epithelium. Blocks throughout the rest of the lesion showed typical cemento-ossifying fibroma.

#### REFERENCE

1. Jones GM, Eveson JW, Shepherd JP. Central odontogenic fibroma. A report of two controversial cases illustrating diagnostic dilemmas. *Br J Oral Maxillofac Surg* 1989;27:406-11.

### Case 5: Radiolucency at the Angle of the Mandible

*Case submitted by Dr Kristiina Heikinheimo, Turku, Finland and discussed by Professor Ho Kee Hai, Singapore*

A 15-year-old boy presented with a painless swelling of the mandibular retromolar area. The lower right first molar and second molar were erupted with a small operculum over the second (Fig. 5a). Posterior to the second molar, the mandible is expanded and an indentation of the opposing tooth and some probably traumatic keratinisation lie distally. Bucco-lingual expansion was also present. Lip sensation was normal. The medical history was clear.

Radiographically, the panoramic tomograph (Fig. 5b) shows a sharply-defined radiolucency distal to the lower second molar extending from its distal root to the mid ramus and from the alveolar crest to the inferior dental canal. The crown of the third molar is displaced inferiorly to the lower cortex and root formation has not begun. The lesion appears uniformly radiolucent with a smooth non-corticated margin and some scalloping superiorly. The tip of the distal root of the second molar is resorbed but there is no widening of the adjacent periodontal ligament. The inferior dental nerve canal appears only slightly displaced but has lost its cortex and the alveolar cortex is thinned superiorly. The radiological appearance suggests either a benign but rapidly expanding lesion or a low-grade malignant neoplasm. Differential diagnosis includes odontogenic tumours such as ameloblastoma, but not odontogenic cysts, a cemento-ossifying fibroma with minimal mineralisation, myofibroma, vascular anomaly or low-grade sarcoma such as an odontogenic sarcoma, fibrosarcoma, desmoplastic fibroma or myofibroblastic sarcoma.

#### *Diagnosis and Discussion*

This unusual lesion comprised a moderately cellular fibroblastic stroma containing islands of odontogenic epithelium, some with peripheral palisading, and prominent formation of osteoid and bone. The lesional cells were positive only for vimentin on immunocytochemistry and had a MIB1 proliferation index of approximately 5%. The initial biopsy showed a cellular myxoid lesion of vacuolated cells. Histological diagnosis proved problematic and, similar to case 4, it was considered that the odontogenic epithelial component was an epiphenomenon rather than an ameloblastic fibrosarcoma or odontosarcoma.

Following extensive histopathological consultation, the lesion was diagnosed as low-grade osteosarcoma, osteoblastic type grade 1. Real-time polymerase chain reaction showed that the lesion contained only a small amount of dentine sialophosphoprotein, a major non-collagenous component of dentine, suggesting that the

lesion is osteogenic rather than odontogenic. The tumour was resected with a supra-omohyoid neck dissection and reconstructed with an osteo-myocutaneous iliac crest graft. Four years later, the lesion recurred locally and was excised with further reconstruction. Comparative genomic hybridisation revealed normal karyotypes in both the primary and secondary osteosarcoma, further suggesting that this is a low-grade tumor. There had been no further recurrence up to the date of the meeting.

#### REFERENCE

1. Tarkkanen M, Bohling T, Gamberi G, Ragazzini P, Benassi MS, Kivioja A, et al. Comparative genomic hybridisation of low-grade central osteosarcoma. *Mod Pathol* 1998;11:421-6.

### Case 6: Anterior Gingival Swelling and a Complex Medical History

*Case submitted by Professor Valerie Murrah, Chapel Hill, USA and discussed by Professor Peter Reichart, Berlin, Germany*

A 6-year-old boy was referred to an oral and maxillofacial surgeon for treatment of this mass on the alveolus that had been present for a few weeks. He had a complex medical history including a heart transplant within the first year of life, required for cardiomyopathy. At the age of 5, he developed lymphoma of the maxillary sinuses and this was treated by chemotherapy. At presentation, the patient was on the following medications: ciclosporin, amoxicillin, omeprazole and trimethoprim/sulfamethoxazole.

Figure 6 shows a relatively well-circumscribed rounded sessile apparently soft tissue mass on the anterior lower alveolus. Vessels are prominent over the surface, showing against a white background that appears to be the internal colour of the lesion rather than keratin or fibrin on the surface. The surrounding mucosa is not inflamed. A small ulcer centrally at the top of the lesion would be consistent with trauma from the upper incisors. It is not possible to see whether the teeth are underneath the lesion or whether they may have failed to erupt. There is mild gingival hyperplasia and hypertrichosis of the upper lip.

Hypertrichosis, gingival hyperplasia and malignant tumours, particularly lymphomas, are common side effects of treatment with ciclosporin. On the basis of the clinical appearance it is not possible to determine whether this might be a reactive lesion or a neoplasm and, if a neoplasm, whether it might be benign, malignant or a metastasis. However, the absence of extensive ulceration favours a benign or low-grade lesion.

The lesion does not look like gingival hyperplasia associated with ciclosporin or any of the common reactive gingival fibroepithelial hyperplasias. The most likely diagnosis is a recurrence of a previous lymphoma. A

radiograph is required to determine the presence of underlying teeth and bone involvement and to exclude the possibility of an odontogenic or other central lesion. A rare possibility would be Barth syndrome, an X-linked condition with (cardio)myopathy, neutropenia and organic aciduria. Post-transplant lymphoproliferative disorder is common. However, no rare condition need be invoked as lymphoma and malignancy of the skin and lips are the commonest sites affected by post-transplant malignancy.

*Diagnosis and Discussion*

This is a highly unusual case of squamous cell carcinoma

arising from ciclosporin treatment. The age and site are most unusual and the appearance is not typical of gingival carcinoma in adults. The white appearance is presumably due to keratin formation.

REFERENCES

1. Varga E, Tyldesley WR. Carcinoma arising in cyclosporin-induced gingival hyperplasia. *Br Dent J* 1991;171:26-7.
2. Alexander JW, First MR, Hariharan S, Penn I, Schroeder T, Ryckman F, et al. Recent contributions to transplantation at the University of Cincinnati. *Clin Transpl* 1991:159-78.