

Melanocytic Lesions of the Face: Diagnostic Pitfalls*

SW McCarthy,^{1,2}*MBBS, FRCPA*, RA Scolyer,^{1,2}*MBBS, FRCPA*

Abstract

The pathologist often has a difficult task in evaluating melanocytic lesions. For lesions involving the face the consequences of misdiagnosis are compounded for both cosmetic and therapeutic reasons. In this article, the pathological features of common and uncommon benign and malignant melanocytic lesions are reviewed and pitfalls in their diagnosis are highlighted. Benign lesions resembling melanomas include regenerating naevus, "irritated" naevus, combined naevus, "ancient naevus", Spitz naevus, dysplastic naevus, halo naevus, variants of blue naevi, balloon and clear cell naevi, neurotised naevus and desmoplastic naevus. Melanomas that can easily be missed on presentation include desmoplastic, naevoid, regressed, myxoid and metastatic types as well as so-called malignant blue naevi. Pathological clues to benign lesions include good symmetry, V-shaped silhouette, absent epidermal invasion, uniform cellularity, deep maturation, absent or rare dermal mitoses and clustered Kamino bodies. Features more commonly present in melanomas include asymmetry, peripheral epidermal invasion, heavy or "dusty" pigmentation, deep and abnormal dermal mitoses, HMB45 positivity in deep dermal melanocytes, vascular invasion, neurotropism and satellites. Familiarity with the spectrum of melanocytic lesions and knowledge of the important distinguishing features should assist in interpretation. Occasionally, the use of ancillary studies may also provide additional useful information. Application of standard criteria for diagnosing such lesions should enable the correct diagnosis to be established in most cases.

Ann Acad Med Singapore 2004;33(Suppl):3S-14S

Key words: Diagnosis, Melanoma, Naevus, Pathology

Introduction

Cutaneous melanocytic lesions are amongst the commonest tumours in all races but are more common in Caucasians with fair skin. Although most are benign melanocytic naevi that are readily diagnosed clinically, melanocytic lesions are commonly excised because of the concern that they may represent a melanoma or because of cosmetic reasons. The pathological criteria that distinguish malignant melanocytic lesions from those that are benign are well-recognised and by applying these criteria the histopathologist can usually make a definitive diagnosis for any given melanocytic lesion. Occasionally, difficulties occur in diagnosis which may result in benign lesions being diagnosed as malignant or vice versa. The consequences of misdiagnosis may be disastrous, especially for lesions involving the face. Benign naevi that are treated as melanoma

may cause unnecessary disfiguring, scarring and morbidity while melanomas misdiagnosed as naevi may result in delayed treatment and death of the patient. Recognition of the potential pitfalls in the diagnosis of melanocytic lesions of the face may prevent these potentially disastrous consequences.¹

The histopathological diagnosis of melanocytic lesions usually requires assessment of a complete excision specimen. This is because a final diagnosis requires interpretation of the macroscopic appearance, a range of architectural and cytological features and assessment of the host response. None of the individual features alone is diagnostic as many of the individual criteria may be seen in both naevi and melanomas. For example, both benign Spitz naevus and melanoma may include large epithelioid cells and dermal mitoses and both may show Pagetoid epidermal

¹ Department of Anatomical Pathology

² Sydney Melanoma Unit and Melanoma and Skin Cancer Research Institute

Royal Prince Alfred Hospital, Camperdown, Australia

Address for Reprints: Dr Richard Scolyer, Department of Anatomical Pathology, Royal Prince Alfred Hospital, Missenden Rd, Camperdown, NSW 2050, Australia.

Email: richard.scolyer@email.cs.nsw.gov.au

* Modified from Plenary Lecture 3 presented by SW McCarthy at the 11th Biennial Meeting of the International Association of Oral Pathologists and International Congress on Oral Pathology and Medicine in Singapore in August 2002

invasion.^{2,3} As the features that need to be assessed to make a diagnosis include those at the deep aspect and peripheral margins of the lesion, it is often very difficult and sometimes impossible to make a definite diagnosis of a naevus or melanoma on incomplete, tiny or damaged biopsy specimens. An important complication of an incomplete biopsy of a melanocytic naevus is that it may subsequently regenerate in the region of the previous biopsy. The pathological features of regenerating naevi often include features that are usually associated with the diagnosis of melanoma and such lesions can be easily over-diagnosed as malignant and hence are sometimes referred to as “pseudomelanomas”.⁴ For these reasons, the use of incomplete biopsies (such as shave or punch biopsies) as techniques for the pathological diagnosis of melanocytic lesions should be strongly discouraged.¹

In this article, we review the pathological features of common and uncommon melanocytic lesions, including benign lesions that may resemble melanomas and melanomas that can easily be missed on presentation. Important distinguishing features and potential pitfalls in diagnosis are highlighted.

Misdiagnosis of Naevi as Melanomas

Benign melanocytic naevi may be misdiagnosed as melanomas (Table 1). This is particularly likely to occur with lesions that display some of the pathological features of melanomas. Other potentiating factors may include inexperience, a low threshold for malignancy, fear of litigation, stress and working long hours. The features of melanocytic naevi that make them prone to be misdiagnosed as melanomas and their important distinguishing features are presented below. Important pathological features that generally favour a benign diagnosis are listed in Table 2.

Regenerating Compound Naevus (“Pseudomelanoma”)

A melanocytic naevus may regenerate following its incomplete removal or other trauma, usually in association with a scar (Fig. 1a). Regenerating naevi are particularly

prone to be misdiagnosed as melanomas as they may show some of the microscopic features that are usually associated with melanomas.^{4,7} These include the presence of pagetoid epidermal spread, some cytological atypia, occasional dermal mitotic figures and HMB45 positivity in the dermis. However, there are microscopic and clinical features that should enable the correct diagnosis to be established. There is usually a history of trauma (such as a previous shave biopsy or incomplete excision) within a few months prior to the biopsy although this is sometimes not provided in the clinical notes that accompany the specimen. Microscopic findings such as variable epidermal thickening and shallow and/or deep scarring in the dermis are clues to previous trauma. Although the residual melanocytic naevus may show foci of epidermal invasion, in contrast to melanomas the melanocytes are usually small and the pagetoid spread occurs only in the epidermal region over the scar and/or at the edge of the scar (Fig. 1b). Although occasional dermal mitoses may be seen, these are never frequent or abnormal as is often seen in melanomas. The residual naevus usually displays typical histological features. Often there is a merging of the naevus cells in the area of regeneration with those of the native naevus, rather than 2 discrete populations of cells often seen in melanomas associated with a dermal naevus.

Post-excisional Junctional Melanocytic Hyperplasia with or without Atypia

It is not uncommon to observe single cell lentiginous melanocytic hyperplasia in the junctional epidermis in wide excision specimens or initial excision specimens for basal cell carcinomas or other malignancies and this should not be confused with residual or de novo in situ melanoma.^{6,8} This is probably a reactive proliferation, possibly stimulated by the release of growth factors as part of the healing process. Occasionally, the hyperplasia may be associated with mild and focally moderate cytological atypia making the distinction from in situ melanoma more difficult. In such instances, comparison with the original tumour may be helpful. If the change extends well beyond the scar, often to the re-excision margin, it is more likely to be part of a generalised change, field effect or lentiginous junctional dysplastic naevus of the elderly. The possibility of a

Table 1. Benign Cutaneous Melanocytic Lesions which may Resemble and be Misdiagnosed as Melanoma

• Regenerating naevus	• Blue naevus
• “Irritated” naevus	– Dendritic
• Post-excisional junctional hyperplasia	– Cellular
	– Deep penetrating
• Cellular/hyperplastic nodule in congenital naevus	
• Combined naevus	
• Ancient naevus	• Balloon and clear cell naevi
• Spitz naevus	• Neurotised naevus
• Dysplastic naevus	• Desmoplastic naevus
• Naevus in pregnancy	• Halo naevus

Table 2. Important Pathological Features that Favour a Benign Diagnosis for a Melanocytic Lesion

• Good symmetry
• V-shape silhouette
• Epidermal invasion absent
• Uniform cellularity
• Deep maturation
• Absent deep mitoses
• Clustered Kamino bodies

Hutchinson’s melanotic freckle (HMF) or in situ melanoma should not be diagnosed unless there is excessive atypia, confluent or nested growth or Pagetoid epidermal invasion.

“Irritated” Naevus

A variety of agents, especially sunburn, rubbing, topical agents and insect bites, may cause atypical features in melanocytic naevi that raise the possibility of malignancy and so a relevant history is often helpful. Minor irritation produces mild epidermal thickening, parakeratosis and upward migration of intraepidermal melanocytes and, when present, these features should raise the possibility of an irritated lesion. In contrast to melanomas, the intraepidermal melanocytes are usually small and tend to become smaller and pyknotic as they extend upwards in the epidermis near or to the granular layer. Pathological features associated with more marked irritation include vesicle formation (particularly seen following sunburn), spongiosis and an inflammatory cell infiltrate.

Naevi associated with an eczematous process often have spongiosis, a mixed inflammatory infiltrate (especially lymphocytes and eosinophils) and sometimes a clinically apparent “halo” reaction.⁹ Such melanocytic lesions are sometimes termed Meyerson’s naevus.

Cellular/Hyperplastic/Proliferating Nodules in Congenital Naevus

Although congenital naevi are rare on the face, as in other sites, they may develop cellular/hyperplastic/proliferating nodules.^{10,11} Their occurrence in an adult should always arouse suspicion and their distinction from melanoma may be difficult. The nodules are often small (less than 5 mm) and usually involve the superficial dermis, but may be larger and may involve almost the full thickness of the dermis. They are usually composed of a monotonous population of slightly enlarged epithelioid or spindle naevoid cells with minimal atypia and nuclear pleomorphism. However, they may show mitotic activity. The cells at the periphery tend to merge with those of the adjacent congenital naevus. Pigmented spindle cell nodules may represent a blue naevus component of a congenital naevus (combined

naevus). Features favouring malignancy in these nodules are necrosis, poor circumscription, marked nuclear atypia, prominent and variable nucleoli and frequent or atypical mitoses. Recent genetic evidence using comparative genomic hybridisation supports the interpretation that hyperplastic or proliferation nodules in congenital naevi do not represent early melanomas.^{12,13} Nonetheless, there are some lesions which display features of both a hyperplastic/proliferating nodule and melanoma. We designate such lesions as atypical proliferative nodules of uncertain biological potential and recommend complete excision and close clinical follow-up.

Combined Naevus

Combined naevi are a frequent source of concern for patients, parents, clinicians and pathologists as they are easily overdiagnosed as melanoma both clinically and histologically.¹⁴ They are defined as a melanocytic naevus that includes cells from 2 types of naevi. Possible components/combinations of naevi from 3 main groups may form a combined naevus and these groups are presented in Table 3. The 2 components may be separate or intermingled. It is because of the presence of different components that combined naevi may appear clinically heterogeneous and therefore clinically suspicious for melanoma. Furthermore, it is the presence of these 2 cellular components, particularly when 1 consists of larger, heavily pigmented cells, that may raise the possibility of melanoma histopathologically. By far the most common variant of combined naevus includes a common naevus (compound or dermal) with a component of blue naevus of “deep penetrating” type (Fig. 2).¹⁵ The latter may be heavily pigmented and occasionally shows a non-atypical dermal mitotic figure. Despite being composed of a variety of cell types and at times appearing asymmetrical, combined naevi usually lack other features of malignancy such as an in situ component, poor maturation, marked nuclear pleomorphism, frequent dermal mitotic activity and a host response. Occasionally tumour-infiltrating lymphocytes (TILs) may be present within an otherwise typical dysplastic naevus or Spitz naevus component. This is suggestive of early regression and should not be misdiagnosed as melanoma.

The entity “ancient” naevus, as described by Kerl and colleagues,¹⁶ is found mainly on the face in those over 50 years of age. They are of long standing and in our view are probably variants of combined naevi that include a combination of common naevus (small naevus cells) and degenerating Spitz naevus (larger pleomorphic cells).

Spitz Naevus

Spitz naevus can cause major problems in diagnosis at any site, even in adolescence.¹⁷ The diagnosis of Spitz

Table 3. Combined Naevi are Composed of 2 or more Components of Different Types of Naevi from Groups A, B or C

Group A Common naevus	Group B Blue naevus	Group C Spitz naevus
• Congenital	• Deep penetrating	• Conventional
• Dysplastic	• Cellular	• Regressing
• Regressing	• Epithelioid	• Desmoplastic/sclerosing
• Junctional	• Dendritic	
• Compound		
• Dermal		

Table 4. Important Pathological Features that Favour Malignancy in a Melanocytic Lesion

• Asymmetry
• Peripheral epidermal invasion
• Heavy pigmentation
• Deep and abnormal mitoses
• Nuclear pleomorphism
• HMB45 positive deep dermal cells
• Vascular invasion, neurotropism, satellites

naevus requires the presence of a constellation of pathological features, including both cytological and architectural, none of which alone is diagnostic.² These features may include small size (usually less than 10 mm), symmetry, diffuse epidermal thickening, hypergranulosis, terminal junctional nests, retraction clefts around junctional nests, Kamino bodies, “raining down” pattern (spindle-shaped cells arranged perpendicular to the surface), Spitzoid cytology, maturation with depth, non-brisk (less than 2 per mm²) and non-atypical dermal mitotic activity (usually confined to the superficial half of the dermal component) and telangiectatic blood vessels in the superficial dermis (Fig. 3).^{18,19} Early junctional lesions may mimic in situ malignant melanoma with epithelioid cells and foci of epidermal invasion and have been termed pagetoid Spitz naevus.^{20,21} The epithelioid cells of Spitz naevi tend to be paler and lack the nuclear pleomorphism of melanoma. They are almost always associated with epidermal thickening and hypergranulosis. Compound Spitz naevi may have many features in common with melanomas including epidermal invasion, epidermal thickening, Kamino bodies and dermal mitoses. However in Spitz naevi, epidermal invasion is usually central and consists of nests as well as single cells.³ Kamino bodies tend to be larger, paler and clustered in Spitz naevi and mitoses are less frequent (less than 2 per mm²), rarely deep and not abnormal.² The cell borders of the deep dermal component also tend to merge with the dermal collagen, rather than having well-defined cell margins, and they do not form expansile dermal nodules. Dermal Spitz naevus cells are also almost always HMB45-negative.

Atypical Spitz Tumours

While tumours that display all or most of the typical features of a Spitz naevus should be appropriately diagnosed, it is recognised that it can be very difficult or impossible to predict, even by experts, the biological behaviour of some Spitzoid melanocytic tumours with atypical pathological features.²²⁻²⁴ We classify such tumours as atypical Spitzoid tumours of uncertain malignant (biological) potential (Fig. 4).² We recommend complete excision and careful clinical follow-up. Sentinel node biopsies are now being performed on some tumours greater than 1 mm in thickness in an

attempt to determine their malignant potential.^{25,26}

Pigmented Spindle Cell Naevus (of Reed) and Pigmented Epithelioid Junctional Naevus

Pigmented spindle cell naevus (of Reed) and pigmented epithelioid junctional naevus are frequently confused with melanoma but are uncommon in the head and neck region. They are probably variants of Spitz naevus.^{18,27} They share with Spitz naevi the histological features of good symmetry, more or less diffuse epidermal thickening and hypergranulosis and are distinguished from it by the presence of more heavily pigmented cells. If present, their usually small dermal component shows maturation with depth. Kamino bodies and epidermal invasion may also be seen. It is the presence of the latter feature that may prompt overdiagnosis as melanoma. However, as with other melanocytic tumours, the pathological diagnosis rests along with clinical data on the assessment of a range of both architectural and cytological features none of which alone is diagnostic of any particular lesion.

Dysplastic Naevus

Dysplastic naevi are characterised histopathologically by the presence of architectural disorder and cytological atypia.^{28,29} They are important clinically as they have an inherent risk of transforming into melanoma and are also a marker of increased risk of developing melanoma at other sites. Dysplastic naevi of either junctional or compound types often develop over a pre-existing common naevus. The degree of lentiginous melanocytic hyperplasia, lamellar collagen (organised periretal stromal fibroplasia) in the superficial dermis and associated lymphocytic infiltrate is variable (Fig. 5). In our experience, the degree of lamellar fibroplasia is greater in those lesions associated with the dysplastic naevus syndromes. Features of concern in dysplastic naevi include those with moderate to severe cytological atypia, focal epidermal invasion (except by small cells with pyknotic nuclei) or dermal mitoses (which are otherwise usually rare and not abnormal in morphology). While the presence of any one of these features alone is not sufficient for a diagnosis of melanoma, when they occur in combination, especially in association with an expansile growth pattern of the dermal component, poor maturation and asymmetry, they will in most instances be a manifestation of malignancy.

Some dysplastic naevi are predominantly lentiginous and appear to form a continuous spectrum with Hutchinson's melanotic freckle (lentigo maligna), lentiginous melanocytic hyperplasia of the elderly and solar lentigo. Lentiginous junctional dysplastic naevi are distinguished from Hutchinson's melanotic freckle by their lack of epidermal atrophy, marked solar elastosis, skin adnexal involvement and Pagetoid spread.

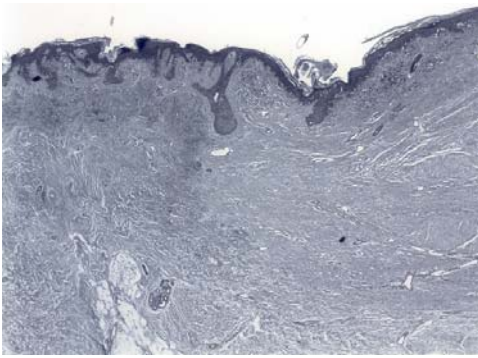


Fig. 1a. At low magnification, the residual part of this compound naevus is present adjacent to a thick dermal scar. [Haematoxylin and eosin (H&E) x40]

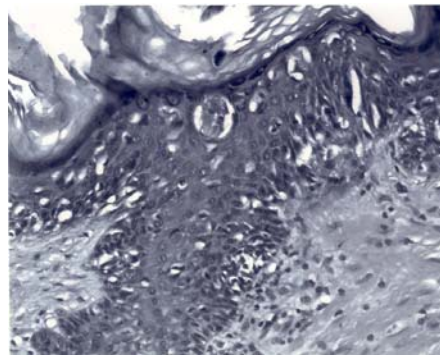


Fig. 1b. There is focal pagetoid spread of non-atypical small melanocytes within a thickened epidermis overlying the scar. This should be distinguished from the pagetoid spread of in situ melanoma. (H&E x400)

Fig. 1. 8-year-old male: regenerating naevus.

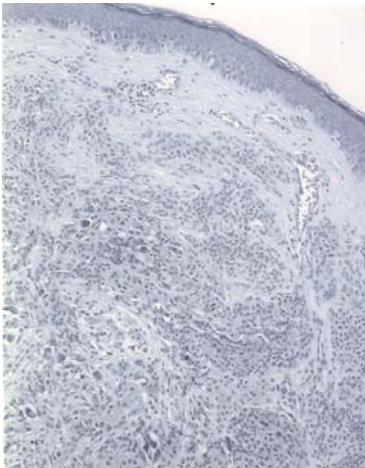


Fig. 2a. This compound melanocytic lesion is composed of compound and blue naevus components. (H&E x40)

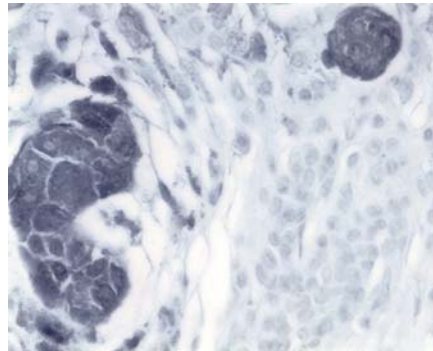


Fig. 2b. An HMB45 stain is very useful in highlighting the blue naevus component. (HMB45 immunohistochemical stain x400)

Fig. 2. 33-year-old female: combined naevus.

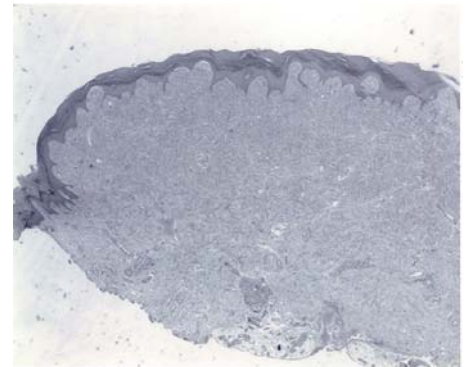


Fig. 3a. The lesion is symmetrical and there is diffuse epidermal thickening and hypergranulosis. (H&E x12.5)

Fig. 3. 7-year-old male: compound Spitz naevus. The diagnosis is made on the basis of a constellation of architectural and cytological features, none of which alone is diagnostic.

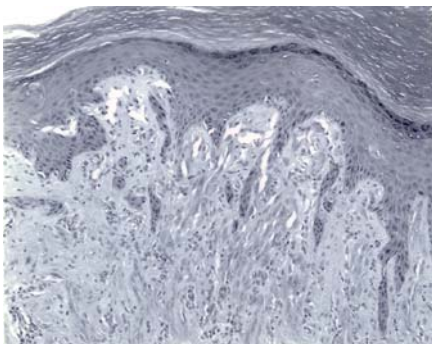


Fig. 3b. Scattered Kamino bodies and telangiectatic blood vessels are present. The spindle-shaped cells display a “rain down” pattern. (H&E x200)

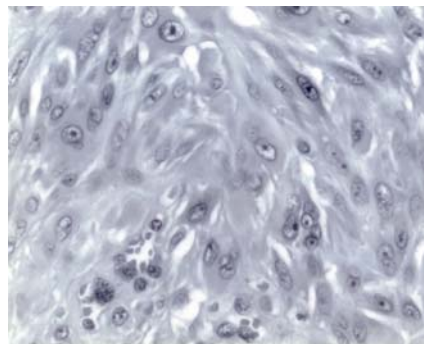


Fig. 3c. The cells in the superficial dermis are larger than those at the base of the lesion (Fig. 3d), i.e. “maturation” is present. (H&E x400)

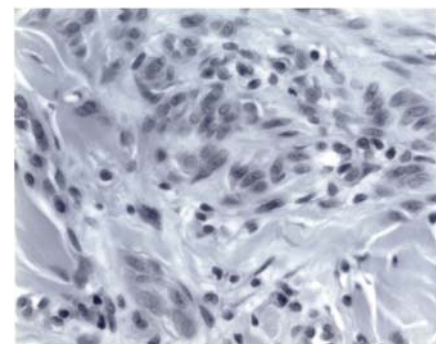


Fig. 3d. The deep dermal Spitz cells are small, merged with the dermal collagen and are devoid of significant pleomorphism or mitotic activity. (H&E x400)

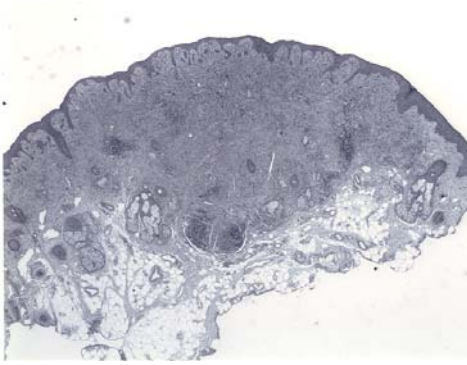


Fig. 4a. This compound melanocytic lesion has Spitzoid features including symmetry at low power. Atypical features at low power include patchy epidermal thinning, the presence of an expansile dermal growth pattern and the presence of an associated lymphocytic infiltrate. (H&E x40)

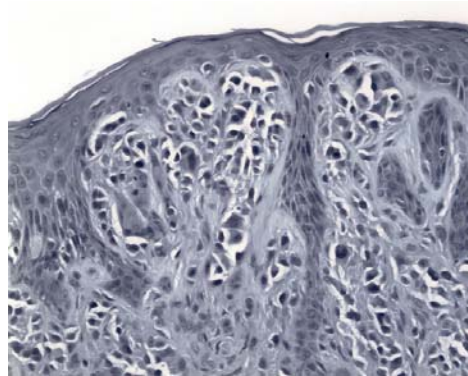


Fig. 4b. The Spitzoid cells are large with amphophilic cytoplasm. An occasional Kamino body is present (left of picture). (H&E x400)

Fig. 4. 37-year-old male: atypical Spitz tumour. The prediction of the biological behaviour of atypical Spitzoid tumours is very difficult. Although this case does not display diagnostic features of malignancy, given the atypical features it should be regarded as having uncertain malignant potential.

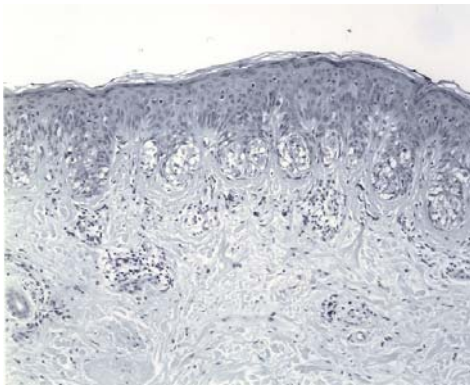


Fig. 5a. This junctional dysplastic naevus shows mild cytological atypia and prominent lamellar collagenous fibroplasia around the rete ridges. (H&E x100)

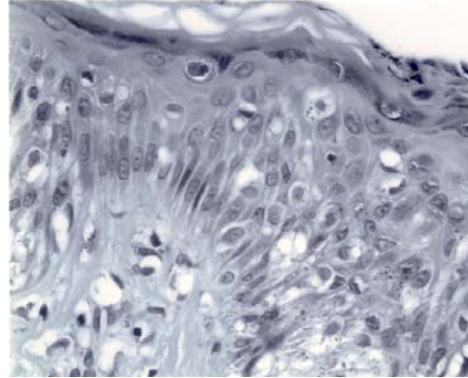


Fig. 5b. Occasional suprabasilar pyknotic melanocytes may be observed in dysplastic naevi and does not indicate in situ melanoma. (H&E x400)

Fig. 5. 55-year-old female: dysplastic naevus.

“Halo” Naevus

The clinical term “halo naevus” describes a naevus surrounded by a sharply demarcated zone of depigmentation.³⁰ The halo is caused by the destruction of both lesional and adjacent non-lesional melanocytes by cytotoxic T-lymphocytes. The halo phenomenon indicates early regression and may be observed in other types of naevi and also in melanomas, although it is rarely if ever observed in blue naevi. In general, the lymphoid reaction tends to be symmetrical and uniform in halo naevi in contrast to that usually associated with regressing melanomas. The commonest “halo naevus” appears to be a regressing compound dysplastic naevus with a lymphocytic infiltrate (TILs) in both the junctional and dermal components. The junctional component may be rather florid but in contrast to a regressing melanoma, there is no epidermal invasion and cytological atypia is at most moderate. The small dark HMB45-negative naevus cells of the dermal component may show an occasional mitosis but

in the absence of other atypical features, this does not indicate malignancy. “Halo Spitz” naevi show a similar pattern but the melanocytes are larger and epidermal thickening more prominent.^{31,32}

Naevus in Pregnancy

Benign naevi (including common naevi and blue naevi) may grow during pregnancy and this correlates histologically with increased junctional activity.³³⁻³⁵ The melanocytes may appear activated and may show non-atypical mitoses in the dermal component but, at the base of the lesion, lack significant nuclear pleomorphism, nucleolation or an expansile dermal growth pattern.³⁶ Dysplastic naevi and melanomas may also present during pregnancy and should be diagnosed using standard criteria.

Balloon Cell Naevus and Clear Cell Naevus

The cytoplasmic clearing in balloon cell and clear cell naevi is caused by vacuolar degeneration and confluence of

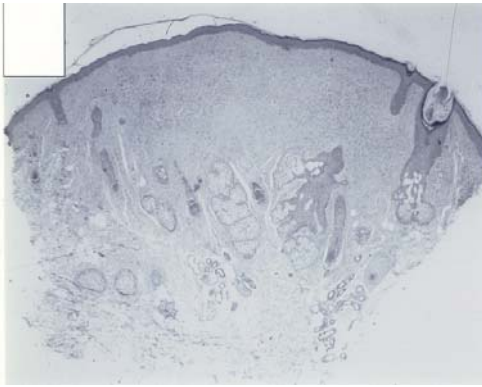


Fig. 6a. Unlike most desmoplastic melanomas, desmoplastic naevi lack an atypical epidermal component and are non-infiltrative and symmetrical lesions. (H&E x25)

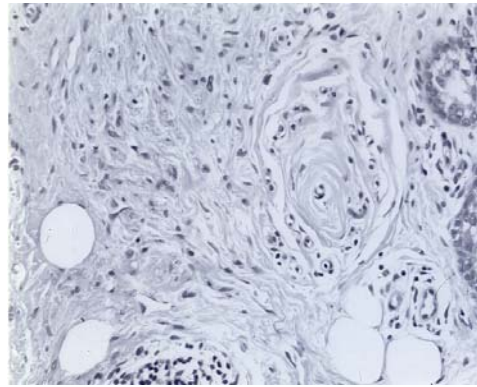


Fig. 6b. The cells show no atypia and focal neurotisation at high power. (H&E x400)

Fig. 6. 42-year-old male: desmoplastic naevus.

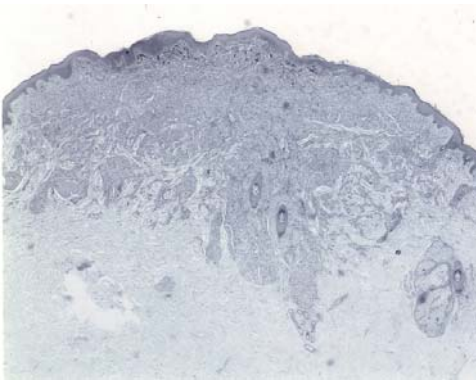


Fig. 7a. At low power, the lesion has a wedge-shaped profile with the apex of the wedge involving the deep dermis. Only a minimal epidermal junctional component is present. (H&E x40)

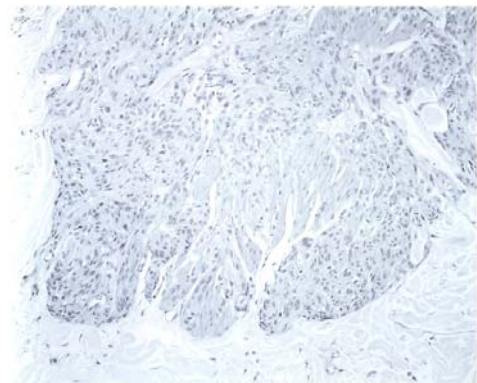


Fig. 7b. The cells at the deep margin are plump but show only minimal pleomorphism. (H&E x200)

Fig. 7. 29-year-old female: deep penetrating naevus.

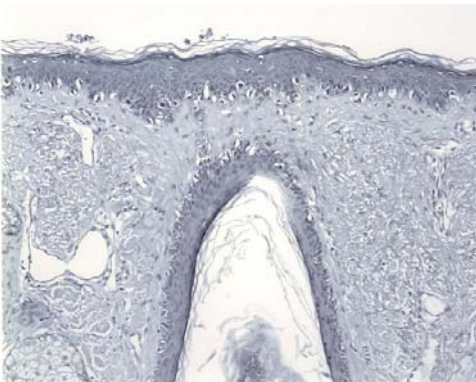


Fig. 8a. The atrophic epidermis shows loss of normal rete ridges and there is marked dermal solar elastosis. A lentiginous proliferation of melanocytes is evident that involves a pilosebaceous unit. (H&E x100)

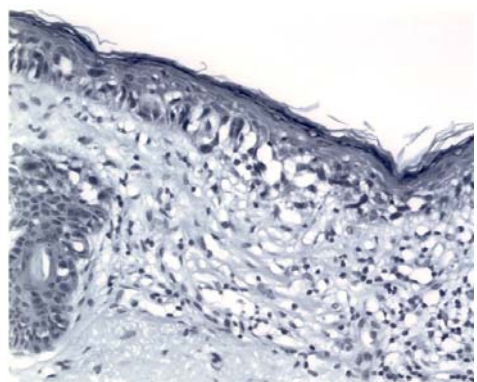


Fig. 8b. The melanocytes show moderate to marked atypia and form an occasional junctional nest. There is mild inflammation and fibrosis within the superficial dermis. However, no dermal invasive melanoma is present. (H&E x400)

Fig. 8. 78-year-old female: Hutchinson's melanotic freckle (lentigo maligna).

melanosomes or intracytoplasmic lipid accumulation.³⁷⁻³⁹ Both these types of naevi are rare and need to be distinguished from their malignant counterparts which have dermal mitoses, nuclear pleomorphism, HMB45 positivity, increased nuclear to cytoplasmic ratio and often

epidermal invasion.⁴⁰

Neurotised and Desmoplastic Naevi

As naevi mature with progressive ageing, they may show prominent neurotisation and include structures resembling



Fig. 9a. The dermis is expanded and there are scattered collections of lymphocytes. The latter is a frequent subtle clue to the diagnosis. (H&E x100)

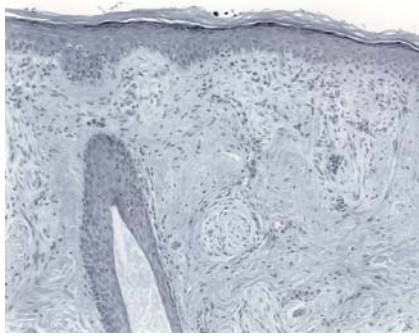


Fig. 9b. Perineural invasion is often seen. (H&E x200)

Fig. 9. 69-year-old male: desmoplastic melanoma.

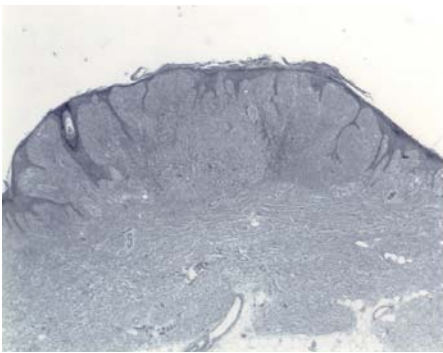


Fig. 10a. A clue to the diagnosis at low power is the presence of elongated long thin rete ridges. (H&E x12.5)

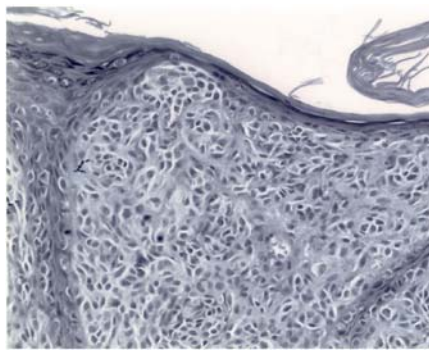


Fig. 10b. Focal pagetoid epidermal invasion is present and there are a number of dermal mitoses. (H&E x200)

Fig. 10. 41-year-old female: naevoid melanoma.

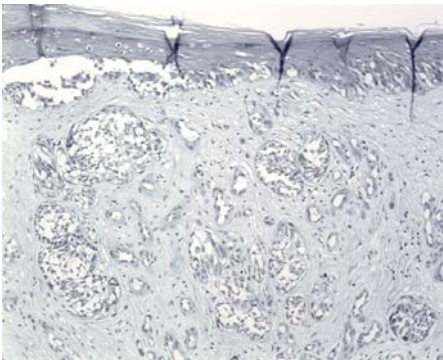


Fig. 11. Abdomen of 47-year-old male: melanoma of superficial spreading type. The tumour displays prominent pagetoid epidermal invasion by cells with marked nuclear atypia. The dermal invasive component is formed by atypical cells within reactive stroma. The latter shows angiofibroplasia and is indicative of regression. (H&E x200)

lack the abnormal junctional melanocytes, atypical elongated nuclei, scattered foci of lymphocytes and frequent neurotropism which are often the only clues to the diagnosis of a subtle desmoplastic melanoma.^{45,46}

Blue Naevi

Histological variants of blue naevi include common or dendritic blue naevus, cellular blue naevus, deep penetrating naevus and epithelioid blue naevus.^{47,48} Because these lesions may show some cytological atypia, occasional dermal mitoses and perineural involvement and are nearly always HMB45-positive, they may be misdiagnosed as melanomas.

Sclerosing blue naevi can usually be separated from desmoplastic melanomas by the presence of melanin pigment and positive HMB45 staining and the absence of an atypical junctional component, asymmetry or an associated lymphoid infiltrate. Sometimes metastatic melanomas may closely resemble dendritic blue naevi.⁴⁹ The presence of an associated lymphoid infiltrate, subtle nuclear pleomorphism and mitotic activity together with a prior history of a melanoma are the most useful distinguishing features.

Meissner corpuscles, Verocay bodies and nerve twigs.^{41,42} Lesions in which the latter predominate are sometimes referred to as desmoplastic naevi (Fig. 6).^{43,44} Neurotised and desmoplastic naevi need to be distinguished from desmoplastic melanoma. This may be difficult especially on the first biopsy when malignant features may be less obvious in desmoplastic melanomas. Desmoplastic naevi

So-called “deep penetrating naevi” are common on the face and are often heavily pigmented clinically, an appearance that may raise concern about the possibility of malignancy. Pathologically deep penetrating naevi are usually symmetrical with a wedge shape (Fig. 7a).^{15,50} They are composed predominantly of fascicles of plump and spindle-shaped cells with variable melanisation and admixed melanophages and extend around skin adnexal structures and neurovascular bundles, often into the deep dermis or subcutis (Fig. 7b). They often have a small junctional component. As they may show occasional atypical nuclei, perineural spread and an occasional non-atypical dermal mitosis, the possibility of melanoma may be considered. However they lack frequent, deep or atypical mitotic activity, marked nuclear pleomorphism, asymmetry and an in situ component.

Epithelioid blue naevus is a distinctive form of blue naevus associated with Carney’s myxoma syndrome.⁵¹⁻⁵³ It is a dermally based lesion composed of scattered large pigmented epithelioid cells with prominent nucleoli which are often admixed with more typical spindled or dendritic blue naevus-type cells. As they often show poor maturation, include occasional dermal mitoses and are HMB45-positive, they are often reported as melanoma. Again, the absence of marked nuclear pleomorphism, frequent and abnormal mitotic activity and an in situ component should allow their distinction.

In our view, so-called “melanophagic”/equine/animal-type melanocytic tumours are probably variants of blue naevi as well. The various names that have been applied to these tumours reflect the fact that they are characterised by the presence of heavily pigmented melanocytes and that similar tumours occur around the perianal skin of “old grey” horses.⁵⁴ There is often overlying pseudo-epitheliomatous hyperplasia of the epidermis. Although some authors have suggested that such tumours in humans are malignant,⁵⁵ in our experience of over 20 cases, only a minority behave in an aggressive manner (unpublished data). Furthermore, we believe that the frequent presence of blue naevus-like areas (including sclerotic dermal collagen and spindled and dendritic shaped blue naevus-type cells) and HMB45 positivity are all features supporting our interpretation that these tumours are variants of blue naevi. It may be appropriate to apply standard pathological criteria to determine their malignant potential rather than to classify every tumour as a melanoma.

Recently, Zembowicz and colleagues⁵⁶ reported their experience of heavily pigmented melanocytic lesions including so-called animal-type melanomas and epithelioid blue naevi. They found that there were overlapping morphologic features between the 2 tumours and that they were indistinguishable histologically. Regional lymph node

sampling in 24 patients [including sentinel lymph node (SNL) biopsies performed in 23 patients] revealed metastatic tumour in 11 (46%) patients. They concluded that it was not possible to predict the tumour’s biologic behaviour from its morphologic features. Therefore, they proposed the term “pigmented epithelioid melanocytoma” (PEM) as a provisional diagnostic entity to encompass both animal-type melanoma and epithelioid blue nevus. On the basis of their results, Zembowicz et al suggested that PEM is a unique low-grade variant of melanoma with frequent lymph node metastases but an indolent clinical course. In our view, because some melanomas may not manifest clinical evidence of metastatic disease until 30 years after excision of the primary tumour, long follow-up is required of large series of patients to determine whether these tumours are “metastasizing or recurring melanocytic tumours with a favourable clinical outcome” as Zembowicz et al suggest,⁵⁶ or simply an uncommon variant of melanoma.

Other Diagnostic Problems

Hutchinson’s Melanotic Freckle (Lentigo Maligna)

Hutchinson’s Melanotic Freckle (HMF), also termed lentigo maligna, commonly occurs on the face of elderly patients and may cause difficulties in diagnosis particularly in small biopsy specimens. HMF is characterised pathologically by the presence of hyperchromatic, often angulated melanocytes initially confined to the basal epidermal layer in a discontinuous fashion, involving sun damaged skin showing epidermal atrophy, loss of rete ridges and dermal solar elastosis (Fig. 8a). The cells extend along eccrine ducts and the outer sheaths of hair follicles (Fig. 8b). As the lesions progress, the single cells become continuous and occasional nests form. In later lesions, the cells may show a more epithelioid cyto-morphology and pagetoid epidermal invasion. In some cases, features resembling or overlapping with a lentiginous junctional dysplastic naevus are seen. The distinction is made by identifying interspersed more typical areas of a HMF and the presence of more diffuse cytological atypia. Another common and difficult problem, particularly in small biopsies, is determining whether a mild to moderate increase in mildly atypical junctional melanocytes represents the effects of chronic sun damage such as a solar lentigo or an early HMF. The presence of enlarged melanocytes (greater than the size of adjacent keratinocytes), a continuous/lentiginous growth pattern and upward migration of melanocytes within the epidermis are features favouring a HMF.

Melanomas Prone to be Missed on Presentation

Desmoplastic Melanoma

Desmoplastic melanoma (DM) is not infrequently

misdiagnosed clinically and histologically especially when not obviously associated with a HMF.⁴⁶ It most commonly involves the scalp or face and Caucasians are most frequently affected. The presenting papule or nodule is usually non-pigmented and clinically may resemble a basal cell carcinoma. Associated junctional change is present in about 70% of cases where it may be minimal or extensive. However, occasionally it is absent.⁴⁵ The dermal spindling melanocytes resemble fibroblasts histologically and ultrastructurally. Diagnostic clues include very elongated nuclei which may be hyperchromatic, dermal mitoses, scattered foci of lymphocytes and neurotropism (Fig. 9a).^{45,57} The latter may be perineural, intraneural or “neural transforming” (Fig. 9b).⁵⁸

The differential diagnosis includes variants of blue naevus (however unlike DM, they are HMB45-positive), dermatofibroma/fibrous histiocytoma (they may include numerous S100-positive and CD1a-positive interdigitating cells which should not prompt a diagnosis of DM) and desmoplastic Spitz naevus.

Naevoid Melanoma

Naevoid melanoma is easily misdiagnosed and often a cause of medico-legal action. At low power, the histological pattern resembles a benign naevus, including Spitz naevus. Some, including atypical Spitz naevi, have been diagnosed as “minimal deviation melanoma”. Clues to the diagnosis include an infiltrative deep margin, expansile dermal nodules, poor maturation, cell crowding, a mixture of cell sizes, nucleoli (particularly in the deeper dermal cells), elongated long thin rete ridges and at least occasional dermal mitotic figures (including deep and abnormal forms) (Fig. 10).⁵⁹⁻⁶¹ Some naevoid melanomas are HMB45-negative but most have a few HMB45-positive dermal cells. Proliferation markers (e.g. Ki67) may be increased (most show more than 2% of nuclei are positive).⁶² Kamino bodies are rare and usually solitary. There is probably a histological continuum between Spitz naevus and Spitzoid melanomas and hence classification into benign or malignant for some atypical tumours may be very difficult or impossible.²

Regressed Melanoma

Areas of completely regressed melanoma can closely resemble regressed pigmented basal cell carcinomas (BCC). There is loss of rete ridges and the papillary dermis is widened with angiofibroplasia (Fig. 11) and variable numbers of pigmented melanophages and lymphocytes. A band of heavily pigmented melanophages favours regressed melanoma over regressed BCC or other tumours. However, in the absence of identification of the original tumour, it is not possible to definitively determine the nature of totally

regressed lesions in which no tumour is present. Extra levels may reveal some residual atypical junctional dermal melanocytes in cases of regressing melanoma.

Malignant Blue Naevus

So-called malignant blue naevus are very rare tumours that usually arise on the scalp.⁶³⁻⁶⁵ In most cases, there is an obvious spindle and/or epithelioid melanoma associated with a blue naevus of dendritic or cellular type. The presence of marked nuclear atypia and hypercellularity, frequent and abnormal mitoses and sometimes necrosis are the features that establish the correct diagnosis.⁶⁶

Metastatic Melanoma

Metastatic malignant melanoma may be myxoid, blue naevus-like or contain balloon cells. Mitoses and nuclear pleomorphism are often present and may provide clues to the diagnosis.

Important pathological features that favour a diagnosis of melanoma are listed in Table 4.

Conclusions

The pathological diagnosis of melanocytic lesions can be difficult. As well as clinical data, accurate diagnosis requires the assessment of a range of architectural and cytological features and features of the host response. For this reason, histopathological diagnosis usually requires assessment of a complete excision specimen. Knowledge of the pathological features of benign and malignant melanocytic lesions, awareness of potential diagnostic pitfalls and the application of standard criteria should enable the correct diagnosis to be established in most cases.

REFERENCES

1. Troxel DB. Pitfalls in the diagnosis of malignant melanoma: findings of a risk management panel study. *Am J Surg Pathol* 2003;27:1278-83.
2. Crotty KA, Scolyer RA, Li L, Palmer AA, Wang L, McCarthy SW. Spitz naevus versus Spitzoid melanoma: when and how can they be distinguished? *Pathology* 2002;34:6-12.
3. Scolyer RA, Crotty KA, Palmer AA, McCarthy SW. Pagetoid spread of melanocytes in Spitz naevi. *Pathology* 2002;34:591. (reply to letter)
4. Kornberg R, Ackerman AB. Pseudomelanoma: recurrent melanocytic nevus following partial surgical removal. *Arch Dermatol* 1975;111:1588-90.
5. Suster S. Pseudomelanoma. A pathologist's perspective. *Int J Dermatol* 1986;25:506-7.
6. Dymock RB, Menz J. Recurrent melanocytic naevi following partial removal (pseudomelanoma). *Australas J Dermatol* 1986;27:67-9.
7. Harvell JD, Bastian BC, LeBoit PE. Persistent (recurrent) Spitz nevi: a histopathologic, immunohistochemical, and molecular pathologic study of 22 cases. *Am J Surg Pathol* 2002;26:654-61.
8. Botella-Estrada R, Sanmartin O, Sevilla A, Escudero A, Guillen C. Melanotic pigmentation in excision scars of melanocytic and non-melanocytic skin tumors. *J Cutan Pathol* 1999;26:137-44.

9. Elenitsas R, Halpern AC. Eczematous halo reaction in atypical nevi. *J Am Acad Dermatol* 1996;34:357-61.
10. Lowes MA, Norris D, Whitfield M. Benign melanocytic proliferative nodule within a congenital naevus. *Australas J Dermatol* 2000;41:109-11.
11. Hendrickson MR, Ross JC. Neoplasms arising in congenital giant nevi: morphologic study of seven cases and a review of the literature. *Am J Surg Pathol* 1981;5:109-35.
12. Bastian BC, Xiong J, Frieden IJ, Williams ML, Chou P, Busam K, et al. Genetic changes in neoplasms arising in congenital melanocytic nevi: differences between nodular proliferations and melanomas. *Am J Pathol* 2002;161:1163-9.
13. Bastian BC. Understanding the progression of melanocytic neoplasia using genomic analysis: from fields to cancer. *Oncogene* 2003;22:3081-6.
14. Pulitzer DR, Martin PC, Cohen AP, Reed RJ. Histologic classification of the combined nevus. Analysis of the variable expression of melanocytic nevi. *Am J Surg Pathol* 1991;15:1111-22.
15. Seab JA Jr, Graham JH, Helwig EB. Deep penetrating nevus. *Am J Surg Pathol* 1989;13:39-44.
16. Kerl H, Soyer HP, Cerroni L, Wolf IH, Ackerman AB. Ancient melanocytic nevus. *Semin Diagn Pathol* 1998;15:210-5.
17. Mooi WJ. Histopathology of Spitz naevi and "Spitzoid" melanomas. *Curr Top Pathol* 2001;94:65-77.
18. Weedon D, Little JH. Spindle and epithelioid cell nevi in children and adults. A review of 211 cases of the Spitz nevus. *Cancer* 1977;40:217-25.
19. Paniago-Pereira C, Maize JC, Ackerman AB. Nevus of large spindle and/or epithelioid cells (Spitz's nevus). *Arch Dermatol* 1978;114:1811-23.
20. Busam KJ, Barnhill RL. Pagetoid Spitz nevus. Intraepidermal Spitz tumor with prominent pagetoid spread. *Am J Surg Pathol* 1995;19:1061-7.
21. Han MH, Koh KJ, Choi JH, Sung KJ, Moon KC, Koh JK. Pagetoid Spitz nevus: a variant of Spitz nevus. *Int J Dermatol* 2000;39:555-7.
22. Barnhill RL, Argenyi ZB, From L, Glass LF, Maize JC, Mihm MC Jr, et al. Atypical Spitz nevi/tumors: lack of consensus for diagnosis, discrimination from melanoma, and prediction of outcome. *Hum Pathol* 1999;30:513-20.
23. Wechsler J, Bastuji-Garin S, Spatz A, Bailly C, Cribier B, Andrac-Meyer L, et al. Reliability of the histopathologic diagnosis of malignant melanoma in childhood. *Arch Dermatol* 2002;138:625-8.
24. Llewellyn K, Barnhill RL. Distinguishing Spitz tumors from malignant melanoma: potential role of comparative genomic hybridization and fluorescence in situ hybridization in diagnosis and prognosis. *Adv Anat Pathol* 2001;8:249-54.
25. Su LD, Fullen DR, Sondak VK, Johnson TM, Lowe L. Sentinel lymph node biopsy for patients with problematic spitzoid melanocytic lesions: a report on 18 patients. *Cancer* 2003;97:499-507.
26. Lohmann CM, Coit DG, Brady MS, Berwick M, Busam KJ. Sentinel lymph node biopsy in patients with diagnostically controversial spitzoid melanocytic tumors. *Am J Surg Pathol* 2002;26:47-55.
27. Sagebiel RW, Chinn EK, Egbert BM. Pigmented spindle cell nevus. Clinical and histologic review of 90 cases. *Am J Surg Pathol* 1984;8:645-53.
28. Elder DE, Goldman LI, Goldman SC, Greene MH, Clark WH Jr. Dysplastic nevus syndrome: a phenotypic association of sporadic cutaneous melanoma. *Cancer* 1980;46:1787-94.
29. Elder DE, Green MH, Guerry DT, Kraemer KH, Clark WH Jr. The dysplastic nevus syndrome: our definition. *Am J Dermatopathol* 1982;4:455-60.
30. Mooney MA, Barr RJ, Buxton MG. Halo nevus or halo phenomenon? A study of 142 cases. *J Cutan Pathol* 1995;22:342-8.
31. Yasaka N, Furue M, Tamaki K. Histopathological evaluation of halo phenomenon in Spitz nevus. *Am J Dermatopathol* 1995;17:484-6.
32. Harvell JD, Meehan SA, LeBoit PE. Spitz's nevi with halo reaction: a histopathologic study of 17 cases. *J Cutan Pathol* 1997;24:611-9.
33. Grin CM, Rojas AI, Grant-Kels JM. Does pregnancy alter melanocytic nevi? *J Cutan Pathol* 2001;28:389-92.
34. Foucar E, Bentley TJ, Laube DW, Rosai J. A histopathologic evaluation of nevocellular nevi in pregnancy. *Arch Dermatol* 1985;121:350-4.
35. Ellis DL, Wheeland RG. Increased nevus estrogen and progesterone ligand binding related to oral contraceptives or pregnancy. *J Am Acad Dermatol* 1986;14:25-31.
36. Lee HJ, Ha SJ, Lee SJ, Kim JW. Melanocytic nevus with pregnancy-related changes in size accompanied by apoptosis of nevus cells: a case report. *J Am Acad Dermatol* 2000;42:936-8.
37. Schrader WA, Helwig EB. Balloon cell nevi. *Cancer* 1967;20:1502-14.
38. Hashimoto K, Bale GF. An electron microscopic study of balloon cell nevus. *Cancer* 1972;30:530-40.
39. Smoller BR, Kindel S, McNutt NS, Gray MH, Hsu A. Balloon cell transformation in multiple dysplastic nevi. *J Am Acad Dermatol* 1991;24:290-2.
40. Kao GF, Helwig EB, Graham JH. Balloon cell malignant melanoma of the skin. A clinicopathologic study of 34 cases with histochemical, immunohistochemical, and ultrastructural observations. *Cancer* 1992;69:2942-52.
41. Gray MH, Smoller BR, McNutt NS, Hsu A. Neurofibromas and neurotized melanocytic nevi are immunohistochemically distinct neoplasms. *Am J Dermatopathol* 1990;12:234-41.
42. Misago N. The relationship between melanocytes and peripheral nerve sheath cells (Part I): melanocytic nevus (excluding so-called "blue nevus") with peripheral nerve sheath differentiation. *Am J Dermatopathol* 2000;22:217-29.
43. Mackie RM, Doherty VR. The desmoplastic melanocytic naevus: a distinct histological entity. *Histopathology* 1992;20:207-11.
44. Harris GR, Shea CR, Horenstein MG, Reed JA, Burchette JL Jr, Prieto VG. Desmoplastic (sclerotic) nevus: an underrecognized entity that resembles dermatofibroma and desmoplastic melanoma. *Am J Surg Pathol* 1999;23:786-94.
45. Jain S, Allen PW. Desmoplastic malignant melanoma and its variants. A study of 45 cases. *Am J Surg Pathol* 1989;13:358-73.
46. Quinn MJ, Crotty KA, Thompson JF, Coates AS, O'Brien CJ, McCarthy WH. Desmoplastic and desmoplastic neurotropic melanoma: experience with 280 patients. *Cancer* 1998;83:1128-35.
47. Gonzalez-Campora R, Galera-Davidson H, Vazquez-Ramirez FJ, Diaz-Cano S. Blue nevus: classical types and new related entities. A differential diagnostic review. *Pathol Res Pract* 1994;190:627-35.
48. Carr S, See J, Wilkinson B, Kossard S. Hypopigmented common blue nevus. *J Cutan Pathol* 1997;24:494-8.
49. Busam KJ. Metastatic melanoma to the skin simulating blue nevus. *Am J Surg Pathol* 1999;23:276-82.
50. Mehregan DA, Mehregan AH. Deep penetrating nevus. *Arch Dermatol* 1993;129:328-31.
51. Carney JA, Ferreiro JA. The epithelioid blue nevus. A multicentric familial tumor with important associations, including cardiac myxoma and psammomatous melanotic schwannoma. *Am J Surg Pathol* 1996;20:259-72.
52. O'Grady TC, Barr RJ, Billman G, Cunningham BB. Epithelioid blue nevus occurring in children with no evidence of Carney complex. *Am J Dermatopathol* 1999;21:483-6.
53. Groben PA, Harvell JD, White WL. Epithelioid blue nevus: neoplasm Sui generis or variation on a theme? *Am J Dermatopathol* 2000;22:473-88.
54. Seltenhammer MH, Simhofer H, Scherzer S, Zechner R, Curik I, Solkner J, et al. Equine melanoma in a population of 296 grey Lipizzaner horses. *Equine Vet J* 2003;35:153-7.
55. Crowson AN, Magro CM, Mihm MC Jr. Malignant melanoma with prominent pigment synthesis: "animal type" melanoma – a clinical and histological study of six cases with a consideration of other melanocytic neoplasms with prominent pigment synthesis. *Hum Pathol* 1999;30:543-50.

56. Zembowicz A, Carney JA, Mihm MC. Pigmented epithelioid melanocytoma: a low-grade melanocytic tumor with metastatic potential indistinguishable from animal-type melanoma and epithelioid blue nevus. *Am J Surg Pathol* 2004;28:31-40.
 57. Longacre TA, Egbert BM, Rouse RV. Desmoplastic and spindle-cell malignant melanoma. An immunohistochemical study. *Am J Surg Pathol* 1996;20:1489-500.
 58. Smithers BM, McLeod GR, Little JH. Desmoplastic, neural transforming and neurotropic melanoma: a review of 45 cases. *Aust N Z J Surg* 1990;60:967-72.
 59. McNutt NS, Urmacher C, Hakimian J, Hoss DM, Lugo J. Nevoid malignant melanoma: morphologic patterns and immunohistochemical reactivity. *J Cutan Pathol* 1995;22:502-17.
 60. Zembowicz A, McCusker M, Chiarelli C, Dei Tos AP, Granter SR, Calonje E, et al. Morphological analysis of nevoid melanoma: a study of 20 cases with a review of the literature. *Am J Dermatopathol* 2001;23:167-75.
 61. Kossard S, Wilkinson B. Nucleolar organizer regions and image analysis nuclear morphometry of small cell (nevoid) melanoma. *J Cutan Pathol* 1995;22:132-6.
 62. Li LX, Crotty KA, McCarthy SW, Palmer AA, Kril JJ. A zonal comparison of MIB1-Ki67 immunoreactivity in benign and malignant melanocytic lesions. *Am J Dermatopathol* 2000;22:489-95.
 63. Aloï F, Pich A, Pippione M. Malignant cellular blue nevus: a clinicopathological study of 6 cases. *Dermatology* 1996;192:36-40.
 64. Mehregan DA, Gibson LE, Mehregan AH. Malignant blue nevus: a report of eight cases. *J Dermatol Sci* 1992;4:185-92.
 65. Temple-Camp CR, Saxe N, King H. Benign and malignant cellular blue nevus. A clinicopathological study of 30 cases. *Am J Dermatopathol* 1988;10:289-96.
 66. Granter SR, McKee PH, Calonje E, Mihm MC, Jr., Busam K. Melanoma associated with blue nevus and melanoma mimicking cellular blue nevus: a clinicopathologic study of 10 cases on the spectrum of so-called 'malignant blue nevus'. *Am J Surg Pathol* 2001;25:316-23.
-