

## Young Breast Cancer in a Specialised Breast Unit in Singapore: Clinical, Radiological and Pathological Factors

Sze Yiun Teo,<sup>1</sup> MBBS, FRCR, Esther Chuwa,<sup>2</sup> MBBS, FRCS, Suvarna Latha,<sup>1</sup> MBBS, FRCR, Yi Ling Lew,<sup>2</sup> MBBS, Yah Yuen Tan,<sup>3</sup> MBBS, FRCS

### Abstract

**Introduction:** Whilst only 5.5% to 7% of breast cancer occurs in women less than 40 years of age in the West, the incidence has been reported in up to 18% in Asian population. This study seeks to evaluate our unit's experience in breast cancer in young women. **Materials and Methods:** A retrospective review of our database identified women with newly diagnosed breast cancer from January 2006 to February 2011. Patient demographics, clinical presentation, imaging and pathological findings and treatment received were determined. **Results:** Out of a total of 1160 women with breast cancer, 135 (11.6%) were under 40 years of age and made up our study population. The most common presentation was a self-detected breast lump. Most patients did not have a positive family history. Mammography demonstrated abnormal findings in 78% of patients. Ultrasound was very sensitive in the evaluation of a breast lump and demonstrated abnormal findings in 95%. Out of 129 women, 40 (31%) underwent breast-conserving surgery of which 5 (12.5%) proceeded to mastectomy due to involved margins. Also, 89 out of 129 women (69%) underwent mastectomy of which 19 (21.3%) had immediate reconstruction. Of a total of 121 primary resections, 94% were invasive ductal carcinoma while 15.5% were pure ductal in-situ carcinomas. The majority (61.2%) showed high grade disease. **Conclusion:** Most young breast cancer patients present with a self-detected breast lump and do not have a positive family history. A strong clinical index of suspicion and appropriate breast imaging workup are useful for the early and accurate diagnosis of breast cancer in young women.

Ann Acad Med Singapore 2014;43:79-85

**Key words:** Breast carcinoma, Breast imaging, Family history, Symptoms, Young age

### Introduction

Breast cancer is the most common cancer to afflict women in Singapore, accounting for almost 30% of all female cancers. The greatest incidence occurred in women aged between 45 and 49 years but has more recently showed a shift towards older women in their late 50's.<sup>1</sup> There was also a worrying upward trend in the number of breast cancer cases with a 25% higher incidence in the period from 1998 to 2002 compared to 1993 to 1997.<sup>2</sup>

There are few studies examining breast cancer in women under 40 years of age. While it has been reported that only 5.5% to 7% of breast cancers are detected in women younger than 40 years in the West,<sup>3,4</sup> this group has been reported to account for 12% to 18% of breast cancers in Asian population with an increasing trend observed over the years.<sup>5-7</sup>

The purpose of this study is to evaluate our unit's experience in breast cancer occurring in young women under 40 years of age in a predominantly Chinese population in Singapore. The span of the study includes clinical, radiological, surgical and pathological factors.

### Materials and Methods

Young breast cancer is defined as breast cancer occurring in women younger than 40 years of age at diagnosis. A retrospective, institutional review board-approved review of our centre's surgical database identified a total of 1160 women diagnosed with breast cancer from January 2006 to February 2011. Breast cancer diagnosis was made by either core needle or excisional biopsy of a breast lesion. Of these,

<sup>1</sup>Department of Diagnostic and Interventional Imaging, KK Women's and Children's Hospital, Singapore

<sup>2</sup>Gleneagles Hospital, Singapore

<sup>3</sup>Mount Elizabeth Medical Centre, Singapore

Address for Correspondence: Dr Sze Yiun Teo, Department of Diagnostic and Interventional Radiology, KK Women's and Children's Hospital, 100 Bukit Timah Road, Singapore 229899.

Email: Teo.Sze.Yiun@kkh.com.sg

135 women were under the age of 40 at the time of diagnosis, comprising 11.6% of all patients with breast cancer. Data including clinical findings, imaging studies and findings, and histo-pathological findings were recorded. Imaging findings were retrospectively reviewed by 2 radiologists and classified according to the Breast Imaging Reporting and Data System (BI-RADS) developed by the American College of Radiology.<sup>8</sup>

## Results

### Clinical Findings (Table 1)

The median patient age at breast cancer diagnosis was 36 years with an age range from 18 to 39 years. Family history was unknown in one patient as she was adopted. For the rest of the patients, a family history of breast cancer was positive in 19 out of 134 (14.1%) of patients. The most common clinical presentation was a self-detected symptomatic breast lump (n = 109; 80.7%). Other patients presented with a self-detected breast lump together with

another breast symptom (nipple discharge, pain, or nipple change; n = 15; 11.3%). A few patients presented with nipple discharge only (n = 5; 3.5%) and others had mastalgia (n = 2; 1.5%). Four patients were asymptomatic but had abnormalities detected on breast imaging, including 1 patient with a positive family history and who underwent mammographic screening before the age of 40. The other 3 patients had undergone routine breast ultrasound.

Five women had pregnancy-related breast cancer (3.5%) including 4 who were pregnant at the time of diagnosis and 1 who was lactating. Most of the women were Chinese (n = 91; 67.4%), 27 were Malay (20%), 3 were Indian (2.2%), 1 was Caucasian (0.7%) and 13 were of other races (9.6%).

### Imaging Findings (Table 2)

Amongst the 135 women, 7 had no preoperative breast imaging, including 2 with advanced disease at presentation and 5 with incidental malignancy detected after excision of a breast lump. Twelve had preoperative breast imaging studies performed at another institution which were not available for review. The preoperative breast imaging studies for the remaining 116 women were reviewed.

Table 1. Clinical Findings

Clinical factors	Study population	
	Number (n)	Percentage (%)
Age (years)		
Mean	34 (6.6)	
Median (range)	36 (18 to 39)	
Symptom duration (weeks)		
Mean (SD)	13 (36.4)	
Median (range)	4 (<1 to 384)	
Symptoms		
Breast lump only	109	80.7
Breast lump and other breast symptom	15	11.3
Nipple discharge only	5	3.5
Breast pain only	2	1.5
Asymptomatic with incidental imaging findings	4	3.0
Pregnancy-associated cancer		
No	130	96.3
Yes	5	3.7
Ethnicity		
Chinese	91	67.4
Malay	27	20.0
Indian	3	2.2
Others	14	10.4
Family history		
No	115	85.2
Yes	19	14.1
Unknown	1	0.7

Table 2. Imaging Findings

Imaging findings	Study population	
	Number (n)	Percentage (%)
Mammography		
n = 100		
Mammographic density		
Extremely dense	68	68.0
Heterogeneously dense	15	15.0
Scattered fibroglandular densities	14	14.0
Mainly fat replaced	3	3.0
Mammographic findings		
Normal/Benign	22	22.0
Abnormal (total)	78	78.0
Opacity	40	40.0
Microcalcifications only	19	19.0
Opacity and microcalcifications	10	10.0
Others	9	9.0
Ultrasound		
n = 115		
Ultrasound findings		
Normal/Benign	6	5.2
Abnormal	109	94.8
MRI		
n = 14		
MRI findings		
Mass	13	92.9
Non-mass enhancement	1	7.1
Additional abnormal findings not seen on mammogram and ultrasound	9	64.3

**Mammography**

Mammography was performed for 101 of the 116 women. Fourteen patients only had a preoperative ultrasound, and mammogram could not be performed for one patient as the affected breast was too hard to compress. The mammogram films for one of the 101 patients could not be retrieved as they had been culled. The mammogram examinations for 100 patients were thus reviewed. Most patients had dense breasts on mammogram (n = 83; 83%), including 68 women (68%) with extremely dense and 15 women (15%) with heterogeneously dense parenchymal patterns respectively. Fourteen (14%) women showed scattered fibroglandular densities and 3 (3%) were fat replaced.

Mammogram was either normal or benign in 22 patients (22%), with the cancer appearing mammographically occult with no other findings in 16 patients (BIRADS 1; 16%) and mammographically occult with other benign findings in 6 patients (BIRADS 2; 6%).

Suspicious mammographic findings (BIRADS 4/5) were present in 78 patients (78%)

The most common suspicious mammographic abnormality

was an abnormal opacity, seen in 40 patients (Fig. 1). Nineteen patients had abnormal microcalcifications as a solitary finding and 10 patients had an opacity associated with microcalcifications. The other findings included asymmetric density only (n = 4), asymmetric density with microcalcifications (n = 3) and microcalcifications with distortion (n = 1). Stromal distortion alone was present in 1 patient.

**Ultrasound**

Preoperative breast ultrasound examination was performed in almost all women (n = 115; 99.1%), except for 1 patient who had advanced disease at presentation.

The majority of patients (n = 109; 94.5 %) demonstrated suspicious sonographic findings (BIRADS 4/5), with the size of the masses ranging from 0.4 to 11.2 cm (mean = 2.6 cm; median = 2.0 cm). In 94 patients with an accompanying mammogram, the latter was normal or benign in 18. Most of these 18 patients had extremely dense breast parenchyma (n = 17; Fig. 2) and one was heterogeneously dense.

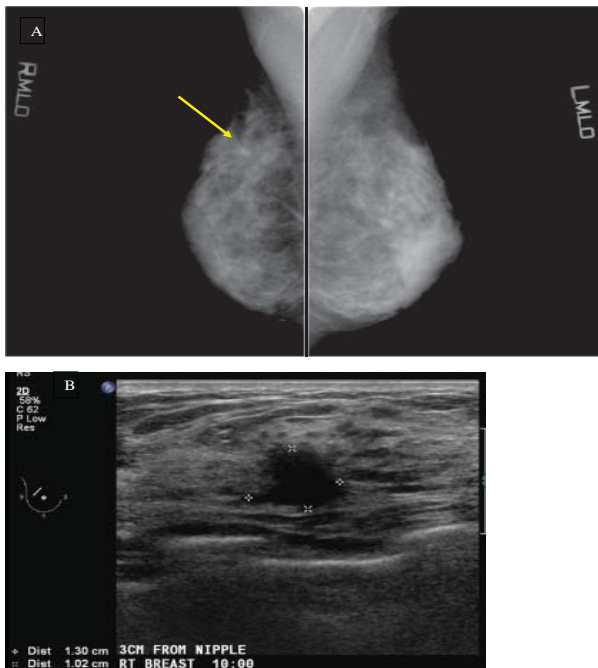


Fig. 1. A 34-year-old Malay lady with no family history who presented with right mastalgia. (A) Mammogram shows extremely dense parenchymal tissues and a spiculated opacity in the right upper breast (arrow). The left breast was normal. (B) Breast ultrasound shows an irregular hypoechoic nodule corresponding to the mammographic finding. Histology revealed invasive ductal carcinoma.

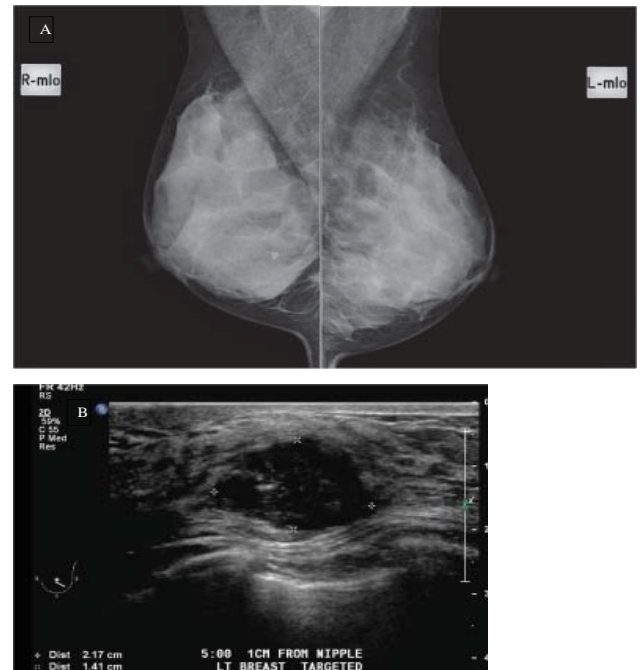


Fig. 2. A 38-year-old Chinese lady with no family history who presented with left sided breast lump. (A) Mammogram shows extremely dense parenchymal tissues with no abnormal finding. (B) Breast ultrasound shows a 2.2cm mass with slightly irregular margins and heterogeneous echotexture. Histology revealed invasive ductal carcinoma.

Ultrasound was normal in 2 patients. The first patient presented with a breast lump and mammogram showed an abnormal cluster of microcalcifications assigned a BIRADS 4 classification. She underwent stereotactic guided biopsy of the abnormal microcalcifications which yielded atypical cells. This was subsequently upgraded to DCIS after wide excision of the affected area (Fig. 3). The second patient presented with blood-stained nipple discharge. The accompanying mammogram was also normal; ductal carcinoma in-situ and mucinous carcinoma were found on micro-dochectomy.

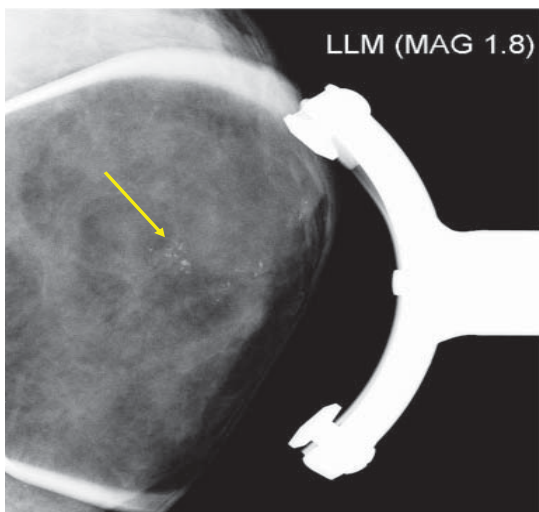


Fig. 3. A 35-year-old Chinese lady with no family history who presented with left breast lump. Magnification mammogram shows abnormal microcalcifications in a segmental distribution (arrow). Breast ultrasound was negative. Stereotactic mammographic guided biopsy of the microcalcifications revealed hyperplasia with moderate atypia. This was upgraded to ductal carcinoma-in-situ on wide excision.

Benign findings (BIRADS 2/3) were present in 4 patients. Of these, one patient did not have a mammogram and the other 3 had benign mammographic findings. The patient who only had an ultrasound had a 3.9 cm benign appearing solid mass. This was excised due to its size and a small incidental focus of DCIS was found involving a large fibroadenoma on pathology. Two other patients with mammogram and ultrasound had benign appearing solid nodules and cysts in both breasts. In one patient, open biopsy of an area of induration felt clinically revealed invasive lobular carcinoma. In the other patient, vacuum assisted percutaneous biopsy of an area of mastalgia showed ductal carcinoma in-situ (DCIS). The third patient presented with blood-stained nipple discharge. Ultrasound showed a dilated duct in the retro-areolar region and there were benign-appearing calcification on mammogram. DCIS was found on subsequent micro-dochectomy.

### Magnetic Resonance Imaging (MRI)

Preoperative breast MRI was performed for 14 patients. Interpretation of the breast MRI study was accomplished using the ACR breast MRI reporting lexicon.<sup>8</sup> Abnormal mass lesions were present in 13 patients and abnormal non-mass enhancement was present in 1 patient. MRI showed additional suspicious findings in 9 patients (64.3%) that were not detected on mammogram or US (Fig. 4). In 1 patient with lobular carcinoma, the tumour was seen only on MRI, being occult on both mammography and ultrasound. The rest of the 4 patients had no additional findings on MRI.

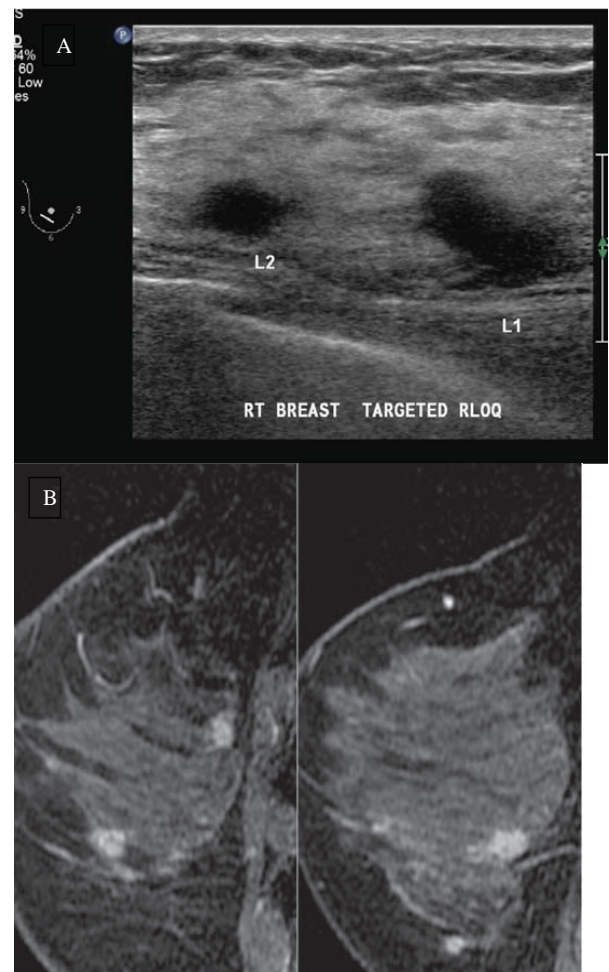


Fig. 4. A 35-year-old Malay lady with no family history who presented with a right breast lump. Mammogram showed extremely dense parenchymal tissues with no abnormal finding. (A) Breast ultrasound showed 2 hypoechoic nodules with ill-defined margins in the right lower outer quadrant. Biopsy of both nodules showed invasive ductal carcinoma. (B) Breast MRI showed multiple other suspicious enhancing nodules in the rest of the right breast. These were due to areas of solid and comedo DCIS on histology of the mastectomy specimen.

### Surgical Management

Four (3%) women had metastatic disease at presentation and 2 (1.5%) defaulted treatment and follow-up after biopsy. These 6 women were excluded from further analysis; the remaining 129 patients underwent surgical treatment in our institution.

Forty out of 129 women (31%) underwent breast-conserving surgery (BCS) of which 5 (12.5%) proceeded to mastectomy due to involved margins. Eighty-nine out of 129 women (69%) underwent mastectomy of which 19 (21.3%) had immediate reconstruction.

Table 3. Histopathological Findings

Histopathological findings	Study population	
	Number	(%)
Primary surgical treatment	Total = 129	
Breast conservation	40	31
Mastectomy	70	54.3
Mastectomy with reconstruction	19	14.7
Tumour size (cm)		
Mean (SD)	2.8 (2.1)	
Median (range)	2.2 (1 to 10.0)	
Overall tumour size		
2.0 cm or less	67	51.9
More than 2.0 cm	62	48.1
Tumour histology type		
Pure DCIS	20	15.5
Invasive ductal carcinoma	94	72.9
Invasive lobular carcinoma	3	2.3
Invasive mucinous carcinoma	10	7.7
Metaplastic carcinoma	2	1.6
Histologic Grade		
Low	19	14.8
Intermediate	31	24.0
High	79	61.2
Nodal involvement (invasive cancers with operative histology n = 110)		
No	60	54.5
Yes	50	45.5
TNM Stage (n = 133 excluding loss to follow up)		
0	19	14.3
I	35	26.3
II	53	39.8
III	22	16.5
IV	4	3.0
Hormone receptor status (n = 133)		
ER negative	41	30.8
ER positive	92	69.2
CerbB2 overexpression (invasive cancers only, n = 118)		
No	83	70.3
Yes	35	29.7

### Histo-pathological Findings (Table 3)

The median tumour size was 2.2 cm (range, 0.1 to 10.0 cm). Of them, 6.2% (8/129) received neo-adjuvant chemotherapy. Of a total of 121 primary resections, 94% were invasive ductal carcinoma with or without associated DCIS while 15.5% were pure DCIS. There were 2 cases of metaplastic adeno-squamous cancer. The majority (61.2%) showed high grade disease. A total of 45.5% of them had nodal involvement. Among these, 69.2%, 54.9% and 29.7% were oestrogen receptor (ER), progesterone receptor (PR) and human epidermal growth factor receptor-2 (HER-2) positive respectively. Adjuvant chemotherapy was administered in 48.1% (62/129) of surgically treated patients with invasive disease.

### Discussion

In Singapore, women 40 years of age and above are invited to undergo breast cancer screening under the BreastScreen Singapore programme. This programme has been shown to be effective in increasing breast cancer detection at an earlier stage and with more favourable tumour characteristics.<sup>9-11</sup> Younger women below the age of 40 do not qualify for and thus do not benefit from mammographic screening. As such, the vast majority of young breast cancer patients present with a breast symptom, most commonly a self-detected breast lump, as was seen in more than 90% of our patients, including 81% of them presenting with a breast lump alone, and 11% of them presenting with a breast lump and another accompanying breast symptom. This mirrors the findings of other studies.<sup>12-14</sup>

Unexpectedly, our study showed that a majority of these young women (86%) do not have a positive family history of breast cancer. This is contrary to the increased risk of breast cancer found in women above 40 years of age with a positive family history reported in a Singaporean population study.<sup>15</sup> Only one patient in our study cohort had her breast cancer detected by early mammographic screening due to a positive family history. Our study also showed that a significant proportion of women were of the Malay race (20%). This high percentage is disproportionate to the percentage of resident Malays in Singapore (13.4%)<sup>16</sup> and also contrary to a report in which Malays were found to have a low risk of cancer.<sup>17</sup>

A small proportion of women (3.5%) had pregnancy-related breast cancer (Fig. 5). Some women were pregnant at the time of diagnosis and others were lactating. These women generally presented with advanced disease possibly as a result of their symptoms being masked by pregnancy-related changes in the breasts. Due to the young age of these patients, the treatment of these patients can be complicated by additional fertility and psychosocial issues, requiring multi-disciplinary care and support.

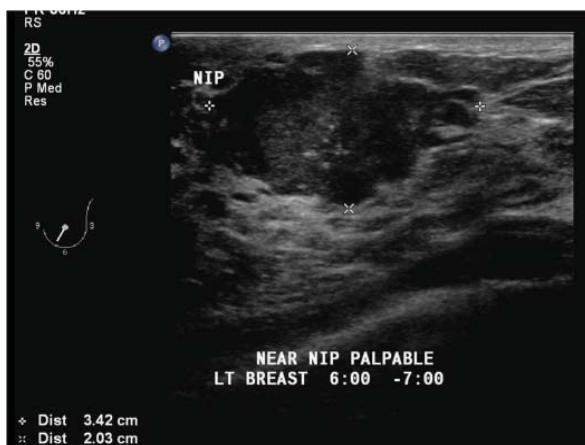

Fig. 5. A 36-year-old Chinese lady with no family history who presented with a left breast lump in pregnancy. Breast ultrasound showed an irregular hypoechoic mass with echogenic foci within which may represent foci of microcalcification. No mammogram was done as she was pregnant. Histology revealed invasive ductal carcinoma.

Mammography was able to detect suspicious findings in slightly more than three quarters of patients, with an opacity being the most common abnormality. Mammography was however normal or benign in almost a quarter of patients. The relative insensitivity of mammography may be partly attributed to the presence of dense breast parenchyma, seen in more than 80% of patients in our study. This is not surprising, as increased breast density and young age are major factors associated with decreased mammographic sensitivity.<sup>18-20</sup> When mammogram was normal or benign, breast ultrasound found a suspicious finding in 86.4% (19 out of 22 patients).

When a breast lump is present, ultrasound is a very useful tool in its evaluation, with a sensitivity of around 95%. In almost 20% of patients, the accompanying mammogram was normal or benign. Again, this could be due to obscuration of an underlying mass by dense tissues on mammogram. Conversely, the mammogram may occasionally detect an abnormal finding in the presence of a normal ultrasound, as seen in one patient with abnormal calcification as a solitary imaging finding.

In the small number of cancers with normal or benign ultrasound findings ( $n = 6$ ), one-third presented with bloody nipple discharge. Both patients also had mammogram with no abnormal findings. A third patient had abnormal mammographic findings which prompted a biopsy. Two other patients had normal or benign mammographic findings as well but clinical suspicion of a symptomatic area within the breast lead to the eventual diagnosis. One was due to an invasive lobular carcinoma; the other was found to have DCIS involving areas of fibrocystic change. The last patient had an incidental focus of DCIS involving

a large fibroadenoma.

Breast MRI has been shown to detect additional foci of occult cancer other than the index tumour in patients with a known breast malignancy, and is especially useful in the assessment of invasive lobular carcinomas.<sup>21,22</sup> This was also seen in our study, where MRI detected additional suspicious findings in about 60% of patients. However, as only a small number of patients underwent preoperative breast MRI in our study, an in-depth evaluation and discussion on the use of breast MRI is beyond the scope of this article.

The high percentage of mastectomies in our cohort (73%) is a reflection of the relatively large size of the cancers at presentation. The median size of cancers is 2.2 cm which classifies them as stage T2 by virtue of their size alone. Moreover, nearly half had nodal involvement. Nearly 60% of women were at least stage II by TNM staging at presentation. Together with a general lack of family history in these women, these findings confirm the need for a high index of suspicion among clinicians in their management of breast lumps as well as greater breast cancer awareness among women. Histo-pathological data revealed that in excess of 90% of the cancers were invasive ductal carcinomas with a low rate of DCIS. This corresponds to the 85.5% rate of invasive ductal carcinomas reported by McAree et al<sup>13</sup> and is consistent with the fact that our cohort is a non-screened population with a majority presenting with a breast lump. The distribution of ER positive and cerbB2 over-expressed cancers are comparable to the general population.<sup>23-25</sup>

Our study was limited by its retrospective nature as well as the small number of patients in the study population in a single institution which may contribute to selection bias.

## Conclusion

Breast cancer can afflict women younger than 40 years of age. As these occur before the commencement of breast screening, most patients present with a self-detected breast lump. A majority of patients do not have a positive family history of breast cancer, and the lack of a positive family history should not decrease the level of clinical suspicion. Ultrasound is a sensitive examination for the evaluation of a breast lump and can accurately detect suspicious findings. Mammography may sometimes be negative but in a small proportion detects abnormalities in the presence of a normal ultrasound study. The detection of breast cancer in young women under 40 years of age remains challenging due to a lack of routine breast screening and the presence of dense breast tissues. A strong clinical index of suspicion and appropriate breast imaging workup are useful for the early and accurate diagnosis of breast cancer in young women.

## REFERENCES

1. Jara-Lazaro AR, Thilagaratnam S, Tan PH. Breast cancer in Singapore: some perspectives. *Breast Cancer* 2010;17:23-8.
2. Trends in cancer incidence in Singapore 1968-2002. Singapore cancer registry report no. 6.
3. Brinton LA, Sherman ME, Carreon JD, Anderson WF. Recent trends in breast cancer among younger women in the United States. *J Natl Cancer Inst* 2008;100:1643-8.
4. Muttarak M, Pojchamarnwiputh S, Chaiwun B. Breast cancer in women under 40 years: preoperative detection by mammography. *Ann Acad Med Singapore* 2003;32:433-7.
5. Bouchardy C, Fioretta G, Verkooijen HM, Vlastos G, Schaefer P, Delaloye JF et al. Recent increase of breast cancer incidence among women under the age of forty. *Br J Cancer* 2007;96:1743-6.
6. Agarwal G, Pradeep PV, Aggarwal V, Yip CH, Cheung PS. Spectrum of breast cancer in Asian women. *World J Surg* 2007;31:1031-40.
7. Kwong A, Cheung P, Chan S, Lau S. Breast cancer in Chinese women younger than 40: are they different from their older counterparts? *World J Surg* 2008;32:2254-61.
8. American College of Radiology. Breast imaging reporting and data system, breast imaging atlas. 4th ed. Reston Va: American College of Radiology, 2003.
9. Ng EH, Ng FC, Tan PH, Low SC, Chiang G, Tan KP, et al. Results of intermediate measures from a population-based, randomized trial of mammographic screening prevalence and detection of breast carcinoma among Asian women: the Singapore Breast Screening Project. *Cancer* 1998;82:1521-8.
10. Wang SC. The Singapore National Breast Screening Programme: principles and implementation. *Ann Acad Med Singapore* 2003;32:466-75.
11. Chuwa EW, Yeo AW, Koong HN, Wong CY, Yong WS, Tan PH, et al. Early detection of breast cancer through population-based mammographic screening in Asian women: a comparison study between screen-detected and symptomatic breast cancers. *Breast J* 2009;15:133-9.
12. Foxcroft LM, Evans EB, Porter AJ. The diagnosis of breast cancer in women younger than 40. *Breast* 2004;13:297-306.
13. McAree B, O'Donnell ME, Spence A, Lioe TF, McManus DT, Spence RA. Breast cancer in women under 40 years of age: a series of 57 cases from Northern Ireland. *Breast* 2010;19:97-104.
14. Samphao S, Wheeler AJ, Rafferty E, Michaelson JS, Specht MC, Gadd MA, et al. Diagnosis of breast cancer in women age 40 and younger: delays in diagnosis result from underuse of genetic testing and breast imaging. *Am J Surg* 2009;198:538-43.
15. Chay WY, Ong WS, Tan PH, Jie Leo NQ, Ho GH, Wong CS, et al. Validation of the Gail model for predicting individual breast cancer risk in a prospective nationwide study of 28,104 Singapore women. *Breast Cancer Res* 2012;14:R19.
16. Yearbook of Singapore Statistics, 2011.
17. Wang H, Seow A, Lee HP. Trends in cancer incidence among Singapore Malays: a low-risk population. *Ann Acad Med Singapore* 2004;33:57-62.
18. Kerlikowske K, Grady D, Barclay J, Sickles EA, Ernster V. Effect of age, breast density, and family history on the sensitivity of first screening mammogram. *JAMA* 1996;276:33-8.
19. Carney PA, Miglioretti DL, Yankaskas BC, Kerlikowske K, Rosenberg R, Rutter CM, et al. Individual and combined effects of age, breast density and hormone replacement therapy use on the accuracy of screening mammogram. *Ann Intern Med* 2003;138:168-75.
20. Buist DS, Porter PL, Lehman C, Taplin SH, White E. Factors contributing to mammography failure in women aged 40-49 years. *J Natl Cancer Inst* 2004;96:1432-40.
21. Liberman L. Breast MR imaging in assessing extent of disease. *Magn Reson Imaging Clin N Am* 2006;14:339-49.
22. Mann RM. The effectiveness of MR imaging in the assessment of invasive lobular carcinoma of the breast. *Mag Reson Imaging Clin N Am* 2010;18:259-76.
23. Slamon DJ, Godolphin W, Jones LA, Holt JA, Wong SG, Keith De, et al. Studies of the HER-2/neu proto-oncogene in human breast and ovarian cancer. *Science* 1989;244:707-12.
24. Diaz LK, Sneige N. Estrogen receptor analysis for breast cancer: Current issues and keys to increasing testing accuracy. *Adv Anat Pathol* 2005;12:10-9.
25. Elledge RM, Allred DC. Clinical aspects of estrogen and progesterone receptors. In: Harris JR, Lippman ME, Morrow M, et al, editors. *Diseases of the Breast*. 3rd ed. Philadelphia, PA, Lippincott Williams and Wilkins, 2004.