

Rapidly Vanishing Pulmonary Pseudotumour

Quiz

A 51-year-old male ex-smoker with a history of pulmonary tuberculosis was referred for exertional dyspnoea for 5 days. He had no fever, cough or constitutional symptoms. Physical examination revealed stony dullness to percussion over the right lower thorax posteriorly. There was no pedal oedema or elevated jugular venous pulse. Serum albumin was 31 g/L and serum creatinine was 100 mmol/L with no leukocytosis. What is the diagnosis from Figures 1 and 2?

- a) Lung malignancy
- b) Rounded atelectasis
- c) Left ventricular failure
- d) Loculated empyema of the lung
- e) Rounded pneumonia

Case of a Rapidly Vanishing Pulmonary Pseudotumour

A posteroanterior chest radiograph revealed mild cardiomegaly, with a cardiothoracic ratio of >0.5 . There

was blunting of both costophrenic angles and a small loculated pleural effusion along the lateral aspect of the right hemithorax. An adjacent 9.4 x 6.3 cm well-defined, rounded opacity (arrow) was noted at the right lower zone (Fig. 1). This opacity was noted to be lenticular in shape and located within the right oblique fissure on the lateral chest radiograph (Fig. 3). In addition, the right horizontal fissure was prominent.

Computed tomography (CT) of the chest (Fig. 2) confirmed a homogenous loculated effusion in the right oblique fissure (arrow), the so-called “pulmonary pseudotumour”.¹⁻³ Transthoracic 2-dimensional echocardiography demonstrated left ventricular hypertrophy with a systolic ejection fraction of 15%. The patient’s symptoms resolved rapidly after diuresis using oral frusemide and fluid restriction.

This is consistent with the diagnosis of left ventricular failure. A repeat chest X-ray 4 days later showed that the right lung opacity and pleural effusions had vanished (Fig. 4).

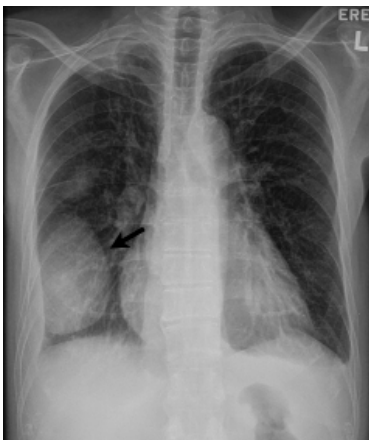

Fig. 1. Posterior-anterior chest radiograph.

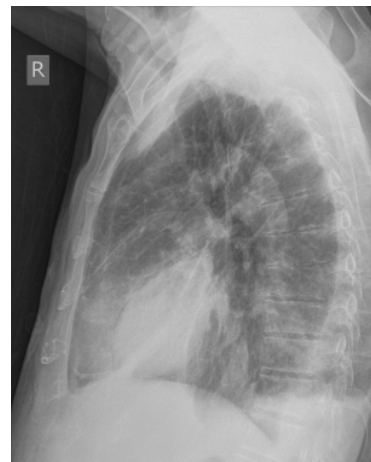

Fig. 3. Right lateral chest radiograph.

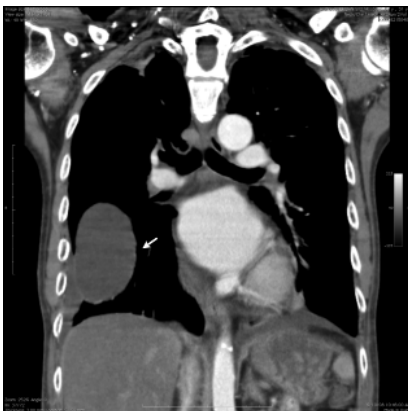

Fig. 2. Coronal reconstructed image of the CT thorax.

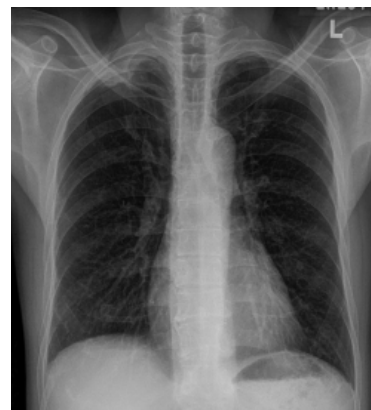


Fig. 4. Posterior-anterior chest radiograph post-therapy.

Answer: c

Discussion

The pulmonary pseudotumour is a collection of pleural fluid along the interlobar lung fissure, and can be diagnosed presumptively by its lenticular shape and typical location on chest radiograph. It is most commonly due to left ventricular failure, and can be the only sign of cardiac decompensation, as in the case described. These pseudotumours are typically transudative, and can also be contributed by hypoalbuminaemia and renal insufficiency. A preponderance of right sided pseudotumours, along the right horizontal fissure has been described,² which may be attributed to the anatomy of the pleural venous system, the right recumbent position assumed by many cardiac patients, and finally the pulmonary lymphatic drainage. Treatment of the condition involves merely managing the underlying disorder. This case underlies the importance of a lateral chest X-ray, which may avoid incorrect interpretation of this finding, causing unnecessary additional costly imaging, interventions and antibiotics.

REFERENCES

1. Haus BM, Stark P, Shofer SL, Kuschner WG. Massive pulmonary pseudotumor. *Chest* 2003;124:758-60.
2. Higgins JA, Jeurgens JL, Bruwer AJ. Loculated interlobular pleural effusion due to congestive heart failure. *Arch Intern Med* 1955;96:180-7.
3. Millard CE. Vanishing or phantom tumor of the lung; localized interlobar effusion in congestive heart failure. *Chest* 1971;59:675-7.

Augustine KH Tee,¹*MRCP*, Angeline CC Poh,²*FRCR*

¹ Division of Respiratory Medicine, Changi General Hospital, Singapore

² Department of Radiology, Changi General Hospital, Singapore

Address for Correspondence: Dr Augustine Tee, Division of Respiratory Medicine, Changi General Hospital, 2 Simei Street 3, Singapore 529889.
Email: augustine_tee@cgh.com.sg