

## Intracranial Aspergilloma in Immunocompetent Patients Successfully Treated with Radical Surgical Intervention and Antifungal Therapy – Case Series

US Srinivasan,<sup>1</sup>*MCh*

### Abstract

**Introduction:** Aspergillosis of the central nervous system is an uncommon infection, mainly occurring in immunocompromised patients with a high mortality. Surgical excision of the intracranial lesion combined with oral voriconazole has been proposed to improve the outcome in immunocompromised patients. Itraconazole has been considered not to be effective because of poor penetration into the brain tissue. We report the long-term outcome of 3 cases of intracranial aspergilloma in immunocompetent patients who were successfully treated with radical surgery combined with oral itraconazole. **Materials and Methods:** This is a retrospective study in which chronic invasive intracranial aspergilloma was successfully treated in 3 apparently immunocompetent patients and followed-up for more than 5 years. **Results:** Near complete or radical surgical removal of this localised chronic invasive intracranial aspergilloma whenever possible is the definitive treatment. When combined with the oral antifungal drug itraconazole, the management regimen is effective in achieving near complete long-term cure of more than 5 years. Oral itraconazole 200 mg twice daily should be given for a prolonged period of at least 6 months. **Conclusion:** In chronic invasive intracranial aspergilloma in an immunocompetent patient, it was suggested that radical excision of the intracranial aspergilloma combined with oral antifungal drug belonging to triazole group that can be either itraconazole or voriconazole given for a period of 6 months was likely to improve the long-term outcome.

Ann Acad Med Singapore 2008;37:783-7

**Key words:** Central nervous system aspergillosis, Aspergilloma, Itraconazole, Voriconazole

### Introduction

Aspergillosis of the central nervous system (CNS) is an uncommon infection, mainly occurring in immunocompromised patients. It may present in several forms: meningitis, mycotic aneurysms, infarcts and the tumoral form (aspergilloma).<sup>1</sup> The primary focus in most of the cases is in the lungs followed by sinuses. Fulminant invasive sinus aspergillosis affects immunocompromised patients and is usually lethal because of intracranial complications. Chronic invasive and non-invasive types occur in non-immunocompromised patients.<sup>2</sup> Siddiqui et al<sup>3</sup> had classified them into 3 types. Type 1 is patients with intracerebral aspergillosis that was associated with the worst clinical outcome. Type 2 is patients with orbital and cranial base aspergillosis who had a good recovery. Type 3 is patients with intracranial extradural aspergillosis where they had intermediate outcome. Schwartz et al<sup>4</sup> had suggested a combination of oral voriconazole with neurosurgical in-

tervention whenever feasible might improve the overall prognosis. The extent of surgical excision of the amenable intracranial lesion and the optimal treatment duration in CNS aspergillosis remains unknown.<sup>3-6</sup> Standard amphotericin B deoxycholate is associated with poor outcomes in addition to unacceptable toxicity. It is no longer recommended as primary therapy for most patients. Lipid formulations of amphotericin reduce toxicity, but because of cost and toxicity concerns, they may not be used at optimal doses. Interestingly, a recent trial showed that initial use of higher doses of liposomal amphotericin at 10 mg kg<sup>-1</sup>d<sup>-1</sup> did not improve efficacy and was associated with increased toxicity.<sup>6-9</sup> Itraconazole given alone has been considered not to be effective because of poor penetration into the brain tissue.<sup>8,10,11</sup> However, Yamanoi et al<sup>12</sup> have recently shown that high-dose itraconazole given alone to be effective in achieving a cure in 2 of their 3 cases. The literature supports the view that a combination of surgery with

<sup>1</sup> Department of Neurosurgery, MIOT Hospital, Tamil Nadu, India

Address for Correspondence: Dr U S Srinivasan, Department of Neurosurgery, MIOT Hospital, 4/112 Mount Poonamalle Road, Manapakkam, Chennai – 60089, Tamil Nadu, India.

antifungal drug is more likely to benefit patients.<sup>3-6,11,13</sup> We report 3 cases of chronic invasive intracranial aspergilloma in immunocompetent patients in retrospect with a long-term survival of more than 5 years. They were treated with a combination of radical surgery followed by oral itraconazole.

## Materials and Methods

The clinical profile of the 3 cases who were treated and followed up during January 1996 to December 2006 is presented. The duration of follow-up ranged between 6 and 9 years. The age range was 40 to 50 years, with a mean age of 45 years; the male-to-female ratio was 2:1. The duration of symptoms ranged from 1 day to 20 years. In 2 cases it was of gradual onset causing only visual disturbance without any other neurological deficit while the third case presented as an acute stroke. The lone female patient had unilateral non-pulsatile, non-reducible downward and outward proptosis of 20 years duration without visual loss. The second case had unilateral progressive loss of vision with only perception of light and primary optic atrophy. The third patient with acute onset of stroke presented with right side 3th, 4th, 6th cranial nerve paresis, moderate non-pulsatile proptosis with left hemiplegia. None of the patients were immunocompromised cases. Among these immunocompetent patients, 1 was a farmer by occupation, the second had diabetes of 5 years' duration and the third had chronic sinusitis.

During the same period, we had 2 more cases of intracranial aspergilloma in immunocompetent patients among whom 1 presented with a pituitary lesion with a posterior circulation stroke and later developed hydrocephalus. This patient was treated with injection amphotericin and developed nephrotoxicity and died within 3 months due to disseminated aspergillosis. The second case had sphenoid sinus aspergillosis which extended into the cavernous sinus and presented as proptosis with 3th, 4th and 6th cranial nerves involvement. But this case was treated with oral voriconazole and improved. She is being followed up for the past 2 years. These 2 cases were excluded from this case series.

## Investigations

All patients were investigated with plain radiography of chest, paranasal sinuses, contrast enhanced computed tomography (CT) of brain, orbit and sinuses. A detailed cardiac evaluation including electrocardiogram (ECG), echocardiogram (ECHO), Doppler study of both carotids and vertebrals were performed. In addition to the regular blood investigations including complete blood count, serological test for HIV was also carried out. Among the 2 patients with gradual onset of symptoms, CT scan of the brain revealed an extradurally situated unilateral mass in

the floor of the anterior cranial fossa. This mass elevated the frontal lobe and extended from the frontal bone to the anterior clinoid process. The CT characteristics in the first case were hypodense mass lesion with irregular enhancement of the periphery with contrast. The mass had extended into the medial aspect of the orbit producing proptosis. While in the other case, it was homogeneously enhancing hyperdense lesion with smooth margins situated only intracranially and mimicked like a meningioma (Figs. 1 and 2). No lesion in the sinuses or chest could be identified in the above 2 cases. The patient who presented with an acute stroke in the right posterior cerebral artery territory showed intracranial extension of the sphenoid sinus lesion into the right side cavernous sinus. In all the above cases, serology for HIV and other blood parameters including complete blood counts were normal. Detailed cardiac evaluation did not reveal any cardiac abnormality including thrombus or atrial fibrillation.

## Treatment

Through bifrontal craniotomy the mass was totally excised in the 2 patients with anterior cranial fossa lesion. It was combined with medial orbitotomy in the second case who had extension of the mass into the medial aspect of the orbit. The standard transnasal transphenoidal approach was used to completely remove the sphenoid sinus mass in the case that had a sphenoid sinus lesion that extended into the cavernous sinus. The intracavernous part of the aspergilloma was left in situ.

All the 3 patients were treated with only oral itraconazole during the postoperative period after confirmation of the diagnosis of aspergilloma. A dose of 200 mg twice daily orally were administered for a period of 6 months and their blood counts and liver function were monitored. None of the 3 patients were treated with any form of intravenous amphotericin or any other antifungal drugs. Due to the unavailability of oral voriconazole at that point of time, the same could not be administered to the 3 patients.

## Histopathology Report

The biopsy material in all these cases showed fragments of dense fibrocollagenous tissue infiltrated by chronic inflammatory cells comprising several ill-defined epithelioid cells. These granulomas contain many foreign body types and Langhan's type of giant cells. The giant cells were randomly distributed and had fungal bodies in the cytoplasm. Special stains for fungi (PAS, GMS) showed typical septate, acute branching hyphae characteristic of aspergilloma (Figs. 3 and 4).

## Outcome

The period of follow up of these cases ranged from 6 years to 9 years. The two cases whose intracranial lesion

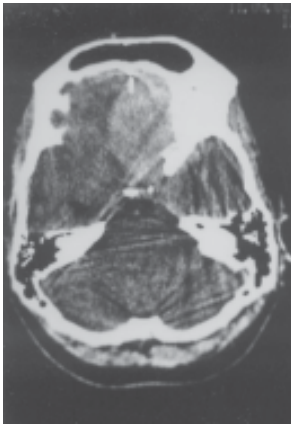


Fig. 1.

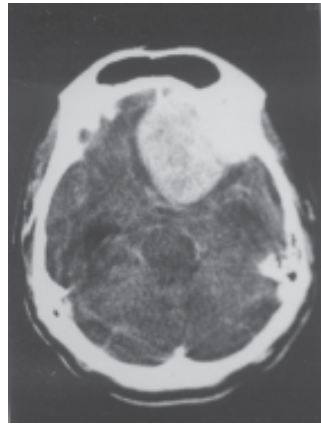


Fig. 2.

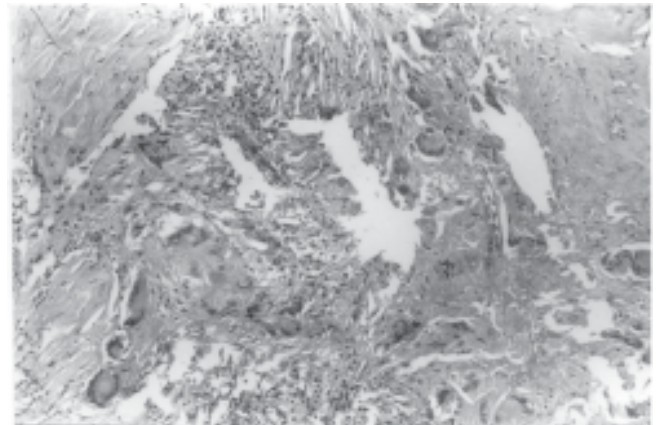


Fig. 3.

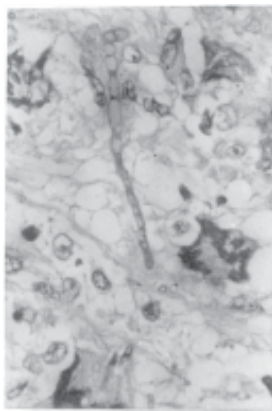


Fig. 4.

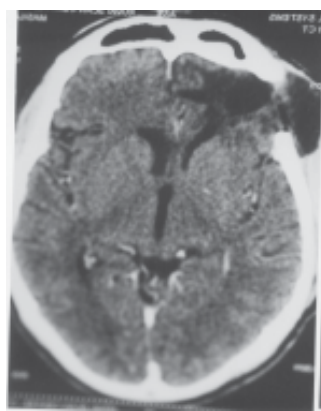


Fig. 5.

was totally excised including the intraorbital part in one case are alive. Postoperative contrast enhanced CT scan of brain done at the end of 5 and 6 years respectively did not reveal recurrence of the lesion (Fig. 5). The vision in the patient who presented with only anterior cranial fossa mass lesion did not recover even at the end of 6 years. The patient who presented with acute stroke improved his motor power in the left hemiplegic side except for minimal diplopia. Follow-up CT brain and sinuses done at the end of 5 years showed complete resolution of the lesion. None of these patients developed any significant drug toxicity even when taken for a prolonged period of 6 months.

### Discussion

Aspergillosis is the commonest fungal infection that causes intracranial granuloma formation.<sup>3,4,12-17</sup> It presents as intracranial space occupying lesion. The commonest sites involved are the frontal and temporal lobes. Localised invasion of the fungus generally from one of the nasal sinuses causes intracranial growth mainly along the base of the skull and larger vessels, where fibrous, granulomatous tissue develops. This generally leads to damage of the cranial nerves (I–V1)<sup>18</sup> as observed in all our cases.

Fig. 1. Preoperative plain computed tomography scan showing a hyperdense lesion in the floor of the anterior cranial fossa.

Fig. 2. Preoperative contrast computed tomography scan showing homogenous enhancement of the hyperdense lesion in the floor of the anterior cranial fossa.

Fig. 3. Numerous multinucleated foreign body type and Langerhans type of giant cells randomly distributed in the dense fibrotic stroma. HE x150.

Fig. 4. Higher magnification showing the septate branching hyphal form of Aspergillus in the stroma. Periodic acid schiff stain x600.

Fig. 5. Postoperative contrast enhanced computed tomography scan showing no recurrence of the lesion.

Aspergillus has a predilection for invading the blood vessel walls causing thrombosis and infarction. Because of the vasocentric nature of the infection, the neurologic presentation is often one of stroke.<sup>19</sup> In one of our cases, the stroke occurred without any cardiac abnormality and in a distant area in the posterior cerebral artery territory. It was away from the primary lesion that was noted in the sphenoid sinus extending into the cavernous sinus. Similar case has been reported, where during the postoperative period the stroke occurred in the posterior circulation territory due to basilar artery thrombosis causing infarction in the cerebellum and midbrain distal to the site of surgery.<sup>20</sup>

The intracranial aspergilloma is hyperdense at CT brain without contrast. Based on the CT findings of a similar lesion, various differential diagnoses have to be considered that included meningioma, tuberculoma and abscess depending upon the location. Characteristic magnetic resonance imaging (MRI) appearances for various fungal granulomas have been described and shown some variability. Aspergillomas have intermediate signal intensity for the granuloma surrounded by perilesional oedema on T2.<sup>14</sup> Hiwatashi et al<sup>21</sup> reported that in granulomatous aspergillosis that is more fibrotic than disseminated aspergillosis, the lesion shows hypointensity on T2-weighted images that is probably caused by haemorrhage or iron accumulation. Since haemorrhage and iron deposition are characteristics of aspergillosis, diffusion-

weighted images and T2-weighted images are helpful for detecting these lesions.<sup>21</sup> Goel et al<sup>22</sup> correlated the MRI findings and histopathological nature of aspergillomas and came to a similar conclusion. The low-signal zones may represent the areas where there was active proliferation of *Aspergillus*. The unique location of the low signal may be a helpful imaging characteristic for the diagnosis of abscess caused by *aspergillus*. They also stated that large venous sinus thrombosis is the common cause of presentation in fungal infection of the CNS. The involvement of the superior sagittal and cavernous sinus is common. This point also requires special attention during MRI evaluation of these patients.

In sinus mass lesions due to aspergilloma, the MRI signal would be markedly hypointense on both T1 and T2 images and may demonstrate peripheral enhancement with gadolinium. This hypointense signal can be a useful distinguishing feature when considering differential diagnosis of a sinus mass. Direct intracranial extension is well demonstrated by multiplanar T2 weighted images as areas of hyperintensity. On post-gadolinium T1 weighted images as abnormal meningeal or parenchymal enhancement. The presence of haemorrhage is often a clue to the underlying diagnosis of intracranial aspergillosis.<sup>23</sup> A detailed clinical history with importance given to the nasal symptoms and paranasal and nasopharyngeal evaluation, further assists in diagnosing an *aspergillus* infection that extends intracranially from the sinuses.

For treating intracranial aspergilloma the commonly recommended treatment regime is surgery followed by oral voriconazole.<sup>4,9</sup> Despite high doses of antifungal drugs and extensive surgery, very high mortality rates have been reported ranging between 28% and 85.7%.<sup>3,4,14-16,24</sup> During our study period, oral voriconazole was unavailable for the treatment of the above condition. Hence, the next alternative was oral itraconazole that was used to treat the above 3 patients. Cone in the reviewer's comment had remarked that itraconazole might be a useful drug in the treatment of intracranial fungal granuloma.<sup>14</sup> Yamanoi et al<sup>12</sup> have reported the effectiveness of oral itraconazole in intracranial aspergillosis. Therapy with oral itraconazole should be prolonged beyond resolution of the disease.<sup>5</sup>

In the 6 largest reported series in the literature<sup>3,4,14-16,25</sup> on intracranial aspergilloma of more than 20 patients accounting to 232 patients, only 4 patients in the series of Siddiqui et al<sup>3</sup> received oral itraconazole preoperatively. They further stated that preoperative orally administered itraconazole therapy might improve clinical outcome in patients with intracranial aspergillosis. In the report of 29 cases of invasive sinus aspergillosis in apparently immunocompetent hosts, Clancy and Nguyen<sup>15</sup> reported

that aggressive surgical resection of the infected areas is of utmost importance in the management of this infection. Resection of the infected tissue eliminates areas of low drug penetration that might contain viable fungi. Addition of antifungal agents during the postoperative period helps in achieving a complete cure of the intracranial aspergillosis. Other authors made similar observations.<sup>3,4,13,14,16,24-28</sup>

Coleman et al<sup>27</sup> reported a patient who survived CNS aspergillosis and additionally reviewed 25 previously published case reports on surviving patients. Among the 26 patients, 21 patients underwent neurosurgical intervention, including 15 with craniotomy and 6 with stereotactic drainage or intracavitary catheters. In Schwartz et al's series of 81 patients, 31 underwent neurosurgical intervention that included craniotomy and abscess resection in 14, abscess drainage in 12, ventricular shunt in 4 and placement of Ommaya reservoir in 1.<sup>4</sup> Their results indicated that neurosurgical intervention was associated with improved outcome in 31% of 81 patients who survived a median observation period of 390 days. These groups of patients were mostly patients with low or chronic immunocompromised patients. Further detailed analyses of these patients with aspergilloma abscess have shown that the combination of radical resection of aspergilloma including its abscess capsule have proven to be effective in improving the long-term outcome when combined with antifungal drugs rather than mere aspiration of the abscess cavity where the capsule is left in situ.<sup>4,27</sup> These reports further supports our view that radical neurosurgical intervention improves the overall outcome.

Our study further substantiates the above therapeutic management strategy. Improved long-term outcome of survival of more than 5 years were achieved in all the three cases. These patients had undergone radical surgery with excision of the aspergilloma combined with oral antifungal drug itraconazole. This is one of the few studies which present the long-term outcome of over 5 years in patients with chronic invasive intracranial aspergilloma. Voriconazole can be tried as an alternative to itraconazole especially in refractory cases.<sup>4</sup> None of the above cases were immuno-compromised and fall in the category of acute invasive CNS aspergillosis. Hence in chronic invasive intracranial aspergilloma in an immunocompetent patient, it is suggested that radical excision of the intracranial aspergilloma combined with oral antifungal drug belonging to triazole group that can be either itraconazole or voriconazole given for a period of 6 months is likely to improve the long-term outcome. Prospective clinical studies are required to make firm clinical therapeutic recommendations.



## Acknowledgements

*I wish to acknowledge the Managing Trustee of PSG Hospitals, Coimbatore, Tamil Nadu, India and Managing Director of MIOT Hospitals, Chennai for permitting me to do the above work in their respective hospitals during the above period. Dr SK Shankar, Professor of Neuropathology and Dr Vani Santhosh, Additional Professor, Department of Neuropathology, National Institute of Mental Health and Neurosciences, Bangalore for reporting on the Histopathology slides.*

## REFERENCES

1. Figueiredo EG, Fonoff E, Gomes M, Macedo E, Marino Junior R. Tumoral form of aspergillosis in central nervous system (cerebral aspergilloma): case report. *Sao Paulo Med J* 2003;121:251-3.
2. Wenzel S, Sagowski C, Kehrl W, Metternich FU. Course and therapy of an invasive aspergilloma of the skull base in a non-immunocompromised patient. *HNO* 2004;52:724-8.
3. Siddiqui AA, Shah AA, Bashir SH. Craniocerebral aspergillosis of sinonasal origin in immunocompetent patients: clinical spectrum and outcome in 25 cases. *Neurosurgery* 2004;55:602-11.
4. Schwartz S, Ruhnke M, Ribaud P, Corey L, Driscoll T, Cornely OA, et al. Improved outcome in central nervous system aspergillosis, using voriconazole treatment. *Blood* 2005;106:2641-5.
5. Stevens DA, Kan VL, Judson MA, Morrison VA, Dummer S, Denning DW, et al. Practice guidelines for diseases caused by *Aspergillus*. Infectious Diseases Society of America. *Clin Infect Dis* 2000;30:696-709.
6. Patterson TF, Kirkpatrick WR, White M, Hiemenz JW, Wingard JR, Dupont B, et al. Invasive aspergillosis: disease spectrum, treatment practices, and outcomes. *Medicine (Baltimore)* 2000;79:250-60.
7. Patterson TF. Advances and challenges in management of invasive mycoses. *Lancet* 2005;366:1013-25.
8. Patterson TF. Treatment of invasive aspergillosis: polyenes, echinocandins, or azoles? *Medical Mycology* 2006;44:357-62.
9. Herbrecht R, Denning DW, Patterson TF, Bennett JE, Greene RE, Oestmann JW, et al. Voriconazole versus amphotericin B for primary therapy of invasive aspergillosis. *N Engl J Med* 2002;347:408-15.
10. Heykants J, Michiels M, Meuldermans W, Monbaliu J. The pharmacokinetics of itraconazole in animals and man: an overview. In: Fromtling RA, editor. *Recent Trends in the Discovery, Development and Evaluation of Antifungal Agents*. Barcelona, Spain: JR Prous Science Publishers, 1987:223-49.
11. Bennet JE. Aspergillosis. In: Braunwald E, Fauci AS, Kasper DL, Hauser SL, Longo DL, Jameson JL, editors. *Harrison's Principles of Internal Medicine*. New Delhi: McGraw Hill Co, 2003: 1178-9.
12. Yamanoi T, Shibano K, Soeda T, Hoshi A, Matsuura Y, Sugiura Y et al. Intracranial invasive aspergillosis originating in the sphenoid sinus: a successful treatment with high-dose itraconazole in three cases. *Tohoku J Exp Med* 2004;203:133-9.
13. Giacchino M, Chiapello N, Riva C, Scolfaro C, Pultrone M, Valera M, et al. Intracranial aspergillosis in children successfully treated with antifungal therapy and surgical intervention. *Pediatr Infect Dis J* 2006;25:379-81.
14. Dubey A, Patardhan RV, Sampath S, Santosh V, Kolluri S, Nanda A. Intracranial fungal granulomas: analysis of 40 patients and review of the literature. *Surg Neurol* 2005;63:254-60.
15. Clancy CJ, Nguyen MH. Invasive sinus aspergillosis in apparently immunocompetent hosts. *Infect* 1998;37:229-40.
16. Sharma BS, Khosla VK, Kak VK, Banerjee AK, Vashishtha RK, Prasad KS, et al. Intracranial fungal granuloma. *Surg Neurol* 1997;47:489-97.
17. Santosh V, Yasha TC, Khanna N, Pal L, Swamy HS, Chandramuki A, et al. Fungal infections of the central nervous system – a pathological study. *Neurological Infections and Epidemiology NiE* 1996;1:69-79.
18. Winkler F, Seelos K, Hempel JM, Pfister HW. Localized invasive intracranial aspergillosis with multiple cranial nerve failure – case report and review of the literature. *Nervenarzt* 2002;73:1186-90.
19. Harrison MJG, McArthur JC. Cerebral infections in AIDS: coccidioidomycosis, histoplasmosis and other fungal infections. *Infect Med* 1998;15:474-8.
20. Nadkarni TD, Desai KI, Muzumdar D, Goel A, Shenoy A. Ischemic complications after surgical resection of intracranial aspergilloma. *J Clin Neurosci* 2003;10:500-2.
21. Hiwatashi A, Kinoshita T, Moritani T, Wang HZ, Shrier DA, Numaguchi Y, et al. Hypointensity on diffusion-weighted MRI of the brain related to T2 shortening and susceptibility effects. *AJR Am J Roentgenol* 2003;181:1705-9.
22. Goel D, Bansal KK, Gupta C, Kishor S, Srivastav RK, Raghuvanshi S, et al. Why we missed an early diagnosis of cerebral aspergilloma: lesson from a case. *Ann Indian Acad Neurol* 2007;10:263-5.
23. Whiteman MLH, Bowen BC, Post MJD, Bell MD. Intracranial infection. In: Scott WA, editor. *Magnetic Resonance Imaging of the Brain and Spine*. Philadelphia: Lippincott Williams and Wilkins, 2002;21: 1099-175.
24. Pongbhaesaj P, Dejthevaporn C, Tunlayadechanont S, Witoonpanich R, Sungkanuparph S, Vibhagool A. Aspergillosis of the central nervous system: a catastrophic opportunistic infection. *Southeast Asian J Trop Med Public Health* 2004;35:119-25.
25. Murthy JM, Sundaram C, Prasad VS, Purohit AK, Ramamurti S, Laxmi V. Sinocranial aspergillosis: a form of central nervous system aspergillosis in South India. *Mycoses* 2001;44:141-5.
26. Haran RP, Chandy MJ. Intracranial aspergillus granuloma. *Br J Neurosurg* 1993;7:383-8.
27. Coleman JM, Hogg GG, Rosenfeld JV, Waters KD. Invasive central nervous system aspergillosis: cure with liposomal amphotericin B, itraconazole, and radical surgery – case report and review of the literature. *Neurosurgery* 1995;36:858-63.
28. Das SK, Bhattacharya S, Mitra K, Roy T, Bhattacharya M, Ghorai SP, et al. Central nervous system fungal infection – a report of three cases. *J Indian Med Assoc* 2004;102:634-43.