

Obturator Hernia in an Ageing Society

Masashi Haraguchi,^{1,2MD}, Shigetoshi Matsuo,^{1MD}, Kengo Kanetaka,^{2MD}, Hiroataka Tokai,^{1MD}, Takashi Azuma,^{1MD}, Satoshi Yamaguchi,^{1MD}, Takashi Kanematsu,^{2MD}

Abstract

Introduction: Obturator hernia is an important cause of small bowel obstruction and is associated with difficult diagnosis and high mortality. **Materials and Methods:** We reviewed 22 cases of intestinal obstruction due to obturator hernia that necessitated surgical intervention over the last 17 years and evaluated the changes in the number of patients based on the census data. **Results:** All cases were elderly females. The Howship-Romberg sign was present in 15 patients (68%). Computed tomography (CT) correctly diagnosed 13/15 (87%) of cases in which it was performed prospectively. The median time to surgery was 7.5 ± 5.2 days for those patients with bowel resection, compared to 0.8 ± 1.3 days for those without ($P < 0.05$). The number of patients with obturator hernia has increased with an ageing society. **Conclusions:** The rising incidence of obturator hernia is probably linked to an ageing society. CT of the pelvis was helpful in obtaining the correct diagnosis. The shorter the delay between admission and surgery, the lower the bowel resection rate. Laparotomy at an early stage is recommended in such patients as it leads to reduced morbidity and mortality.

Ann Acad Med Singapore 2007;36:413-5

Key words: Census, Computed tomography, Female

Introduction

Obturator hernia is often seen in elderly, thin females and is usually manifested by recurrent bouts of intestinal obstruction and thigh or knee pain on the affected side, without a history of previous abdominal surgery. Patients with small bowel obstruction due to obturator hernia represent 3.9% of all adult abdominal hernia repairs performed over the last 17 years at Nagasaki Prefectural Shimabara Hospital.

The aim of the present retrospective study was to report our experience with a view to identifying clinical features that help in earlier diagnosis and treatment and to evaluate the changes in the number of patients with obturator hernia.

Materials and Methods

From January 1985 to March 2002, a total of 555 adult patients with abdominal hernia were admitted and 22 (3.9%) of these patients were treated for small bowel obstruction due to obturator hernia at the Department of Surgery, Nagasaki Prefectural Shimabara Hospital. The

clinical records of these 22 patients were retrospectively reviewed with respect to patient characteristics, clinical presentation, radiological findings, operative findings, and treatment and outcome. In addition, we evaluated the changes in the number of patients with obturator hernia.

Results

Patient Characteristics and Clinical Presentation

All 22 patients were elderly females. The age range was 68 to 91 years, with a mean age of 79.5 years. Body weight on admission ranged from 31 to 45 kg, with a mean of 36.5 kg. All the patients presented with intestinal obstruction. The presenting symptoms were abdominal pain, vomiting and abdominal distension. The duration of symptoms prior to admission ranged from 1 to 21 days, with a mean of 5.8 days. In all 22 patients, no mass could be palpated upon abdominal examination. Three patients had undergone previous abdominal surgery. The Howship-Romberg sign, which refers to ipsilateral groin pain radiating down to the thigh due to irritation of the obturator nerve, was present in

¹ Department of Surgery, Nagasaki Prefectural Shimabara Hospital, Nagasaki, Japan

² Department of Surgery, Graduate School of Biochemical Sciences, Nagasaki University, Nagasaki, Japan

Address for Correspondence: Dr Masashi Haraguchi, Department of Surgery, Graduate School of Biochemical Sciences, Nagasaki University 1-7-1 Sakamoto, Nagasaki City, Nagasaki 852-8501, Japan.

Email: haraguci@mb.ejnet.ne.jp

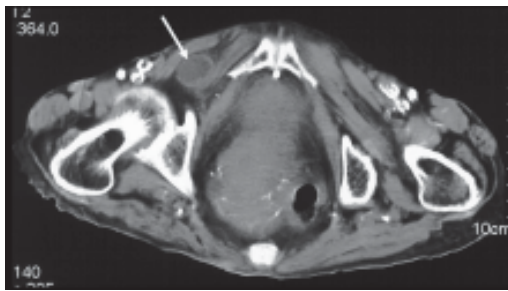


Fig. 1. The image through the pelvis demonstrates a small mass (arrow), consistent with a loop of bowel, lying between the obturator externus muscle and pectineus muscle.

15 (68%) of all 22 patients, including 5 patients with retrospective confirmation after diagnosis was made.

Radiological Findings

An erect and supine plain abdominal radiograph revealed dilated small bowel loops with multiple air-fluid levels in all patients. Computed tomography (CT) of the pelvis was used in 15 (68%) of the 22 patients. In 13 of these 15 patients (87%), CT showed a mass between the external obturator and pectineal muscles and that the correct diagnosis had been suspected preoperatively (Fig. 1).

Operative Findings and Treatment

Surgical repair of the obturator hernia was performed through a variety of approaches (intra-abdominal approach in 17 patients, inguinal approach in 1 patient and both approaches in 4 patients). None of the patients underwent laparoscopic repair. In 17 patients (77%), the obturator hernia was on the right side, whereas the remaining 5 patients (23%) had left-sided involvement. All 22 patients had small bowel involvement in the hernia. Resection of small bowel was performed in 17 patients, whereas reduction of incarcerated small bowel without resection was performed in 5 patients. The medium treatment delay (7.5 ± 5.2 days) of 17 patients with gut resection was significantly longer than that (0.8 ± 1.3 days) of 5 patients without gut resection ($P < 0.05$). The defect at the hernia site was repaired, using an ovary in 2 patients and a sigmoid colon in 1 patient, and with a few interrupted non-absorbable sutures in 19 patients.

Outcome

All patients, except for 1 who died of sepsis after operation, were discharged. The overall mortality rate was 4.5%. Postoperative complications included intra-abdominal abscess ($n = 1$), major leakage ($n = 1$), acute renal failure ($n = 1$), wound infection ($n = 1$) and pneumonia ($n = 1$).

Changes in Patient Number and Census Data

We investigated the change in the number of patients with obturator hernia and the number of females based on

the census data every 5 years because all patients with obturator hernia in our hospital were females (Table 1). Figure 2a shows that the proportion of the females over 80 years of age has increased in Shimabara city. Figure 2b shows that the number of patients with obturator hernia has increased in spite of the decrease in population, with 5 patients from 1985 to 1989, 6 patients from 1990 to 1995, and 11 patients from 1996 to March 2002.

Table 1. Census Data

Census year	Both genders	Shimabara City		
		Female	70-79 years	>80 years
1985	46,061	24,731	1842 (7.4%)	910 (3.7%)
1990	44,828	24,208	1973 (8.2%)	1171 (4.8%)
1995	40,778	21,995	2200 (9.1%)	1352 (5.6%)
2000	39,605	21,417	2567 (11.7%)	1595 (7.3%)

Discussion

Nagasaki Prefectural Shimabara Hospital is the only general hospital in Shimabara city with a catchment area comprising a population of 60,000 people. Shimabara area is an isolated district and the proportion of elderly people in the population has increased from year to year. In June 1993, a dormant volcano near our hospital erupted. Many people moved out and the eruption dealt a severe blow to our hospital. However, the proportion of females over 80 years of age changed from 3.7% in 1985 to 7.3% in 2000 (Fig. 2a). The number of patients with obturator hernia also increased from 5 patients (1985 to 1989) to 11 patients (1996 to March 2002). The number of patients with obturator hernia has increased with an ageing society in the Shimabara area.

Obturator hernia is most commonly seen in underweight, chronically ill females between the seventh and ninth decades of life. Females are affected 6 times more frequently than males.¹ Some reports have shown that obturator hernia is difficult to diagnose preoperatively and has a high mortality rate.^{1,2} The reported mortality ranges from 12% to 70%.³ Postoperative complications (pneumonia, wound infection, sepsis and so on) have been reported in 11.6% of patients.⁴

The Howship-Romberg sign and intestinal obstruction are the most common presentation of obturator hernia and are reported to occur in 45% to 50% of patients.^{2,5-9} This sign was present in 15 (68%) of all 22 patients, including retrospective confirmation by 5 patients after a diagnosis was made. However, because arthritis is common in elderly patients, this sign is often mistaken for arthritis and therefore ignored.

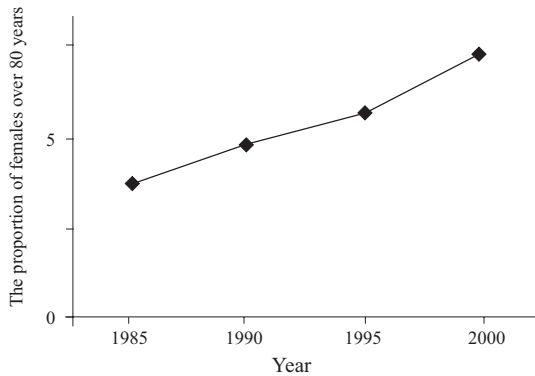


Fig. 2a. The proportion of females over 80 years of age based on the census data in Shimabara city. 1985: 910/24731 (3.7%), 1990: 1171/24208 (4.8%), 1995: 1352/21995 (5.6%), 2000: 1595/21417 (7.3%).

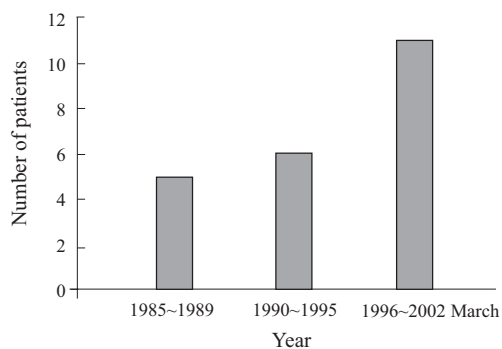


Fig. 2b. Change in the number of patients with obturator hernia from 1985 to 2002.

In our hospital, the overall mortality rate was 4.5%, which is low in comparison to other reported series.^{2,5} However, it is difficult to prove this scientifically. When we examine elderly, chronically ill and thin females with intestinal obstruction, we suspect obturator hernia, and CT of the pelvis is used with success in the diagnosis of obturator hernia. CT of the pelvis was not previously used for the diagnosis of obturator hernia. Recently, the rate of patients with the correct diagnosis by CT of the pelvis was 87%.

From 1995 to 2000, 251 surgical repairs of obturator hernia were reported in the Japanese literature. The intra-abdominal approach was used in 219 patients, the inguinal approach was used in 11 patients, the laparoscopic approach in 10 patients and a combination of both in 10 patients. One

patient was treated using another method.⁴ An intra-abdominal approach was most favoured. We have also recommended the intra-abdominal approach because we can establish the diagnosis, obtain adequate exposure, protect the obturator vessels and identify and resect the compromised bowel when necessary.

In conclusion, the number of patients with obturator hernia will certainly increase in the future with an ageing society. A high index of suspicion is essential to the diagnosis when facing an elderly emaciated female with small bowel obstruction. Pain along the ipsilateral thigh and knee should raise suspicion for obturator hernia. Further, CT of the pelvis would confirm the correct diagnosis preoperatively and allow prompt treatment and a better chance of survival. Though no one was repaired laparoscopically in our hospital, the laparoscopic approach to obturator hernia repair should be performed in the future.¹⁰ Finally, it is most important to keep the possibility of obturator hernia in mind when making a diagnosis.

REFERENCES

1. Sinha SN, DeCosta AE. Obturator hernia. *Aust N Z J Surg* 1983;53:349-51.
2. Gray SW, Skandalakis JE, Soria RE, Rowe JS Jr. Strangulated obturator hernia. *Surgery* 1974;75:20-7.
3. Angstman KB, Myers JW, Olson RT. Obturator hernia – a rare cause of intestinal obstruction. *J Fam Pract* 1986;23:370-2.
4. Kono T, Hyuga T, Honda Y. Obturator hernia – A statistical study of 257 domestic cases in the past six years [Japanese]. *J Jpn Surg Assoc* 2002;63:1847-52.
5. Martin NC, Welch TP. Obturator hernia. *Br J Surg* 1974;61:547-8.
6. Cali RL, Pitsch RM, Blatchford GJ, Thorson A, Christensen MA. Rare pelvic floor hernias. Report of a case and review of the literature. *Dis Colon Rectum* 1992;35:604-12.
7. Lo CY, Lorentz TG, Lau PW. Obturator hernia presenting as small bowel obstruction. *Am J Surg* 1994;167:396-8.
8. Rizk TA, Deshmukh N. Obturator hernia: a difficult diagnosis. *South Med J* 1990;83:709-12.
9. Chung CC, Mok CO, Kwong KH, Ng EK, Lau WY, Li AK. Obturator hernia revisited: a review of 12 cases in 7 years. *J R Coll Surg Edinb* 1997;42:82-4.
10. Miki Y, Sumimura J, Hasegawa T, Mizutani S, Yoshioka Y, Sasaki T, et al. A new technique of laparoscopic obturator hernia repair: report of a case. *Surg Today* 1998;28:652-6.