

## Concurrent Intermediate Uveitis and an Enhancing Intracranial Lesion as the Initial Manifestation of Sarcoidosis

Elaine HZ Huang,<sup>1</sup>*MBBS*, Kim-Teck Yeo,<sup>2</sup>*FRCS (Edin), FRCOphth, FAMS*, Wee-Kiak Lim,<sup>3</sup>*M Med, FRCS, FRCOphth*, Cora YP Chau,<sup>4</sup>*FRCPA, FHKAM (Path)*, William YK Hwang,<sup>5</sup>*MRCP (UK), FAMS (Haematol), M Med (Int Med)*

### Abstract

**Introduction:** Posterior segment involvement has been described to be associated with central nervous system involvement in sarcoidosis as a result of direct sarcoid tissue infiltration or mass effect of a cerebral lesion. However, isolated intermediate uveitis occurring concurrently with central nervous system involvement prior to extensive systemic disease is rare. **Clinical Picture:** We describe a patient with neuro-ophthalmic manifestations of intermediate uveitis and an enhancing basal ganglia lesion at initial presentation, in the absence of extensive systemic disease. **Treatment:** He was treated with high-dose systemic steroids which was progressively tailed down over 6 months. **Outcome:** There was prompt resolution of vitritis with good preservation of visual acuity. **Conclusion:** The difficulties of the initial diagnosis of sarcoidosis and the indications for initiation of steroid therapy are illustrated. We use this case to emphasise the need for a high clinical suspicion of sarcoidosis in the presence of similar unusual and seemingly unrelated combinations of neurological manifestations so as to facilitate the prompt institution of appropriate treatment when indicated.

*Ann Acad Med Singapore 2006;35:266-9*

**Key words:** Basal ganglia, Neurological, Ophthalmic

### Introduction

Sarcoidosis remains an enigmatic disease with protean manifestations. It is a multi-system disorder of unknown cause characterised by an accumulation of T-lymphocytes, mononuclear phagocytes and non-caseating epithelioid granulomas in affected organs. The diverse manifestations of sarcoidosis make prompt diagnosis difficult, yet early diagnosis is imperative in facilitating appropriate therapy.

The criteria for establishing the diagnosis of sarcoidosis are twofold: (a) Suggestive clinical and/or radiological features with evidence of generalised involvement. (b) Histological proof of sarcoidosis from at least one tissue sample. Evidence of one without the other is insufficient, for clinical or radiological manifestations alone present too wide a differential-diagnostic problem. Conversely, isolated histological evidence of sarcoid tissue could be construed as a local sarcoid-tissue reaction.<sup>1</sup>

### Case Report

A 34-year-old Chinese male first presented to the Accident and Emergency Department with sudden onset of left upper and lower limb weakness and numbness, associated with left upper motor neuron facial nerve palsy. Computed

tomography (CT) scan of the brain at the Emergency Department did not reveal any obvious cerebrovascular event.

A magnetic resonance imaging (MRI) and magnetic resonance angiography (MRA) of the brain revealed T2-weighted and diffusion-weighted hyperintense areas in the **right** caudate nucleus, anterior internal capsule, corona radiata and putamen, raising the possibility of an acute infarct (Figs. 1a and 1b). MRA showed only moderate stenosis of the distal **left** internal carotid artery.

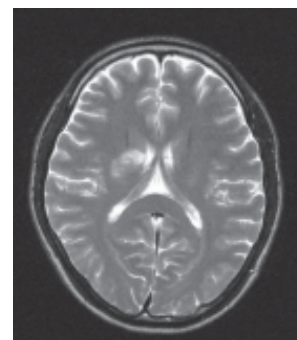
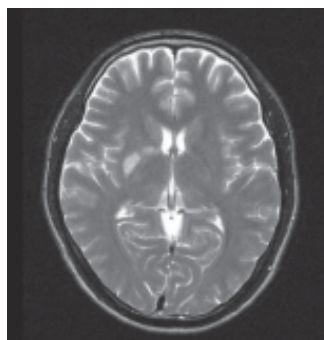


Fig. 1a

Fig. 1b

Figs. 1a and 1b. T2-weighted MRI brain images show hyperintense areas in the right basal ganglia.

<sup>1</sup> Singapore National Eye Centre, Singapore

<sup>2</sup> Vitreo-Retinal Service, Singapore National Eye Centre, Singapore

<sup>3</sup> Ocular Inflammation and Immunology Service, Singapore National Eye Centre, Singapore

<sup>4</sup> Department of Pathology, Singapore General Hospital, Singapore

<sup>5</sup> Department of Haematology, Singapore General Hospital, Singapore

Address for Reprints: Dr Elaine Huang Huizhen, Singapore National Eye Centre, 11 Third Hospital Avenue 3, Singapore 168751.

Email: elainenhz@yahoo.co.uk

He had no significant risk factors for a cerebral vascular accident. Haematologic markers for connective tissue disease, prothrombotic factor levels and venereal disease research laboratory (VDRL) testing were negative.

The left-sided weakness and numbness did not last more than 24 hours, and the left upper motor neuron facial nerve palsy resolved within 9 days after onset. He was treated as for an ischaemic cerebral infarction and aspirin was started, however, there were no convincing contributory biochemical or radiological factors for his early cerebral vascular accident.

There was an incidental finding of a slightly widened right paratracheal region on his chest radiograph (Fig. 2). Beta 2 microglobulin levels were mildly raised at 2130 UG/L. Infective markers, absolute CD 4, CD 8 and CD 4/CD 8 ratio were within normal limits.

CT scans of the thorax done for further work-up of the widened mediastinum showed enlarged mediastinal and pretracheal lymph nodes (Figs. 3a and 3b).

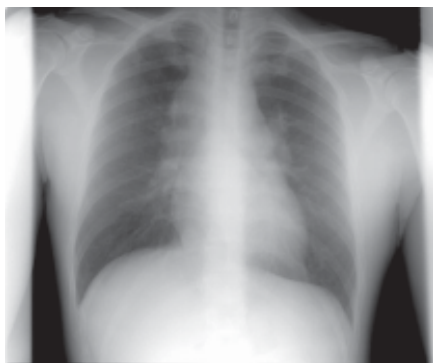

Fig. 2. Chest radiograph shows widening of the paratracheal region.

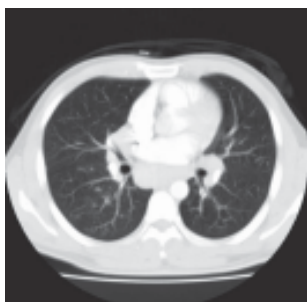

Fig. 3a

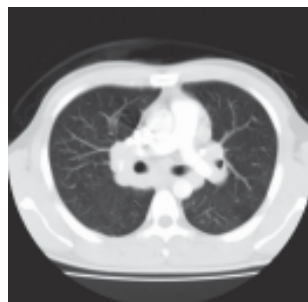

Fig. 3b

Figs. 3a and 3b. CT thorax images show enlarged pretracheal and hilar lymph nodes.

Mediastinoscopy with biopsy of the mediastinal lymph nodes was performed. Frozen sections revealed non-caseating granulomatous inflammation (Figs. 4a and 4b).

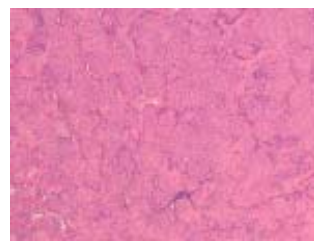


Fig. 4a

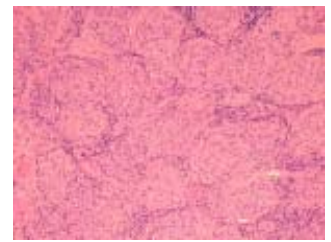


Fig. 4b

Fig. 4a. The lymph node architecture is effaced and replaced by non-caseating granulomas (H & E, x100).

Fig. 4b. The granulomas are formed by aggregates of epithelioid histiocytes (H & E, x200).

He was started on anti-tuberculosis (TB) medications. However, TB cultures from the lymph node biopsy subsequently returned as negative and at this point, the diagnosis of sarcoidosis was made in the presence of non-caseating granulomatous inflammation and negative cultures for TB. In retrospect, the enhancing basal ganglia lesion was likely to be a manifestation of neurosarcoidosis, although his pulmonary disease was not extensive.

At this juncture, he brought up complaints of floaters and blurring of vision in his left eye. He was then referred for ophthalmologic assessment. Visual acuity was 6/9 in the left and 6/6 in the right at presentation. Examination revealed findings of primarily an intermediate uveitis with snowball opacities in the vitreous of the left eye. There was no concomitant anterior segment involvement. Fluorescein fundal angiography (FFA) showed the presence of mild periphlebitis with leakage of dye. There was an incidental scar inferior to the macula in the right eye with a corresponding window defect on FFA (Figs. 5 and 6a to 6g).

The degree of his thoracic involvement had not warranted initiation of treatment, but the retrospective diagnosis of neurosarcoidosis and onset of ocular involvement were, even individually, sufficient indications for steroids.<sup>1</sup> He

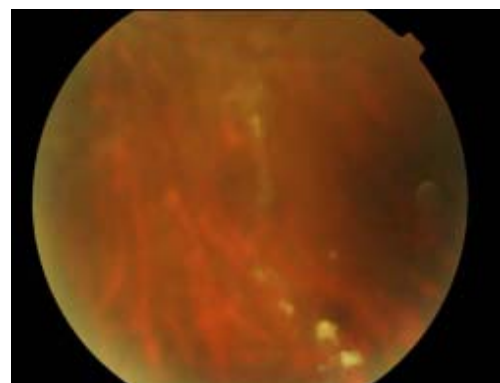


Fig. 5. Fundal photo shows snowball opacities in the vitreous of the left eye.

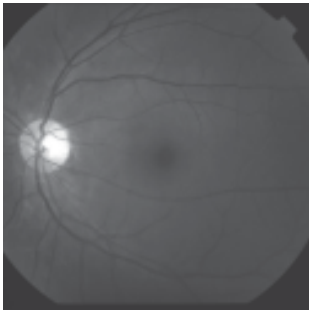


Fig. 6a

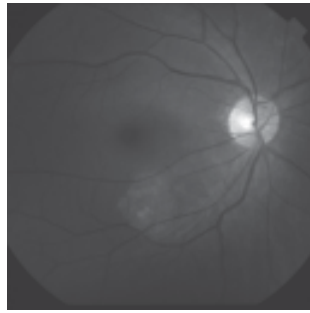


Fig. 6b

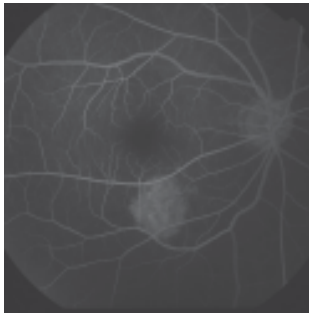


Fig. 6c

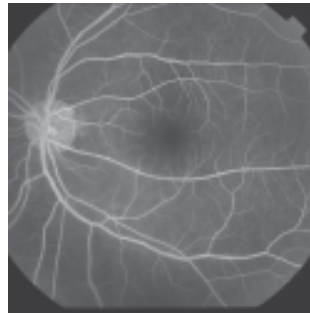


Fig. 6d

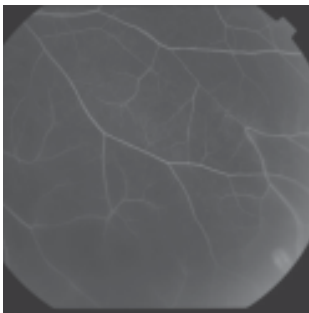


Fig. 6e

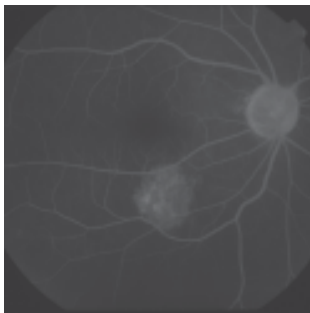


Fig. 6f

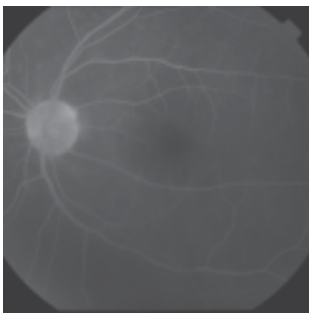


Fig. 6g

Figs. 6a-6g. Fluorescein fundal angiography shows the presence of mild periphlebitis.

was started on high-dose oral prednisolone of 40 mg a day with progressive resolution of vitritis, visual acuity preserved at 6/6 in the right eye and 6/7.5 in the left. The prednisolone was subsequently tailed off.

### Discussion

The interesting myriad of clinical manifestations in our patient is described. He presented with a rare combination of concurrent neurosarcoid and intermediate uveitis, with

an extent of thoracic involvement that did not even warrant initiation of steroid therapy.

Central nervous system (CNS) involvement in patients with diagnosed sarcoidosis has been reported globally as rare, affecting 1% to 5% in a Spanish journal,<sup>2</sup> 5% in the Japanese population,<sup>3</sup> and 7% of patients with sarcoidosis in a British publication.<sup>4</sup>

Ocular involvement manifests in about 30% of patients with systemic sarcoidosis,<sup>5</sup> but uveitis as a presenting manifestation is rare with an incidence of 1.5%.<sup>6</sup>

Concurrent neurological and ocular sarcoidosis at initial presentation before widespread sarcoidosis is even less common. Isolated cases have been reported in other parts of the world,<sup>7-9</sup> describing rare occurrences of concurrent neurological and ocular involvement in the absence of extensive systemic involvement. A Californian case report described an unusual initial manifestation of optic neuropathy without inflammatory signs elsewhere in the eye or the rest of the body. Subsequent investigations led to the finding of a mass in the temporal fossa that craniotomy and biopsy revealed non-caseating granulomas consistent with neurosarcoidosis.<sup>8</sup>

The association between posterior segment and CNS involvement has been described.<sup>10</sup> Optic nerve involvement has been postulated to be caused either by direct sarcoid tissue infiltration or compression by a cerebral mass, which may lead to optic nerve atrophy.<sup>11-14</sup> In the same light, the development of optociliary shunts, choroidal granulomas, exudative detachments of the neurosensory retina and retinal pigment epithelial detachments have been described.<sup>14</sup> However, an isolated intermediate uveitis concurrent with CNS involvement is rare.

We also use this case report to illustrate the difficulties of accurately identifying the many manifestations of sarcoidosis and ensuring timely initiation of the appropriate treatment.

The diagnosis of neurosarcoidosis in this patient only became apparent in retrospect because of the absence of significant risk factors for a cerebral vascular accident at his age, the transient nature of his neurological deficits and the subsequent mediastinal lymph node histology of non-caseating granulomatous inflammation with negative TB cultures.

In patients with central nervous system involvement, transient facial nerve involvement was found to be the most frequent neurological presentation in a UK publication, and when bilateral facial nerve palsy occurred in a young patient, sarcoidosis was found to be the most likely cause.<sup>15</sup> Rapid and complete resolution of facial palsy secondary to neurosarcoidosis was found in 80% of patients in the same paper.

In 2004, Nakagaki et al<sup>16</sup> reported a case of neurosarcoidosis associated with brain infarction. This patient had known sarcoidosis and presented with sudden-onset hemiplegia. MRI of the brain revealed high-intensity lesions in the parieto-occipital lobes on diffusion-weighted images suggestive of acute infarction. Biopsy of the causative lesions showed the presence of non-caseating epithelioid granulomas within the infarcted brain tissue, consistent with neurosarcoidosis.

Contributing to the difficulty of diagnosis is the fact that serum biochemical markers are also non-specific.<sup>17</sup> Elevated beta 2 microglobulin levels in sarcoidosis are due to the non-specific polyclonal stimulation of B-cells by activated T-cells at the site of the affected organs. This can mimic lymphoma particularly with concomitant chest radiograph findings of a widened mediastinum.

Also, CD 4/CD 8 ratio in the blood cannot reflect disease activity of sarcoidosis as there is compartmentalisation of the immune system such that despite the exaggerated rate of T-cell proliferation at the sites of the involved organs, the number of T helper cells in the blood remains normal or slightly low, thus rendering it unhelpful towards diagnosis or monitoring of disease activity.

The heterogeneity of the manifestations of sarcoidosis, its uncertain clinical course and the potential side effects of treatment compound the challenge of clinical management. Patients should initially be observed without therapy because of the potential for spontaneous improvement,<sup>18</sup> unless indications like severe ocular, neurologic, cardiac sarcoidosis or progressive pulmonary disease exist.<sup>19,20</sup> It is therefore important to determine the presence of ocular involvement early as it warrants digression from expectant management.

Yet the prompt diagnosis of sarcoidosis itself is difficult, and many patients with concurrent ocular inflammation may be asymptomatic,<sup>21</sup> resulting in permanent ocular damage and development of irreversible complications.<sup>21-23</sup> Therefore, unusual combinations of neurological deficits should lower the threshold for the clinical suspicion of sarcoidosis. It is also prudent to be vigilant with ophthalmological follow-up even in patients with no ocular symptoms.

## Conclusion

We report the interesting presenting manifestations of our patient and use this to illustrate the need to consider the diagnosis of sarcoidosis in the presence of unusual and seemingly unrelated combinations of neurological deficits. This would help in the institution of prompt treatment. Furthermore, a firm diagnosis of ocular sarcoidosis would lend weight to an uncertain diagnosis of neurosarcoidosis, even in the absence of extensive systemic disease.

## REFERENCES

1. James DG. Sarcoidosis. *Curr Med Drugs* 1967;7:10-21.
2. Garcia Berrocal JR, Trinidad A, Vargas JA, Hijos M, Ramon y Cajal S, Ramirez Camacho R. Sudden hearing loss and uveitis as a form of presentation of neurosarcoidosis [Spanish]. *Acta Otorrinolaryngol Esp* 1998;49:488-90.
3. Iwata M, Kondo M, Ando M, Tano M, Inagaki Y, Shimizu Y. Peripheral polyneuropathy due to sarcoidosis in a patient with intrathoracic, ocular and skin lesions. *Nihon Kyobu Shikkan Gakkai Zasshi* 1993;31:1050-5.
4. Turner RG, James DG, Friedmann AI, Vijendram M, Davies JP. Neuro-ophthalmic sarcoidosis. *Br J Ophthalmol* 1975;59:657-63.
5. Constantino T, Digre K, Zimmerman P. Neuro-ophthalmic complications of sarcoidosis. *Semin Neurol* 2000;20:123-37.
6. Rizzato G, Angi M, Fraioli P, Montemurro L, Pilotto E, Tommasini A. Uveitis as a presenting feature of chronic sarcoidosis. *Eur Respir J* 1996;9:1201-5.
7. Ghabrial R, McCluskey PJ, Wakefield D. Spectrum of sarcoidosis involving the eye and brain. *Aust N Z J Ophthalmol* 1997;25:221-4.
8. Katz B. Disc edema, transient obscurations of vision, and a temporal fossa mass. *Surv Ophthalmol* 1991;36:133-9.
9. Hayashi E, Niwa A, Narita Y, Kuzuhara S. A case of sarcoidosis with simultaneous involvement of the lower brainstem and the whole cervical cord and the extraocular muscles (Japanese). *Rinsho Shinkeigaku* 2001;41:314-7.
10. Hunter DG, Foster CS. Ocular manifestations of sarcoidosis. *Principles and Practice of Ophthalmology* 1994;443-50.
11. Rothova A. Ocular involvement in sarcoidosis. *Br J Ophthalmol* 2000;84:110-6.
12. Beardsley TH, Brown SV, Sydnor CF. Eleven cases of sarcoidosis of the optic nerve. *Am J Ophthalmol* 1984;1:62-77.
13. Karma A, Mustonen EM. Optic nerve involvement in sarcoidosis. *Neuroophthalmology* 1985;5:231-46.
14. Mansour AM. Sarcoid optic disc edema and optociliary shunts. *J Clin Neuroophthalmol* 1986;6:47-52.
15. James DG. Differential diagnosis of facial nerve palsy. *Sarcoidosis Vasc Diffuse Lung Dis* 1997;14:115-20.
16. Nakagaki H, Furuya J, Nagata T, Kotorii S, Nagano S, Higashino T. An elder case of neurosarcoidosis associated with brain infarction (Japanese). *Rinsho Shinkeigaku* 2004;44:81-5.
17. Oksanen V, Gronhagen-Riska C, Fyhrquist F, Somer H. Systemic manifestations and enzyme studies in sarcoidosis with neurologic involvement. *Acta Med Scand* 1985;218:123-7.
18. Newman LS, Rose CS, Maier LA. Sarcoidosis. *N Engl J Med* 1997;336:1224-34.
19. Sharma OP. Pulmonary sarcoidosis and corticosteroids. *Am Rev Respir Dis* 1993;147:1598-600.
20. Selroos O. Treatment of sarcoidosis. *Sarcoidosis* 1994;11:80-3.
21. Lauby TJ. Presumed ocular sarcoidosis. *Optometry* 2004;75:297-304.
22. Kogure M. Treatment of ocular manifestation of sarcoidosis (Japanese). *Nippon Rinsho* 1994;52:1654-8.
23. Dios Castro E, Herreras Cantalapiedra JM, Calonge Cano M, Osés S. Ocular sarcoidosis. Retrospective study of 18 cases [Spanish]. *Arch Soc Esp Oftalmol* 2002;77:301-8.