

## Artificial Urinary Sphincter in Adult Male with Neurogenic Stress Urinary Incontinence: A Rare Indication

KL Toh,<sup>1</sup> MBBS, FRCS (Edin), FRCS (Glas), JK Tan,<sup>1</sup> MBBS, FRCS (Edin), FRCS (Glas)

### Abstract

**Introduction:** The artificial urinary sphincter (AUS) is a rare indication for stress urinary incontinence secondary to spinal cord injury. **Clinical Picture:** A 48-year-old male sustained spinal cord injury, resulting in detrusor acontractility and urinary stress incontinence. **Treatment and Outcome:** An AUS was implanted and the patient achieved complete urinary continence. **Conclusion:** The AUS is an appropriate and durable device for management of patients with neurogenic stress incontinence.

Ann Acad Med Singapore 2005;34:389-90

**Key words:** Artificial, Bladder neck, Prosthesis and implants, Urinary incontinence, Urinary sphincter

### Introduction

The artificial urinary sphincter (AUS) is an established modality for the management of stress urinary incontinence. It is usually used in adults with post-radical prostatectomy incontinence<sup>1</sup> and in children with neurogenic voiding dysfunction usually secondary to spinal dysraphism.<sup>2</sup> However, it is rarely used in adults with neurogenic stress incontinence due to spinal cord injury and to our knowledge, this is the first such case to be reported locally.

### Case Report

A 48-year-old male sustained, in a motor vehicle accident, complete spinal cord injury (American Spinal Injury Association score A) at the level of the first lumbar vertebra and was wheelchair-bound. His voiding dysfunctions, as demonstrated on videourodynamic studies, included detrusor acontractility and stress urinary incontinence. Valsalva leak point pressure was 54 cm of water pressure (Fig. 1). Management included clean intermittent self-catheterisation for bladder emptying but he required diapers to cope with the stress leakage, severely affecting his life. As such, an AMS 800 (American Medical Systems, Minnetonka, Minnesota) AUS device was implanted. The AUS components used were an 8.0-cm cuff placed at the bladder neck, a 70- to 80-cm pressure regulating balloon

and a pump, which was implanted in the left hemiscrotum. At the time of writing, it had been 12 months since his surgery and he was continent.

### Discussion

Since the introduction of the AUS 3 decades ago by Scott et al,<sup>1</sup> the AUS has established itself as an excellent option for 2 major categories of patients: adults with post-radical prostatectomy stress incontinence and children with neurogenic voiding dysfunction commonly due to spinal dysraphism. However, its use in adults with neurogenic dysfunction secondary to spinal cord injury is rare and limited to those with stress incontinence and the dexterity required to activate the device.

A primary reason for the limited use of AUS in patients with neurogenic voiding dysfunction centres on the compatibility of the AUS with intermittent catheterisation, which many of these patients need. The fear was that with repeated urethral catheterisation, there is a higher risk of device erosion into the urethra and infection. The risk of urinary tract infection in patients performing clean intermittent catheterisation is small but nevertheless present. The infection usually affects the lower tract and is easily treated with a course of antibiotics. However, in a patient with an artificial device, any episode of infection, however innocuous, greatly puts the AUS at risk of being infected.

<sup>1</sup> Section of Urology, Department of General Surgery  
Tan Tock Seng Hospital, Singapore

Address for Reprints: Dr KL Toh, Section of Urology, Department of General Surgery, Tan Tock Seng Hospital, 11 Jalan Tan Tock Seng, Singapore 308433.  
Email: khai\_lee\_toh@ttsh.com.sg

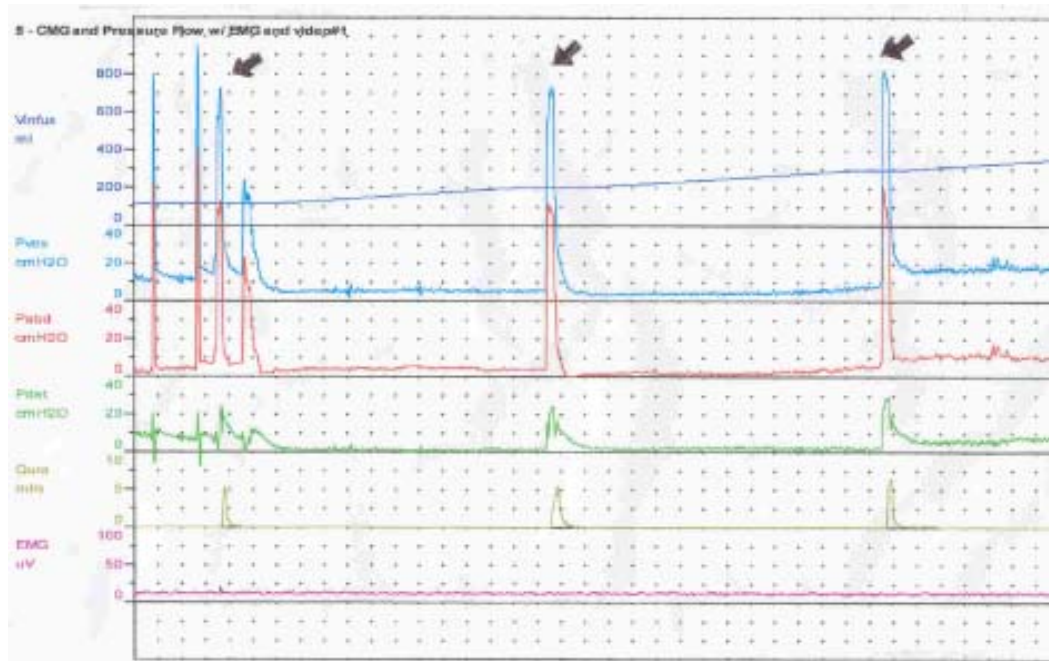


Fig. 1. Multichannel urodynamic tracing demonstrating stress urinary incontinence. The patient leaked urine when performing Valsalva manoeuvres (see arrows).

An infected device renders the AUS non-functional and is an absolute indication for removal.

In addition, repeated urinary catheterisation heightens the risk of device erosion into the urethra. Catheterisation, even in skilful hands, invariably causes some trauma, albeit minor, to the urethra. Furthermore, the nature of urethral trauma encountered in a programme of clean intermittent catheterisation is repetitive. This is borne out by the experience of patients with bulbar urethral cuffs. Forceful catheterisation without first deactivating the device is a major cause of device erosion,<sup>2</sup> resulting in the need for device removal. It is thus an absolute necessity to deactivate the cuff before commencing catheterisation, a procedure which the patient must faithfully follow before each catheterisation. This manoeuvre requires a dextrous patient and only certain patients with spinal cord injuries are able to accomplish this.

The cuff component of the AUS can either be implanted at the bladder neck or along the urethra. The bladder neck has greater tissue bulk compared to the urethra and hence carries a lower rate of device erosion and subcuff tissue atrophy, while not affecting continence results. Thus it is the preferred site for cuff implantation for those with intact anatomy. However, this is not a viable option for adults with post-radical prostatectomy incontinence. The cuff is, in such instances, implanted along the length of the urethra, usually at the bulbar urethra. On the other hand, adults with neurogenic voiding dysfunction have an intact bladder neck, thus allowing for cuff implantation.

Alternative treatment options such as the male sling as well as transurethral injection of bulking agents have been used in males with stress urinary incontinence. However, they are used primarily for male patients with post-prostatectomy incontinence. Little is known about their efficacy in patients with neurogenic stress incontinence. In addition, the durability of these treatment options is not known.

In contrast, an 86% continence rate can be achieved using the AUS over the long term. Mechanical failure and the need for revision surgery range from 30% to 64% and 16% to 35%, respectively. Drawing on long-term experience in children who have bladder neck AUS and are performing intermittent catheterisation, the incidence of urinary tract infection, device infection and erosion is small.<sup>2,3</sup> Long-term data support the AUS as being durable and probably the most appropriate means of achieving continence for such patients.

#### REFERENCES

1. Scott FB, Bradley WE, Timm GW. Treatment of urinary incontinence by an implantable prosthetic urinary sphincter. *J Urol* 1974;112:75-8.
2. Elliott DS, Barrett DM. Mayo Clinic long-term analysis of the functional durability of the AMS 800 artificial urinary sphincter: a review of 323 cases. *J Urol* 1998;159:1206-8.
3. Herndon CD, Rink RC, Shaw MB, Simmons GR, Cain MP, Kaefer M, et al. The Indiana experience with artificial urinary sphincters in children and young adults. *J Urol* 2003;169:650-4.