

Caesarean Scar Pregnancy: A Diagnosis to Consider Carefully in Patients with Risk Factors

G Tan,¹MBBS, MRCOG, M Med (O & G), YS Chong,¹MBBS, M Med (O & G), MRACOG, A Biswas,¹MBBS, FRCOG, MD

Abstract

Introduction: Caesarean scar pregnancy is rare. A high index of suspicion is necessary to make the right diagnosis early. **Clinical Picture:** Two women, each with a history of 1 previous caesarean delivery, were initially diagnosed with spontaneous abortion in progress when ultrasonography scan revealed the gestational sac to be in the lower uterine cavity. Subsequent ultrasound scans showed that the gestational sac was actually in the anterior uterine wall at the level of the uterine isthmus. **Treatment:** Both women were managed successfully with intrasac methotrexate injection. **Outcome:** We report 2 cases of caesarean scar pregnancies mistaken for spontaneous abortions by experienced ultrasonographers. **Conclusion:** This highlights the difficulty in differentiating between these 2 diagnoses and the importance of having a high index of suspicion in women with risk factors.

Ann Acad Med Singapore 2005;34:216-9

Key words: Abortion, Early diagnosis, Ectopic, Pregnancy, Spontaneous

Introduction

A uterine scar pregnancy is a gestation separated from the endometrial cavity and completely surrounded by the myometrium and the fibrous tissue of the scar. The most probable mechanism through which this can occur is invasion of the myometrium through a microscopic tract. The tract is believed to develop from trauma from previous uterine surgeries like dilatation and curettage, myomectomy, metroplasty and caesarean section (Fig. 1).¹⁻³

Although implantation of a pregnancy within the scar of a previous caesarean section is the rarest form of ectopic pregnancy,⁴ it is important to consider this possibility in patients with the above-mentioned risk factors. This is because early diagnosis with an ultrasound scan can offer treatment options capable of avoiding uterine rupture and haemorrhage, and hence preserve the uterus. When the gestational sac is seen in the lower part of the uterine cavity, it can be difficult to differentiate between spontaneous abortion in progress, cervico-isthmic pregnancy and caesarean scar pregnancy. This can be seen in our 2 patients. A high index of suspicion is, therefore, necessary.

Case Reports

Case 1

A 35-year-old gravida 5 para 1 presented to our department at 7 weeks and 2 days of amenorrhoea for painless per-vaginal bleeding. She had had a caesarean section for no progress in labour in her first pregnancy 4 years ago. This was followed by 2 first-trimester termination of pregnancies and 1 missed abortion at 8 weeks, for which an evacuation of uterus was done. She was haemodynamically stable. Vaginal examination revealed a closed cervical os, 6 weeks' size uterus and no adnexal tenderness. Transvaginal ultrasound scan revealed a small, irregular sac low in the uterine cavity (Fig. 2). There was no adnexal mass or fluid in the Pouch of Douglas. A diagnosis of spontaneous abortion in progress was made. Serum beta-hcG was 2134 IU/L. The patient opted for expectant management and was advised to return earlier if she developed per-vaginal bleeding or abdominal pain.

She was asymptomatic at a review 10 days later. Serum beta-hcG had dropped to 587 IU/L. The transvaginal ultrasound scan showed a gestational sac with a fetal pole in the anterior uterine wall at the isthmus. The sac measured

¹ Department of Obstetrics and Gynaecology
National University of Hospital, Singapore

Address for Reprints: Dr Geraldine Tan, Department of Obstetrics and Gynaecology, National University Hospital, 5 Lower Kent Ridge Road, Singapore 119074.
Email: geraldinetpl@pacific.net.sg

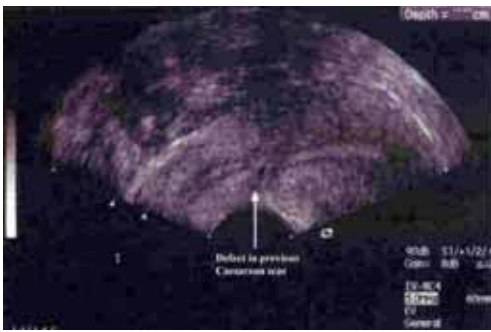


Fig. 1.

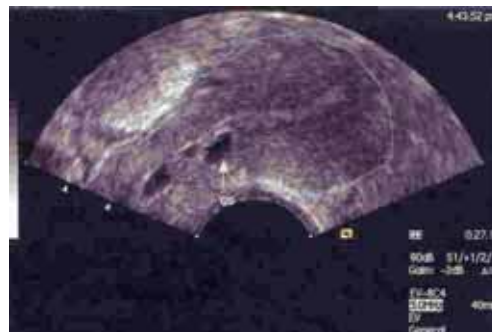


Fig. 2.

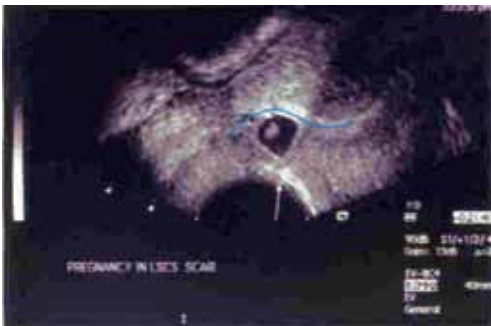


Fig. 3.

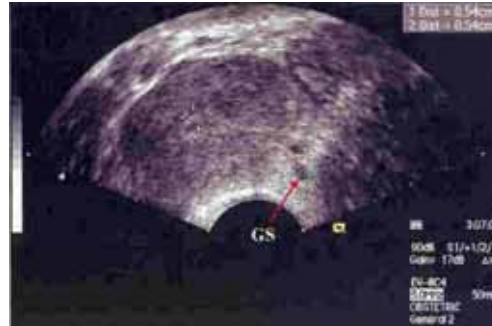

Fig. 4.

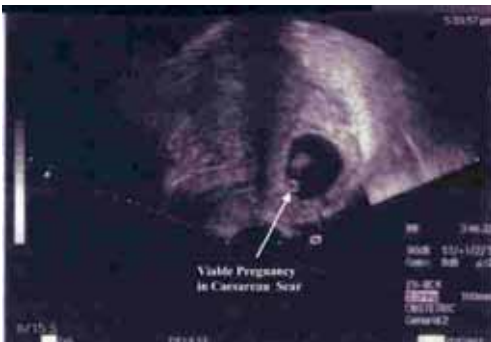


Fig. 5.

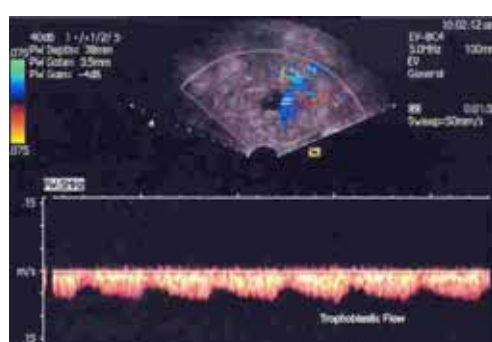


Fig. 6.

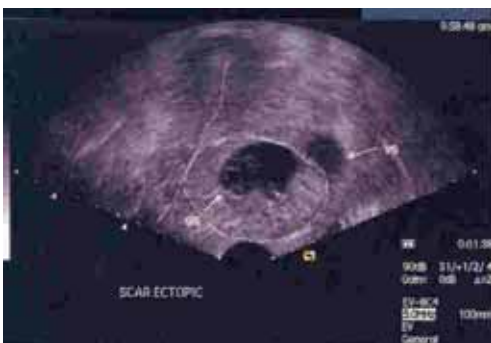

Fig. 7.

Fig. 1. Transvaginal scan of patient with a previous caesarean section showing a defect in the anterior uterine wall at the level of the isthmus, the presumed site of the caesarean scar.

Fig. 2. Transvaginal scan of case 1 shows the gestational sac (arrow) at the level of the uterine isthmus.

Fig. 3. Transvaginal scan of case 1 shows a gestational sac (arrow) with fetal pole outside the lower uterine cavity at the level of the isthmus in the anterior uterine wall.

Fig. 4. Transvaginal scan of case 1 on shows marked decrease in size of the gestational sac (arrow) in the caesarean scar.

Fig. 5. Transvaginal scan of case 2 shows the gestational sac with yolk sac (thick arrow) and viable fetus (thin arrow) at the level of the uterine isthmus in the anterior uterine wall.

Fig. 6. Transvaginal scan of case 2 shows the trophoblastic flow around the gestational sac in the caesarean scar.

Fig. 7. Transvaginal scan of case 2 shows the large venous sinus (arrow) at the periphery of the gestational sac in the caesarean scar.

10 mm in diameter while the crown-rump length was 6 mm. No fetal heart activity was seen. There was increased vascularity and trophoblastic flow around the sac (Fig. 3). The diagnosis was revised to that of a caesarean scar ectopic pregnancy. The patient was counselled about the diagnosis. A decision was made to proceed with transvaginal ultrasound-guided aspiration of the sac with a 20G spinal needle followed by intrasac injection of 50 mg of methotrexate.

On day 5 post-treatment, the transvaginal ultrasound scan showed an empty gestation sac 8 mm by 8 mm with trophoblastic flow still seen. Serum beta-hcG had dropped to 27.6 IU/L. A repeat ultrasound scan on day 12 showed that the sac had slightly increased in size (10 mm by 8 mm) and there was a secondary rise in serum beta-hcG to 79.8 IU/L. After discussion with the patient, an intramuscular injection of methotrexate 70 mg was given. A transvaginal ultrasound scan on day 19 showed a decrease in sac size, but trophoblastic flow was demonstrable. Serum beta-hcG dropped to 4.3 IU/L. On day 33, a transvaginal ultrasound scan showed a further decrease in sac size (5.8 mm by 3.3 mm) (Fig. 4). This time, trophoblastic flow was absent and there was no increased vascularity around the sac. Serum beta-hcG was <2.5 IU/L. Her periods returned spontaneously on day 36 after initial treatment and she has been having regular monthly menses since.

Case 2

A 39-year-old gravida 2 para 1, with a history of caesarean section for breech presentation 1 year ago, came to our department for a second opinion. She had been seen 2 weeks ago by her gynaecologist for per-vaginal bleeding at 8 weeks of amenorrhoea. She was told that the gestational sac was in the lower uterine cavity and was warned of a possible miscarriage. She was asymptomatic when she first presented to our department. Clinical examination was unremarkable. Transvaginal and transabdominal ultrasound scans revealed a gestational sac with a viable fetus equivalent to 8 weeks' gestation in the anterior uterine wall at the level of the isthmus close to the surface (Fig. 5). The uterine cavity was empty and there was no fluid in the Pouch of Douglas. Increased vascularity was noted around the sac (Fig. 6). A diagnosis of a viable caesarean scar pregnancy was made. An intracardiac injection of 5 mL of 7.45% potassium chloride was given to the fetus under transvaginal ultrasound guidance followed by aspiration of sac contents and intrasac injection of 50 mg methotrexate.

A repeat transvaginal ultrasound scan done on day 2 post-treatment showed an absence of fetal heart activity. Serum beta-hcG before treatment was 186,643 IU/L and this fell steadily. A repeat transvaginal ultrasound scan on day 48 showed a large venous sinus around the sac (Fig. 7);

serum beta-hcG was 649 IU/L. The decision was made for intramuscular injection of methotrexate in an attempt to decrease the vascularity around the sac. On day 55, the vascularity around the sac was markedly reduced and serum beta hcG had dropped to 300 IU/L; day 69, the patient was well and serum beta-hcG had dropped to 4.3 IU/L.

Discussion

The caesarean scar pregnancy is the rarest form of ectopic pregnancy. However, with the rising rate of caesarean deliveries all over the world, it is probable that the incidence may increase. Thus, it is important to have a high index of suspicion in patients with risk factors. When the gestational sac is seen in the lower part of the uterine cavity, the differential diagnosis between spontaneous abortion in progress, cervico-isthmic pregnancy and caesarean scar pregnancy can be difficult. If the gestational sac is found at the level of the uterine isthmus in a patient with a previous caesarean section, it is important to consider the possibility of a caesarean scar pregnancy, especially when the cervical os is closed.

Transvaginal ultrasonography combined with Doppler is a reliable tool for diagnosis. Ultrasound imaging criteria to diagnose caesarean scar pregnancy are as follows:

- 1) empty uterine cavity and cervical canal;
- 2) development of the gestational sac in the anterior uterine wall at the isthmus (presumed site of the previous lower segment caesarean section scar);
- 3) evidence of functional trophoblastic circulation on Doppler examination, defined by the presence of an area of increased peritrophoblastic vascularity on colour Doppler examination;⁵ and
- 4) the absence of healthy myometrium between the bladder and sac, allowing differentiation from cervico-isthmic implantation.⁶

In cases of spontaneous abortion in progress, the gestational sac should be seen in the cervical canal on transvaginal scan and the sac should appear avascular, reflecting the fact that the sac has been detached from its implantation site, whereas in caesarean scar pregnancies, the gestational sac would appear well-perfused and would be located in the anterior uterine wall at the isthmus. With early diagnosis, treatment can be initiated promptly, thus decreasing the likelihood of uterine rupture and haemorrhage.

There are no universal treatment guidelines for caesarean scar pregnancy, owing to its rarity. As both our patients were stable and asymptomatic, medical treatment was chosen after discussion with them. Transvaginal ultrasound-guided injections of methotrexate were given to both

patients after aspiration of sac contents. The reason we chose this method was because we agreed with the rationale given by Godin et al,⁶ who reported the first case of caesarean scar pregnancy successfully treated by this route. It seemed logical that the caesarean scar pregnancy, being surrounded by fibrous scar rather than normally vascularised myometrium, would have limited systemic access. Thus, direct injection of methotrexate would probably be more effective. Most other case reports involving conservative management have used methotrexate either systemically or by direct injection into the pregnancy sac, or a combination of both. In one case report, uterine artery embolisation – in addition to methotrexate⁴ – was used, but laparotomy and hysterectomy were subsequently required.

The first patient responded well after initial local injection of methotrexate, with serum beta-hcG levels dropping to as low as 27.6 IU/L within 7 days post-treatment. However, a secondary rise to 79.8 IU/L was noted on day 14 post-treatment. Hence, the decision to give intramuscular methotrexate. Serum beta-hcG dropped to 4.3 IU/L on day 21 and <2.5 IU/L on day 33 after initial treatment. A single dose of intramuscular methotrexate may be a useful treatment option to consider in cases where there is secondary rise in serum beta-hcG, as long as the patient is asymptomatic.

Conclusion

Thus far, there is no comparison of the interval between previous caesarean delivery and the occurrence of caesarean

scar pregnancy. It would be interesting to find out whether there is a possible association, such as whether caesarean scar pregnancies are more likely to occur if the previous caesarean section was recently done, perhaps due to inadequate healing leading to a defect in the scar. This may form the basis for advising women on the spacing of subsequent pregnancies after a caesarean delivery.

Fortunately, for our patients, the right diagnosis was made after initially being mistaken for spontaneous abortion in progress without catastrophic consequence. Both cases highlight the difficulty in differentiating between the 2 diagnoses and, hence, the importance of having a high index of suspicion in women with risk factors.

REFERENCES

1. Miller DA, Chollet JA, Goodwin TM. Clinical risk factors for placenta praevia-placenta accreta. *Am J Obstet Gynecol* 1997;177:210-4.
2. McGowan L. Intramural pregnancy. *JAMA* 1965;192:637-8.
3. Fait G, Goyert G, Sundareson A, Pickens A Jr. Intramural pregnancy with foetal survival: case history and discussion of etiologic factors. *Obstet Gynecol* 1987;70(3 Pt 2):472-4.
4. Fylstra DL. Ectopic pregnancy within a caesarean scar: a review. *Obstet Gynecol Surv* 2002;57:537-43.
5. Jurkovic D, Hillaby K, Woelfer B, Lawrence A, Salim R, Elson CJ. First-trimester diagnosis and management of pregnancies implanted into the lower uterine segment Caesarean section scar. *Ultrasound Obstet Gynecol* 2003;21:220-7.
6. Godin PA, Bassil S, Donnez J. An ectopic pregnancy developing in a previous caesarean section scar. *Fertil Steril* 1997;67:398-400.