

## Pancreas-only Metastasis from Nasopharyngeal Carcinoma

Dear Editor,

A 51-year-old Chinese man presented with a 3 month's history of left cervical lymphadenopathy, rhinorrhoea, tinnitus and nasal congestion. On nasopharyngoscopy, a fungating mass was found in his nasopharynx and was biopsied. Histopathological examination revealed an undifferentiated, non-keratinising carcinoma of the nasopharynx (WHO III). A biopsy of the left cervical lymph nodes showed a similar pathological finding of metastatic undifferentiated carcinoma. A computed tomographic (CT) scan of the head and neck showed a large left nasopharyngeal mass which extended across the midline, laterally and inferiorly towards the deep lobe of the left parotid gland. There was early erosion of the left pterygoid plate (T3) and encasement of the left internal carotid artery but no signs of intracranial invasion. There was bilateral cervical lymphadenopathy measuring up to 5 cm (N2) deep to both right and left sternomastoid muscles. A triphasic CT scan of the abdomen revealed a 3.0 x 2.3 cm pancreatic lesion (arrow, Fig. 1A) in the superior aspect of the neck of the pancreas with a few enlarged lymph nodes around the pancreatic head, one of which had a necrotic centre. These findings were suggestive of malignancy. Several liver cysts and hemangiomas were also present. Bone scan showed negative results. To further evaluate the pancreatic lesion, an endoscopic ultrasound (EUS) was performed which confirmed a 2.5 cm inhomogeneous hypoechoic mass (MASS) at the pancreatic genu/neck adjacent to the portal confluence (PC) and splenic vein (SV) (Fig. 1B). There was a hypoechoic lymph node adjacent to the pancreatic body and multiple enlarged lymph nodes adjacent to the pancreatic head. EUS-guided fine needle aspirate (EUS-FNA) of 2 lymph nodes adjacent to the pancreatic head; one of which measured 3.3 x 2.4 cm containing areas of cystic degeneration, yielded smears and cell blocks with malignant cells consisting of metastatic non-keratinising, undifferentiated carcinoma with morphological similarity to the tumour in the previous nasopharyngeal and cervical lymph nodes biopsy specimens. Sampling of the peri-pancreatic lymph nodes instead of the pancreatic lesion was performed in order to optimise assessment of locoregional disease extent should curative surgery be required for a possible primary pancreatic carcinoma. According to the American Joint Committee on Cancer (AJCC) Staging, this was a Stage IVC nasopharyngeal carcinoma (NPC). The patient is currently undergoing palliative chemotherapy with cisplatin and infusional 5-fluorouracil every 4 weeks with good

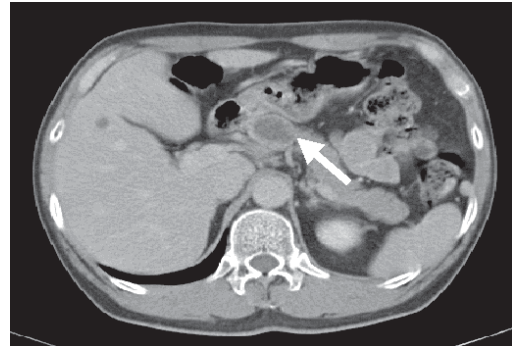


Fig. 1A. Triphasic CT scan abdomen showing a 3.0 x 2.3 cm pancreatic lesion (arrow).

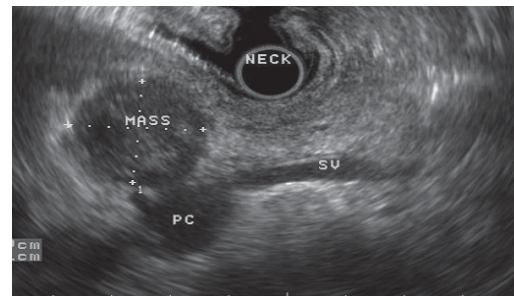


Fig. 1B. Endoscopic ultrasound (EUS) showing a 2.5 cm hypoechoic mass (MASS) at the pancreatic genu/neck adjacent to the portal confluence (PC) and splenic vein (SV).

response so far as evidenced by a decrease in size of the pancreatic lesion (measuring 1.4 x 1.7 cm) on CT scan after 2 cycles of chemotherapy.

NPC is a malignancy which is endemic in southern China, Southeast Asia, and the Mediterranean basin. In Singapore, NPC is the sixth most common cancer among Chinese males with an age-standardised rate of 12.5 per 100,000 per year.<sup>1</sup> Here, the incidence of NPC peaks between 40-65 years with 83.2% of all histological types comprising an undifferentiated carcinoma.<sup>1</sup> Aetiologic factors include a genetically determined susceptibility in some individuals, an early-age exposure to chemical carcinogens, particularly the Cantonese salted fish, and an association with a latent Epstein-Barr virus (EBV) infection. The typical presenting features of NPC include a neck mass, nasal obstruction with bloody discharge, and conduction hearing loss or serous otitis.<sup>2</sup> More than 90% of patients present with locally and/or regionally advanced disease including involvement of the oropharynx (15%), nasal cavity (20%), parapharyngeal space (80%), retropharyngeal and cervical lymph nodes, neighbouring bony structures including the base of skull (25% to 35%), and cranial nerves (15% to 20%).<sup>2,3</sup> Advanced locoregional

and nodal disease is strongly correlated with poor prognosis and a high incidence of metastatic disease.

Distant spread is higher among NPC than most other head and neck squamous cell carcinomas. The most frequently involved sites are the bones (70-80% of patients), followed by the lung, then the liver, and lastly the extra-regional nodes (axillary, mediastinal, pelvic and inguinal).<sup>2</sup> The liver has an incidence of metastasis of 29.3% to 36% and solitary liver and splenic metastases have been reported recently.<sup>4-7</sup> However, solitary pancreatic or pancreas-only metastases from primary NPC have not been described in the literature so far. Two per cent of all malignant pancreatic tumours are metastases from other primaries with lung, colorectal, breast, and hematological neoplasms being the most common.<sup>8</sup> However, renal cell carcinoma is the most common primary leading to solitary pancreatic metastasis and has been well described.<sup>8</sup> Other reported primary tumour sites presenting as solitary pancreatic masses include the stomach, ovary, malignant melanoma, duodenum, oesophagus, uterus, salivary gland, bone, testis, prostate, medulloblastoma and meningioma of the brain.<sup>9</sup>

Our patient was diagnosed with NPC and a solitary pancreatic lesion with peripancreatic lymphadenopathy, for which biopsy was required to differentiate primary and secondary pancreatic tumour. EUS has emerged as the preferred method for cytologic-tissue acquisition of suspected pancreatic masses with an acceptably low complication rate. Although surgical resection of pancreatic metastases has been described for renal cell carcinomas, sarcomas, melanomas, colon, breast and lung cancers with good palliation and a trend towards improved survival for renal primaries,<sup>10</sup> its role in this case is not known yet.

#### REFERENCES

1. Seow A, Koh WP, Chia KS, Shi LM, Lee HP, Shanmugaratnam K. Trends in Cancer Incidence in Singapore 1968-2002. Singapore:

Singapore Cancer Registry, 2004. Singapore Cancer Registry Report No. 6.

2. Altun M, Fandi A, Dupuis O, Cvitkovic E, Krajina Z, Eschwege F. Undifferentiated nasopharyngeal cancer (UCNT): current diagnostic and therapeutic aspects. *Int J Radiat Oncol Biol Phys* 1995;32:859-77.
3. Lee AW, Poon YF, Foo W, Law SC, Cheung FK, Chan DK, et al. Retrospective analysis of 5037 patients with nasopharyngeal carcinoma treated during 1976-1985: overall survival and patterns of failure. *Int J Radiat Oncol Biol Phys* 1992;23:261-70.
4. Ahmad A, Stefani S. Distant metastases of nasopharyngeal carcinoma: a study of 256 male patients. *J Surg Oncol* 1986;33:194-7.
5. Khor TH, Tan BC, Chua EJ, Chia KB. Distant metastases in nasopharyngeal carcinoma. *Clin Radiol* 1978;29:27-30.
6. Delis S, Biliatis I, Bourli A, Kapranos N, Derveniz C. Surgical resection of a solitary liver metastasis from nasopharyngeal carcinoma: a case report. *Hepatobiliary Pancreat Dis Int* 2006;5:610-2.
7. Lam KY, Tang V. Metastatic tumors to the spleen: a 25-year clinicopathologic study. *Arch Pathol Lab Med* 2000;124:526-30.
8. David AW, Samuel R, Eapen A, Vyas F, Joseph P, Sitaram V. Pancreatic metastasis from renal cell carcinoma 16 years after nephrectomy: a case report and review of the literature. *Trop Gastroenterol* 2006;27:175-6.
9. Robbins EG, 2nd, Franceschi D, Barkin JS. Solitary metastatic tumors to the pancreas: a case report and review of the literature. *Am J Gastroenterol* 1996;91:2414-7.
10. Crippa S, Angelini C, Mussi C, Bonardi C, Romano F, Sartori P, et al. Surgical treatment of metastatic tumors to the pancreas: a single center experience and review of the literature. *World J Surg* 2006;30:1536-42.

Sing-Huang Tan,<sup>1</sup>MBBS, MRCP (UK),

Alvin SC Wong,<sup>1</sup>MBBS, MRCP (UK),

Thomas P Thamboo,<sup>2</sup>MChB, MRCPath, FRCPA,

Stephen KY Chang,<sup>3</sup>MRCs (Edin), MMed (Surg), FRCS (Edin),

Christopher JL Khor,<sup>4</sup>MBBS, MRCP (UK), FRCP (Edin)

<sup>1</sup> Department of Hematology-Oncology, National University Hospital, Singapore

<sup>2</sup> Department of Pathology, National University Hospital, Singapore

<sup>3</sup> Department of Surgery (Hepatopancreatobiliary), National University Hospital, Singapore

<sup>4</sup> Department of Medicine (Gastroenterology and Hepatology), National University Hospital, Singapore

Address for Correspondence: Dr Sing-Huang Tan, Department of Hematology-Oncology, 5 Lower Kent Ridge Road, National University Hospital, Singapore 119074.

Email: Sing\_Huang\_Tan@nuh.com.sg