

## Laparoscopic Heller's Cardiomyotomy for Achalasia of the Cardia in a Pregnant Patient

Dear Editor,

Laparoscopy was first used for the evaluation of acute abdominal pain in pregnancy by gynaecologists in 1980.<sup>1</sup> The most commonly reported laparoscopic procedure during pregnancy is laparoscopic cholecystectomy.<sup>2</sup> Achalasia of the cardia is an oesophageal motor disorder, whose incidence in pregnancy is not known. As far as we know, there has been no report of laparoscopic Heller's cardiomyotomy performed on a pregnant patient. We report a case of achalasia cardia of a pregnant patient in her second trimester treated adequately and safely with laparoscopic Heller's myotomy.

The patient was a 24-year-old primigravida in her second trimester of pregnancy who presented to us in August 2003 with persistent dysphagia for liquids and solids, occasional vomiting, anaemia, anorexia and weight loss. Endoscopy showed the dilated proximal portion of the oesophagus and a narrowing of the distal oesophagus. Oral contrast study showed a smooth filling defect with "rat tail" deformity, confirming that it was a case of achalasia cardia. She had undergone balloon dilatation twice in the third gestational month but the symptoms recurred. She was then referred to our institution for definitive treatment, so we planned for a surgical intervention. The risk of general anaesthesia and problems associated with surgery were explained to the patient. After the conventional preoperative preparation, the patient was taken for surgery.

The patient was placed in a reverse Trendelenburg position with the legs apart. The chief surgeon stood between the patient's legs; the camera surgeon and the first assistant stood at the right of the patient; the second assistant and the scrub nurse stood to the left of the patient. Pneumoperitoneum was created using the Hasson technique. A 10-mm optic port was placed 3 cm above the umbilicus; a 10-mm right working hand port was placed along the left

midclavicular line, parallel to the umbilicus; a 5-mm left working hand port was placed along the right midclavicular line, parallel to and above the umbilicus. A 5 mm port was placed along the anterior axillary line just below the right subcostal margin for liver retraction. An additional 10-mm port was placed 6 cm lateral to the right hand port for retraction of the stomach using a Babcock grasper. The gravid uterus was seen in the pelvis (Fig. 1A). The abdominal oesophagus was mobilised by separating both the crura from it using ultrasonic shears. The anterior vagus nerve was gently retracted away from the myotomy site. The cardiomyotomy was commenced by cutting the seromuscular layer (Fig. 1B) overlying the narrowed portion of the oesophagus and was extended distally to 3 cm beyond the gastroesophageal junction (GEJ). A dissector and atraumatic grasper were used to gently separate the muscle fibres. The underlying mucosa was seen bulging through the myotomy. The mucosa in the area of the myotomy was checked for leakage by insufflating air in the nasogastric tube with the oesophagus under saline. The lower end of the oesophagus was further mobilised and a "window" was created posterior to the GEJ. The fundus of the stomach was pulled through this window posterior to the oesophagus and wrapped partially around the GE junction.

The total operating time was 115 minutes and there were no intraoperative complications. The patient was put on a liquid diet on the first postoperative day (POD) after removing the nasogastric tube and soft diet on the third POD. She was discharged on the fifth POD. A postoperative gastrograffin study showed a free flow of dye across the diseased segment. Her nutrition improved and she went on to successfully deliver a normal baby. The patient was followed up once a year for 3 years with endoscopy and barium swallow; there was no evidence of recurrence.

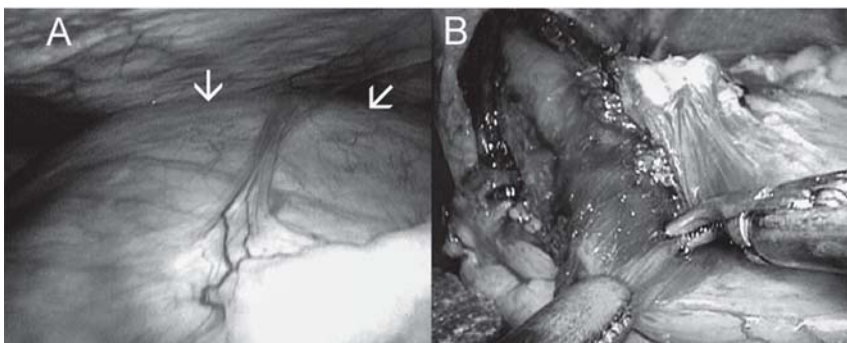


Fig. 1A. The gravid uterus as seen on laparoscopy.  
Fig. 1B. Seromyotomy in progress.

In the past 12 years of our laparoscopic experience, 19 pregnant patients had undergone laparoscopic procedures at our institute for various conditions. In this particular patient, we chose surgical intervention because of the failure of conservative measures. Besides, the patient wanted the surgery as she was malnourished and losing weight, and feared for the health of her unborn child. As we have adequate experience in performing laparoscopic procedures in pregnant patients, there should not be any technical difficulty when performing laparoscopic Heller's cardiomyotomy in non-pregnant patients. Care was taken not to touch or handle the gravid uterus at any time and ultrasonic shears were used for all the dissections to avoid excessive smoke. Nasogastric tube suction and strict airway management were maintained to prevent aspiration into the lungs. Extra care was taken when changing sharp instruments to avoid injury of the enlarged uterus. Several studies of laparoscopic oesophageal myotomy with partial fundoplication have been reported in non-pregnant patients, with a success rate of 88% to 98%.<sup>3</sup> Physiologic and anatomic changes introduce certain risks unique to the gravid patient, some inherent to laparoscopy. These risks have been postulated to include poor visualisation due to gravid uterus, uterine injury during trocar placement or Veress needle insertion, technical difficulty of laparoscopic surgery, decreased uterine blood flow, hypothetical, premature labour from the increased intra-abdominal pressure, increased fetal acidosis or other unknown effects of CO<sub>2</sub> pneumoperitoneum.<sup>4</sup> Ideally, surgery should be done in the second trimester, because the risk of teratogenesis, preterm delivery and miscarriage is lowest in this trimester. All surgeries performed in pregnant patients are technically similar to those performed in non-pregnant patients, the only difference being the extra precautions that have to be taken in pregnant patients. Laparoscopic procedures performed during pregnancy have their advantages, particularly in upper abdominal conditions in which visualisation and accessibility are not compromised by the expanding uterus.<sup>5</sup>

Even though laparoscopic Heller's myotomy is now common, the novelty of this case is the fact that the patient was pregnant. The patient's symptoms could have easily been attributed to the pregnancy itself, so it would be prudent for the surgeon to rule out other causes.

To summarise, laparoscopic surgery has the advantage of allowing reduced narcotic use and hence less fetal depression, better intraoperative visualisation and exposure, less postoperative pain, more rapid maternal recovery and diminished postoperative maternal hypoventilation. It can be concluded that laparoscopic surgery is feasible and safe, even for pregnant patients.

#### REFERENCES

1. Bisharah M, Tulandi T. Laparoscopic surgery in pregnancy. *Clin Obstet Gynecol* 2003;46:92-7.
2. Lachman E, Schienfeld A, Voss E, Gino G, Boldes R, Levine S, et al. Pregnancy and laparoscopic surgery. *J Am Assoc Gynecol Laparosc* 1999;6:347-51.
3. Hunter JG, Trus TL, Branum GD, Waring JP. Laparoscopic Heller myotomy and fundoplication for achalasia. *Ann Surg* 1997;225:655-64.
4. Curet MJ, Allen D, Josloff RK, Pitcher DE, Curet LB, Miscall BG, et al. Laparoscopy during pregnancy. *Arch Surg* 1996;131:546-50.
5. Stepp K, Falcone T. Laparoscopy in the second trimester of pregnancy. *Obstet Gynecol Clin North Am* 2004;31:485-96.

Chinnusamy Palanivelu,<sup>1</sup>*MCh, FRCS, FACS,*  
Muthukumaran Rangarajan,<sup>1</sup>*MS, DipMIS, FACS,*  
Gobi Shanmugam Maheshkumar,<sup>1</sup>*MS,*  
Ramakrishnan Parthasarathi,<sup>1</sup>*MBBS*

<sup>1</sup> Department of Surgical Gastroenterology  
GEM Hospital and Postgraduate Institute, India

Address for Correspondence: Dr M Rangarajan, GEM Hospital and Postgraduate Institute, 45-A, Pankaja Mill Road, Ramnathapuram, Coimbatore – 641045, India. Email: rangy68@gmail.com