

Pathological Pulmonary Hernia in a Patient With Metastatic Breast Cancer[†]

Aleksandra Pirjavec,^{1MD}, Ileana Lulic,^{2MD}, Ivor Kovic,^{2MD}, Marko Zelic,^{1MD}

Abstract

Introduction: Pathological pulmonary hernia is a rare clinical entity which can be caused by malignancies. **Clinical Picture:** A 72-year-old female presented with a painful bulge in the left 4th intercostal space. Chest radiography and computed tomography demonstrated a left pulmonary hernia, pleural effusion and destruction of ribs. **Treatment:** The hernia sac was excised and a part of the chest wall was resected with reconstruction of residual defect. **Outcome:** The patient died 2 years after the treatment. **Conclusions:** A multidisciplinary approach involving various medical specialists may offer patients with pathological pulmonary hernia remarkable palliation and better quality of life.

Ann Acad Med Singapore 2008;37:234-5

Key words: Palliative care, Surgical flaps, Surgical mesh

Introduction

Pulmonary hernia is a rare and uncommon clinical entity that has been defined as a protrusion of pleural membranes or lung parenchyma through the defect in the thoracic enclosure.¹ According to aetiology, pulmonary hernias can be congenital (due to rib or intercostal hypoplasia or agenesis) or acquired (traumatic, pathological or spontaneous).² Among acquired pulmonary hernias, the least common are pathological hernias, which occur because of defects in the chest wall resulting from empyema, osteomyelitis, carcinoma, or other causes.³ We present a case of a pathological pulmonary hernia in a patient with metastatic breast cancer.

Case Report

A 72-year-old female presented with a painful bulge in the left anterior chest wall and symptoms of severe dyspnoea. Four years before admission, she had a left mastectomy due to breast cancer which was pathologically identified as an invasive ductal carcinoma, grade III. The patient underwent chemotherapy and radiotherapy after the mastectomy. The treatment was successful and there was no apparent evidence of disease, so the patient was discharged with instructions to attend regular follow-up examination. Three years after the mastectomy, the patient noticed an expiratory bulging in the left side of the chest after cough, which was painful on pressure. She was then admitted to the Department of

Pulmonology where the recurrence of the primary disease was discovered. The patient received new cycles of chemotherapy. During chemotherapy, the left chest wall bulge increased in size and subsequently led to a decreased pulmonary function.

On admission, physical examination revealed a painful and constant oblong bulge containing liquid, 20 x 10 cm in size, in the left 4th intercostal space. The bulge was reducible on direct pressure and after reduction, a defect of the thoracic wall could be palpated. The initial chest X-ray and computed tomography (CT) demonstrated a left pulmonary hernia, pleural effusion and destruction of the 4th and 5th rib. Fine needle aspiration was performed and the cytological examination revealed carcinoma cells.

The progression of symptoms mandated an immediate surgical intervention. During surgery, the hernia sac was excised and the affected part of the chest wall was resected (Fig. 1). The residual defect was repaired by the interposition of a polypropylene clear mesh sheet (Surgipro Mesh, USA Corp., Norwalk, Connecticut) covered by myocutaneous latissimus dorsi flap (Fig. 2). The postoperative recovery was uneventful. The thoracic drain was removed on the 6th postoperative day without wound infection and on the 11th postoperative day, the patient was discharged with a satisfactory outcome (Fig. 3). After surgery, the patient continued adjuvant chemotherapy. The treatment enabled

¹ Department of Surgery, Clinical Hospital Center Rijeka, Rijeka, Croatia

² Clinical Hospital Center Rijeka, Rijeka, Croatia

Address for Correspondence: Dr Aleksandra Pirjavec, Klinicki Bolnicki Centar Rijeka, Klinika za kirurgiju, Odjel plasticne i rekonstruktivne kirurgije, Krešimirova 42, 51 000 Rijeka, Croatia.

Email: aleksandra.pirjavec@gmail.com

[†] Authors would like to thank the recently deceased Professor Duje Vukas,^{MD, PhD} for his mentorship, inspiration and support

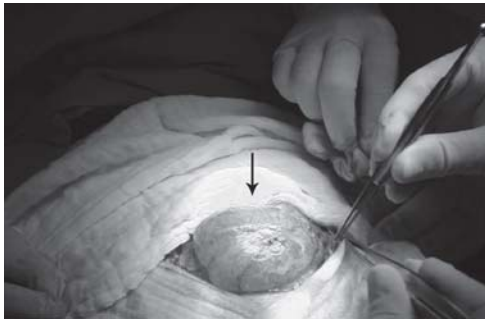


Fig. 1. Intraoperative view of the pulmonary hernia before excision, protruding through the left chest wall (arrow).

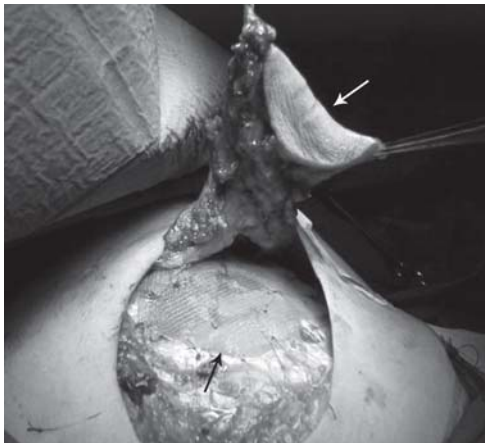

Fig. 2. Reconstruction of the residual chest wall defect with polypropylene mesh sheet under tension (black arrow) and myocutaneous latissimus dorsi flap rotation (white arrow).

the patient to have a better quality of life (QoL). She died 2 years after the surgery.

Discussion

Pulmonary hernia is a rare entity first described by Roland in 1499.⁴ One of the first, and still used, classifications of pulmonary herniation was given by Morel-Lavallee in 1847.⁵ He divided pulmonary hernias by aetiology – congenital or acquired – the latter of which is subdivided into traumatic, spontaneous, or pathological categories.

Pulmonary hernia patients may present with elastic, usually replaceable, swelling in the chest wall, which increases in size during inspiration, coughing and Valsalva manoeuvre. Standard chest X-ray can usually prove the diagnosis, but results can also be misleading, which is why oblique or tangential views are recommended.² More precise information about hernia location and size is provided by CT of the chest, the diagnostic procedure of choice.

Treatment of pulmonary hernias depends largely on whether they present as symptomatic or asymptomatic. Some authors advocate routine surgical treatment for all hernias,⁶ but generally, only symptomatic hernias are treated surgically, while asymptomatic ones are treated

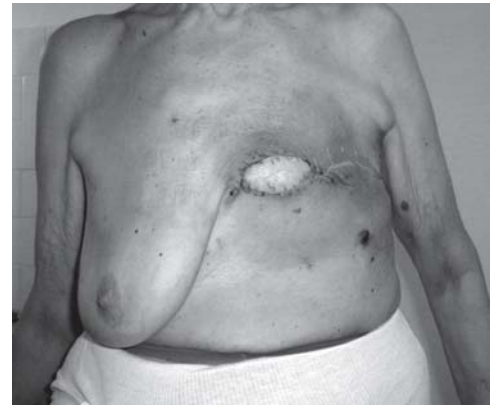

Fig. 3. Postoperative anterior view of the patient demonstrating stability, water and airtight closure, and acceptable appearance of the chest wall.

conservatively, with cough suppression or other simple palliative measures.⁷ Symptomatic hernias presenting with pain and deteriorated pulmonary function, such as the one described in our case report, can benefit substantially from surgical intervention.

Due to the progress in anaesthesia, intensive care, antisepsis and tissue transfer techniques, major chest wall defects can be successfully treated with low mortality. Large defects require reconstructions with prosthetic materials in order to maintain the geometry of the thoracic cage and to achieve sufficient stabilisation.⁸ The goal of reconstruction is stability, water and airtight closure, and acceptable cosmetic appearance. The regional pedicled muscle flap is usually the first choice for soft tissue coverage of a chest wall defect.⁹

Many patients with chest wall malignancies are not within the scope of curative surgical treatment. Such patients may be candidates for palliative resection and reconstruction. Long-term survival in metastatic breast cancer patients is poor, but a combined multidisciplinary approach involving general and thoracic surgeons, plastic and reconstructive surgeons, and intensive care specialists may offer them remarkable palliation and better QoL.

REFERENCES

1. Bhalla M, Leitman BS, Forcade C, Stern E, Naidich DP, McCauley DI. Lung hernia: radiographic features. *AJR Am J Roentgenol* 1990;154: 51-3.
2. Forty J, Wells FC. Traumatic intercostal pulmonary hernia. *Ann Thorac Surg* 1990;49:670-1.
3. Weissberg D, Refaely Y. Hernia of the lung. *Ann Thorac Surg* 2002;74:1963-6.
4. Montgomery JG, Lutz H. Hernia of the lung. *Ann Surg* 1925;82:220-31.
5. Ross RT, Burnett CM. Atraumatic lung hernia. *Ann Thorac Surg* 1999;67:1496-7.
6. Munnell ER. Herniation of the lung. *Ann Thorac Surg* 1968;5:204-12.
7. Sonett JR, O'Shea MA, Caushaj PF, Kulkarni MG, Sandstrom SH. Hernia of the lung: case report and literature review. *Ir J Med Sci* 1994;163:410-2.
8. Lampl L. Chestwall resection: a new and simple method for stabilization of extended defects. *Eur J Cardiothorac Surg* 2001;20:669-73.
9. Tukiainen E, Popov P, Asko-Seljavaara S. Microvascular reconstructions of full-thickness oncological chest wall defects. *Ann Surg* 2003;238: 794-801.