

Local Experience of Endorectal Magnetic Resonance Imaging of Prostate with Correlation to Radical Prostatectomy Specimens

Judy SP Tan,¹MBBS, FRCR, MMed (Diag Radiol), Choon Hua Thng,²MBBS, FRCR, FAMS, Puay Hoon Tan,³MBBS, FRCPA, Christopher WS Cheng,⁴FRCS (Edin), FRCS (Glas), MMed (Surg), Weber KO Lau,⁴MBBS, FRCS (Edin), FRCR (Glas), Terence WK Tan,⁵MBBS, FRCR, FAMS, Juliana TS Ho,²MBBS, FRCR, Boon Chye Ching,²MBBS, FRCR, MMed (Diag Radiol)

Abstract

Introduction: We evaluated the accuracy of endorectal magnetic resonance imaging (MRI) in the staging of prostate cancer. **Materials and Methods:** We retrospectively reviewed 32 patients who underwent endorectal MR prostate prior to radical prostatectomy. The tumour stage based on MR imaging was compared with the pathologic stage. The sensitivity and specificity of endorectal MR prostate in the evaluation of extracapsular extension (ECE) of the tumour were then determined. **Results:** MR correctly diagnosed 17 cases of organ-confined prostate carcinoma and 2 cases of locally advanced disease. In the evaluation of ECE, endorectal MR achieved a high specificity of 94.4%, low sensitivity of 14.3% and moderate accuracy of 59.4%. **Conclusion:** Endorectal MR prostate has high specificity for the detection of ECE. It is useful in the local staging of prostate cancer in patients with intermediate risk as this helps to ensure that few patients will be deprived of potentially curative surgery.

Ann Acad Med Singapore 2008;37:40-3

Key words: Neoplasm staging, Prostatic neoplasms, Prostate-specific antigen

Introduction

Prostate cancer ranks among the top 10 cancers in Singapore.¹ The incidence of prostate cancer has risen by 5% to 118% in most Asian countries.² In the evaluation of patients with prostate cancer, the most important factor affecting a patient's prognosis and choice of treatment regime is disease stage at the time of diagnosis.³ Tumour, nodes, metastasis (TNM) staging of prostate cancer depends on the presence or absence of extraprostatic extension on histopathology. Current clinical staging of prostate cancer is based on Partin's nomogram^{4,5} and predicts the pathological stage based on the 3 variables of prostate-specific antigen (PSA), Gleason's score and digital rectal examination for extraprostatic extension. These 3 clinical variables have been used to develop treatment risk groups^{6,7} and pre-treatment nomograms to predict treatment failure after radical prostatectomy or radiation therapy.^{8,9} Although magnetic resonance imaging (MRI) is the best modality for visualising local extension, it has poor sensitivity for the

detection of microscopic spread and only has a role in patients with intermediate risk based on Partin's nomogram.

It is therefore important for magnetic resonance (MR) staging of prostate cancer to achieve high specificity even at the expense of a decreased sensitivity, in order to avoid denying patients potentially curative radical prostatectomies.¹⁰ We have previously reported our experience with pelvic phased array MR prostate and had achieved a relatively high specificity.¹¹ We now undertake this study to evaluate our experience with endorectal coil MR of prostate.

Materials and Methods

This is a retrospective study. Between 1 January 2001 and 30 June 2005, 139 patients underwent endorectal MR prostate studies. Out of these 139 patients, 32 patients eventually underwent radical prostatectomy. These 32 patients form the study population from whose medical records, clinical and MR imaging data were obtained.

¹ Department of Diagnostic Radiology, Singapore General Hospital, Singapore

² Department of Oncologic Imaging, National Cancer Centre, Singapore

³ Department of Pathology, Singapore General Hospital, Singapore

⁴ Department of Urology, Singapore General Hospital, Singapore

⁵ Department of Radiation Oncology, National Cancer Centre, Singapore

Address for Correspondence: Dr Judy SP Tan, Department of Diagnostic Radiology, Singapore General Hospital, 1 Hospital Drive, Singapore 169608.

Table 1. Sequences Performed with Pelvic Phased-array Coil

Sequence	TR/TE (msec)	FOV (cm)	Matrix (frequency/phase)	Frequency direction	NEX	Section thickness/ intersection gap (mm)
Axial T1W FSE of whole pelvis	700/12-18	30 x 16	320 x 224	transverse	4	8/1
Axial GRASS	33/13; flip angle = 30	30 x 16	256 x 192	transverse	2	8/1
Axial T1W FSE of prostate	600/10-18	16 x 16	320 x 224	Transverse	4	4/1

FOV: field of view; FSE: fast spin echo; GRASS: gradient recalled acquisition in steady state; NEX: number of excitation; T1W: T1-weighted; TE: echo time; TR: repetition time

Table 2. Sequences Performed with Combined Endorectal and Pelvic Phased-array Coils

Sequence	TR/TE (msec)	FOV (cm)	Matrix (frequency/phase)	Frequency direction	NEX	Section thickness/ intersection gap (mm)
Axial T2W FRFSE	5000/90	12 x 12	320 x 224	anteroposterior	4	3/0.5
Coronal T2W FRFSE	5000/90	12 x 12	320 x 224	superoinferior	4	3/0.5

FOV: field of view; FRFSE: fast recovery fast spin echo; NEX: number of excitation; T2W: T2-weighted; TE: echo time; TR: repetition time

The MR examinations were performed with a 1.5-T whole-body MRI system (GE Medical systems, GE Signa LX). The examination was performed with the patients in a supine position. Patients were examined using the body coil for excitation and a pelvic phased-array coil in combination with a commercially available balloon-covered expandable endorectal coil for signal reception. The sequences employed using the pelvic phased-array coil and endorectal coil are detailed in Tables 1 and 2 respectively.

All but 1 patient had their MR images interpreted by a single radiologist with subspecialty body imaging experience using criteria from Yu et al’s study.¹² Diagnostic criteria used for extracapsular extension (ECE) included irregular capsular bulge, asymmetry and thickening of neurovascular bundle at mid gland, obliteration of rectoprostatic angle and periprostatic fat infiltration. Sensitivity, specificity and accuracy of MR in evaluation of ECE were determined. While 95% confidence interval was calculated using the method of Agresti and Coull.¹³ True positive was defined as MR finding of locally advanced disease confirmed pathologically based on histopathological reports. No direct correlation to whole-mount specimens was made.

Results

The mean age of the 32 patients was 61 years (range, 33 to 71). The average time interval between the MR examination and radical prostatectomy was 59.3 days (range, 2 to 181). At histopathologic analysis, 18 patients had stage pT2 disease while 14 patients had stage pT3 disease. We correctly reported 17 cases of organ-confined disease and 2 cases of locally advanced disease. One case of organ-confined disease was reported as having ECE due

Table 3. Comparison of Pathologic and MR Imaging Findings

MR findings	Pathologic Findings		Total
	Organ-confined	Locally advanced	
Organ-confined	17	12	29
Locally advanced	1	2	3
Total	18	14	32

Note:

accuracy = 19/32 (59.4%; 95% CI: 42.3%, 74.5%);
 negative predictive value = 17/29 (58.6%; 95% CI: 40.7%, 74.5%);
 positive predictive value = 2/3 (66.7%; 95% CI: 20.8%, 93.9%);
 sensitivity for ECE = 2/14 [14.3%; 95% confidence interval (CI): 4%, 40%];
 specificity = 17/18 (94.4%; 95% CI: 74.2%, 99%);

to the presence of left capsular bulge. This case was reviewed by both the radiologist and pathologist. On histologic examination, there was an organ-confined focal bulge with a 2-mm rim of capsule (Fig. 1).

In the evaluation of ECE, endorectal MR achieved a high specificity of 94.4%, low sensitivity of 14.3%, moderate accuracy of 59.4%, positive predictive value of 66.7% and negative predictive value of 58.6% (Table 3).

Discussion

Accurate local staging of prostate cancer is important for treatment planning. It has recently been shown that radical prostatectomy for organ-confined disease reduces disease-specific mortality, overall mortality, risks of metastasis and local progression.¹⁴ Patient selection is important as radical prostatectomy is a major operation with attendant risks of urinary and sexual dysfunction.^{15,16} Staging of prostate cancer is performed using Partin’s tables. The combination

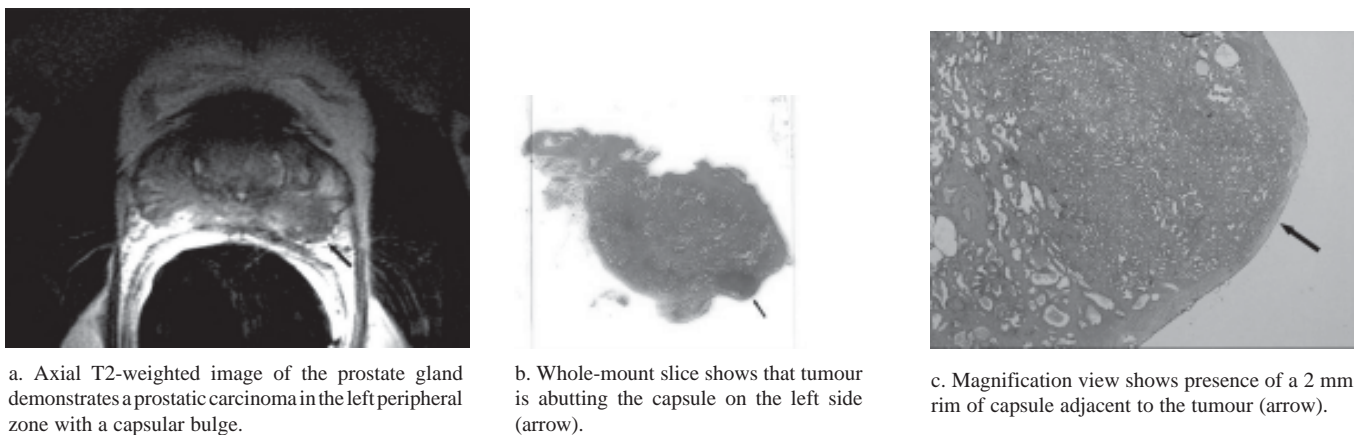


Fig 1. False positive depiction of extraprostatic extension by endorectal magnetic resonance imaging (MRI).

of PSA, clinical stage and Gleason score remains the norm for predicting the pathological stage of localised prostate cancer. MRI has a complementary role in improving the accuracy of local staging in patients with intermediate risk based on Partin's nomograms.^{7,17} The definition of intermediate risks includes: 1) PSA 10 ng/mL or less, biopsy Gleason score 6 or less, 1992 American Joint Committee on Cancer (AJCC) clinical stage T1c or T2a and greater than 50% positive prostate biopsies; 2) greater than 10 to 20 ng/mL, score 7 or stage T2b and 34% to 50%; or 3) greater than 20 ng/mL, score 8 to 10 or stage T2c disease and less than 34%.⁷ In patients with intermediate risks based on Partin's nomogram, the presence or absence of extraprostatic extension on MRI stratifies the 5-year biochemical failure into 2 distinct groups. Hence, surgery should be considered in the intermediate risk patient if MR does not demonstrate extraprostatic extension.

In recent years, endorectal MRI appears to be the most accurate imaging test available for local staging of prostate cancer, replacing phased array MRI of the prostate due to higher spatial and contrast resolution translating to a better image quality.^{18,19} Reported accuracy rates of endorectal MR in staging of prostate cancer vary from 51% to 82.6%.^{12,17,20,21} Wang et al¹⁷ demonstrated that endorectal MR prostate imaging findings are an independent predictor of ECE, yielding additional value to clinical variables (e.g., serum PSA, Gleason score, clinical stage of tumour, greatest percentage of cancer in all core biopsy specimens, etc).

A wide range of specificities and sensitivities of endorectal MR in the assessment of ECE have been reported in the literature, varying from 68% to 95.4% and 17% to 84% respectively.^{12,17,18,20,22} This is due to a combination of factors including differences in radiologists' experience and subspecialty training^{22,23} as well as a lack of standardised diagnostic criteria.^{12,24} High diagnostic specificity indicates

low false-positives and thus helps to ensure that few patients will be deprived of potentially curative surgery. It is accepted that high specificity, even if accompanied by low sensitivity, is a more cost-effective approach for patients being considered for surgery.¹⁰ In our institution, we are able to achieve a high specificity rate of 94.4%, comparable with international norms. Variable sensitivity remains a problem with endorectal MR prostate study, suggesting that the spatial and contrast resolution is still not optimal for the detection of microscopic invasion.^{7,12} One of the limitations of this retrospective study is a tendency for bias towards patients with clinically limited disease. Hence, sensitivity of endorectal coil MR prostate may potentially be lower as patients with clinically obvious extraprostatic extensions are not included in this study. Future study including all patients may eliminate this bias, thus providing a more accurate assessment of this imaging modality as a staging tool.

In conclusion, we are able to achieve a high specificity rate for ECE in our endorectal coil MR prostate examinations, in keeping with international norms, satisfying the complementary role that endorectal coil MR prostate plays in the local staging of prostate cancer in patients with intermediate risk.

REFERENCES

1. Seow A, Koh WP, Chia KS, Shi LM, Lee HP, Shanmugaratnam K. Trends in Cancer incidence in Singapore 1968-2002. Singapore: Singapore Cancer Registry, 2003. Report No. 6.
2. Sim HG, Cheng CW. Changing demography of prostate cancer in Asia. *Eur J Cancer* 2005;41:834-45.
3. Epstein JI, Partin AW, Sauvageot J, Walsh PC. Prediction of progression following radical prostatectomy. A multivariate analysis of 721 men with long-term follow-up. *Am J Surg Pathol* 1996;20:286-92.
4. Partin AW, Kattan MW, Subong EN, Walsh PC, Wojno KJ, Oesterling JE, et al. Combination of prostate-specific antigen, clinical stage, and

- Gleason score to predict pathological stage of localized prostate cancer. A multi-institutional update. *JAMA* 1997;277:1445-51. Erratum in: *JAMA* 1997;278:118.
5. Partin AW, Mangold LA, Lamm DM, Walsh PC, Epstein JI, Pearson JD. Contemporary update of prostate cancer staging nomograms (Partin Tables) for the new millennium. *Urology* 2001;58:843-8.
 6. D'Amico AV, Whittington R, Malkowicz SB, Schultz D, Blank K, Broderick GA, et al. Biochemical outcome after radical prostatectomy, external beam radiation therapy, or interstitial radiation therapy for clinically localized prostate cancer. *JAMA* 1998;280:969-74.
 7. D'Amico AV, Whittington R, Malkowicz B, Schnall M, Schultz D, Cote K, et al. Endorectal magnetic resonance imaging as a predictor of biochemical outcome after radical prostatectomy in men with clinically localized prostate cancer. *J Urol* 2000;164:759-63.
 8. D'Amico AV, Whittington R, Malkowicz SB, Fondurulia J, Chen MH, Kaplan I, et al. Pretreatment nomogram for prostate-specific antigen recurrence after radical prostatectomy or external-beam radiation therapy for clinically localized prostate cancer. *J Clin Oncol* 1999;17:168-72.
 9. Stephenson AJ, Scardino PT, Eastham JA, Bianco FJ Jr, Dotan ZA, Fearn PA, et al. Preoperative nomogram predicting the 10-year probability of prostate cancer recurrence after radical prostatectomy. *J Natl Cancer Inst* 2006;98:715-7.
 10. Coakley FV, Qayyum A, Kurhanewicz J. Magnetic resonance imaging and spectroscopic imaging of prostate cancer. *J Urol* 2003;170:S69-75.
 11. Kwek JW, Thng CH, Tan PH, Yuen JS, Khoo JB, Quek ST, et al. Phased-array magnetic resonance imaging of the prostate with correlation to radical prostatectomy specimens: local experience. *Asian J Surg* 2004;27:219-24.
 12. Yu KK, Hricak H, Alagappan R, Chernoff DM, Bacchetti P, Zaloudek CJ. Detection of extracapsular extension of prostate carcinoma with endorectal and phased-array coil MR imaging: multivariate feature analysis. *Radiology* 1997;202:697-702.
 13. Agresti A, Coull BA. Approximate is better than "exact" for interval estimation of binomial proportions. *Am Stat* 1998;52:119-26.
 14. Bill-Axelsson A, Holmberg L, Ruutu M, Haggman M, Andersson SO, Bratell S, et al. Scandinavian Prostate Cancer Group Study No. 4. Radical prostatectomy versus watchful waiting in early prostate cancer. *N Engl J Med* 2005;352:1977-84.
 15. Steineck G, Helgesen F, Adolfsson J, Dickman PW, Johansson JE, Norlen BJ, et al. Scandinavian Prostatic Cancer Group Study Number 4. Quality of life after radical prostatectomy or watchful waiting. *N Engl J Med* 2002;347:790-6.
 16. Penson DF, Litwin MS, Aaronson NK. Health related quality of life in men with prostate cancer. *J Urol* 2003;169:1653-61.
 17. Wang L, Mullerad M, Chen HN, Eberhardt SC, Kattan MW, Scardino PT, et al. Prostate cancer: incremental value of endorectal MR imaging findings for prediction of extracapsular extension. *Radiology* 2004;232:133-9.
 18. Hricak H, White S, Vigneron D, Kurhanewicz J, Kosco A, Levin D, et al. Carcinoma of the prostate gland: MR imaging with pelvic phased-array coils versus integrated endorectal - pelvic phased-array coils. *Radiology* 1994;193:703-9.
 19. Schnall MD, Imai Y, Tomaszewski J, Pollack HM, Lenkinski RE, Kressel HY. Prostate cancer: Local staging with endorectal surface coil MR imaging. *Radiology* 1991;178:797-802.
 20. Jager GJ, Ruijter ET, van de Kaa CA, de la Rosette JJ, Oosterhof GO, Thornbury JR, et al. Local staging of prostate cancer with endorectal MR imaging: correlation with histopathology. *Am J Roentgenol* 1996;166:845-52.
 21. Quinn SF, Franzini DA, Demlow TA, Rosencrantz DR, Kim J, Hanna RM, et al. MR imaging of prostate cancer with an endorectal surface coil technique: Correlation with whole-mount specimens. *Radiology* 1994;190:323-7.
 22. Yu KK, Scheidler J, Hricak H, Vigneron DB, Zaloudek CJ. Prostate cancer: prediction of extracapsular extension with endorectal MR imaging and three-dimensional proton MR spectroscopic imaging. *Radiology* 1999;213:481-8.
 23. Mullerad M, Hricak H, Wang L, Chen HN, Kattan MW, Scardino PT. Prostate cancer: detection of extracapsular extension by genitourinary and general body radiologists at MR imaging. *Radiology* 2004;232:140-6.
 24. Outwater EK, Petersen RO, Siegelman ES, Gomella LG, Chernesky CE, Mitchell DG. Prostate carcinoma: assessment of diagnostic criteria for capsular penetration on endorectal coil MR images. *Radiology* 1994;193:333-9.