

## Torsion of the Gallbladder: A Rare Entity

### Dear Editor,

Torsion of the gallbladder remains a rare entity difficult to diagnose preoperatively. To our knowledge, this is the first reported case in the literature in our local context with a subsequent literature review on the management of this uncommon condition.

A 45-year-old Chinese female presented to us with a 24-hour history of severe epigastric pain without radiation and associated with nausea and vomiting. She was febrile on admission with moderate right hypochondrial tenderness and positive Murphy's sign. Admission white cell count was  $14.0 \times 10^3/\text{UL}$  ( $7.0\text{-}11.0 \times 10^3/\text{UL}$ ). Liver function test and amylase were within normal range. Chest radiograph and abdominal radiograph done were unremarkable. She was started on intravenous antibiotics with a provisional diagnosis of acute cholecystitis. However, her symptoms failed to respond to conservative management. Intravenous contrast enhanced computed tomography (CT) of the abdomen and pelvis done revealed a markedly distended gallbladder with pericholecystic stranding with focal mass-like thickening of gallbladder neck.

Emergency cholecystectomy via a Kocher's incision was performed on the fifth day following admission. Intraoperatively the gallbladder was markedly enlarged, acalculous and gangrenous with anticlockwise 360 degrees torsion of the pedicle (Fig. 1) The patient recovered well postoperatively and was discharged day 4 post-operation.

Gallbladder torsion was first described by Wendell in 1898 and since then, fewer than 400 cases have been reported in the literature. The peak incidence of gallbladder torsion is in elderly women aged between 65 and 75 years, accounting for 84% of cases.

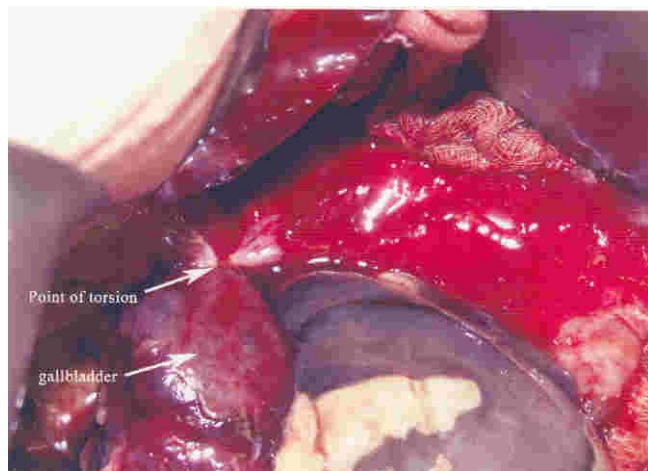


Fig 1. Point of torsion is at the neck of the gallbladder.

Although commonly mimicking acute cholecystitis, Lau et al<sup>1</sup> proposed 3 triads of clinical diagnosis suggestive of torsion. These include specific symptoms (short history, abdominal pain and early vomiting), physical signs (abdominal mass, absence of toxemia, and a pulse rate–temperature discrepancy) and even physical characteristics (thin, elderly, and deformed spine). Interestingly, gallstones are not a consistent risk factor, only present in approximately 20% to 33% of patients with torsion.

Anatomically, 2 features predispose the gallbladder to torsion. The first is having a long mesentery allowing the gallbladder to twist. The other is having a short mesentery supporting only the cystic duct and vessels, with the loss of fixation of the gallbladder to the inferior margin of the liver – the so-called “floating gallbladder”. Autopsy studies have found these anatomic variants in up to 4% to 5% of the population; however, the actual incidence of gallbladder torsion is much lower.<sup>2</sup>

Furthermore, torsion may be divided into complete (>180 degrees) and incomplete (<180 degrees). Complete torsion is likely to result in vascular compromise and gangrene of the gallbladder, whereas incomplete torsion may only obstruct the cystic duct and blood supply to the gallbladder wall may be maintained.<sup>3</sup> Some authors suggest that intense peristalsis by the stomach or the duodenum is implicated in clockwise rotation whereas the transverse colon is implicated in counterclockwise rotation. Other precipitating factors mentioned in the literature include kyphoscoliosis, visceroptosis, cystic artery atherosclerosis, abdominal trauma, sudden motion, heavy meals, constipation, adhesions, weight loss, and postpartum status.

Blood tests are generally unremarkable early in the clinical presentation, with white blood count often within normal limits and liver function test not deranged. Sonographic features of gallbladder torsion include a large anteriorly floating gallbladder without gallstones and a conical appearance of the neck with discontinuity of the lumen suggesting torsion. Merine et al<sup>4</sup> proposed that a massively distended gallbladder, resembling a fluid-filled loop of the bowel with a circular high attenuation structure to the right of the gallbladder on CT scan were specific signs of torsion of the gallbladder. Suggestive magnetic resonance cholangiopancreatography (MRCP) findings include a V-shaped distortion of the extra-hepatic bile ducts due to traction by the cystic duct, tapering and twisting of the cystic duct, a distended gallbladder and intensity differences between the gallbladder and the cystic and extra-hepatic bile ducts.

Definitive treatment is urgent surgery and removal of the gallbladder. Delayed intervention may result in gangrenous acute cholecystitis, perforation and severe sepsis, leading to high mortality and morbidity, especially in the elderly with diminished physical and physiological reserves.

While the majority of cases were treated via open cholecystectomy, there are emerging reports of gallbladder torsion diagnosed and removed laparoscopically with success. Principles of laparoscopic management include laparoscopic decompression, detorsion and cholecystectomy with or without intraoperative cholangiogram.<sup>5</sup> Diagnosed early and treated with cholecystectomy, this disease has a low mortality rate of less than 5%.

Gallbladder torsion, while rare, is an important differential diagnosis in the setting of an elderly patient with atypical or non-resolving signs and symptoms of acute cholecystitis. Early diagnostic investigations should be arranged and emergent surgery, whether open or laparoscopic, should be performed for best patient outcome.

## REFERENCES

1. Lau WY, Fan ST, Wong SH. Acute torsion of the gallbladder in the aged: a re-emphasis on clinical diagnosis. *Aust N Z J Surg* 1982;52:492-4.
2. Gross RE. Congenital anomalies of the gallbladder: a review of one hundred and forty-eight cases, with report of a double gallbladder. *Arch Surg* 1936;32:131-62.
3. Ashby BS. Acute and recurrent torsion of the gall-bladder. *Br J Surg* 1965;52:182-4.
4. Merine D, Meziane M, Fishman EK. CT diagnosis of gallbladder torsion. *J Comput Assist Tomogr* 1987;11:712-3.
5. Nguyen T, Geraci A, Bauer JJ. Laparoscopic cholecystectomy for gallbladder volvulus. *Surg Endosc* 1995;9:519-21.

Adrian KH Chiow,<sup>1</sup>*MBBS (Melbourne)*, Salleh Ibrahim,<sup>1</sup>*MBBS, FRCS (Glas), FAMS*, Khoon-Hean Tay,<sup>1</sup>*MBBS, FRCS (Glas, Edin), FAMS*

<sup>1</sup> Department of General Surgery, Changi General Hospital, Singapore

Address for Correspondence: Dr Salleh Ibrahim, Department of General Surgery, Changi General Hospital, 2 Simei Street 3, Singapore 529889.