

## Clinically Compressed Digital Echocardiography: A Patient-safe Alternative to Videotape Review

Kian-Keong Poh,<sup>1</sup>*MBBChir (Camb), MRCP, FAMS*, Hong Yang,<sup>2</sup>*MD, RDCS*, Abdul Razakjr Omar,<sup>1</sup>*MBBS, MRCP, FAMS*, James WL Yip,<sup>1</sup>*MBBS, MRCP, FAMS*, Yiong-Huak Chan,<sup>3</sup>*PhD*, Lieng-Hsi Ling,<sup>2</sup>*MBBS, FRCP, FAMS*

### Abstract

**Introduction:** Digital storage of echocardiographic data offers logistical advantages over videotape archival. However, limited information is available on the accuracy of clinically compressed digitised examinations, an important consideration for patient safety. **Materials and Methods:** Transthoracic echocardiograms of 520 consecutive patients were prospectively acquired digitally and on videotape. Two echocardiologists, in consensus, reported studies in both formats sequentially. Using the videotape as a reference, the significance of any reported differences was graded from both imaging and clinical standpoints, and the reasons for these differences identified. **Results:** From an imaging perspective, differences between digital and videotaped studies were absent or minor in 459 cases (88%), fairly significant in 55 (11%) and very significant in 6 (1%). The main reasons for the observed differences were inadequate acquisition of optimal views (59%), an insufficient number of acquired cardiac cycles (25%) and suboptimal image quality (9%). These differences were considered to be of possible or definite clinical importance in 21 (4%) and 8 (2%) cases, respectively. In multinomial logistic regression models, the only independent predictor of significant difference between digitised and videotaped images was study complexity. Regardless of case complexity, most diagnostic errors arising from digital review were attributable to technical failure rather than observer error. **Conclusions:** The potential for important errors arising from exclusive reporting of clinically compressed digital echocardiograms is small. Digital echocardiography, as practiced in a routine clinical setting, offers a patient-safe alternative to videotape review.

*Ann Acad Med Singapore 2007;36:662-71*

**Key words:** Clinical implications, Digital echocardiography, Patient safety, Videotape

### Introduction

The field of echocardiography has seen significant technological advances in instrumentation, imaging and recently, image archival and review.<sup>1</sup> Compared to conventional videotape storage, digital echocardiograms offer many advantages,<sup>2-6</sup> including random access to images, comparative interpretation of serial studies, rapid data transmission, duplication without image degradation and data measurement without a need for calibration. The logistical superiority of digital review has the potential to improve the use of physician and sonographer time and increase cost-efficiency.

However, limited information is available on the accuracy of clinically compressed digitised examinations, which is critical for clinical management and patient safety. Until

such data become widely available, physicians practising in today's high-litigation environments may continue to have reservations about digital review. At our institution, echocardiograms have been stored and reviewed on videotape for over 15 years. In the process of migration to a fully digital echocardiographic laboratory, we aimed to determine if diagnostic information equivalent to tape recordings could be obtained without compromising patient safety and management decisions.

### Materials and Methods

Transthoracic echocardiograms of 520 consecutive patients were prospectively acquired digitally and on videotape over a 4-month period. Twelve cardiac sonographers performed all the examinations; 5 sono-

<sup>1</sup> Cardiac Department, National University Hospital, Singapore

<sup>2</sup> Department of Medicine, Yong Loo Lin School of Medicine, National University of Singapore, Singapore

<sup>3</sup> Biostatistics Unit, Yong Loo Lin School of Medicine, National University of Singapore, Singapore

Address for Correspondence: Dr Kian-Keong Poh, Cardiac Department, National University Hospital, 5 Lower Kent Ridge Rd, Singapore 119074.

Email: doctorpoh@yahoo.com

graphers had 1 to 3 years of experience, and 7 of them had 4 to 9 years of experience. All studies were performed with SONOS 5500 ultrasound equipment (Philips Medical Systems, Andover, Massachusetts) using the S4 (2 to 4 MHz) transducer. Harmonic imaging was used whenever necessary.

#### *Videotape Recordings*

Standard M-mode, two-dimensional, spectral and colour Doppler echocardiograms were recorded on super VHS tape. Imaging windows included all standard imaging planes and additional non-standard views, depending on the abnormality of interest.<sup>7</sup> At least 5 cardiac cycles of each view were recorded. The average duration of videotape recording was about 15 minutes (11 to 13 studies stored per 180-minute tape).

#### *Digital Recordings*

Sonographers were trained over several didactic demonstrations and on the job to acquire digital images according to a standard protocol (Table 1), which was appended in every scan room for ready reference. They had been routinely acquiring digital images for 3 months prior to the study. Digital acquisition was considered adequate when all views mandated by the protocol were obtained. However, sonographers were encouraged to obtain additional views of ambiguous findings to ensure representative recordings.

The R-wave of the electrocardiogram was used to trigger digital capture. Two cardiac cycles were captured for patients in sinus rhythm and 3 for irregular rhythms, including atrial fibrillation (AF). Non-QRS-triggered and post-ectopic loops and those with very short R-R intervals during AF were rejected. Care was taken to ensure that the full extent of colour Doppler jets was represented. All measurements and quantifications, including those of valvular regurgitation, were made in real time. Acquired cine-loops were previewed for quality immediately before storage onto hard disk.

Upon completion of the study, the locally stored file, typically 150 megabytes in size, was relayed via gigabit Ethernet to a central server for archival in proprietary digital and storage retrieval (DSR)-TIFF format. Images were retrieved for review on workstations running the EnConcert Image Diagnosis Application Version B.2.2 (Philips Medical Systems, Andover, MA). Two-dimensional and colour flow images were displayed at 1024 x 768 resolution and in at least 256 colours. Spectral Doppler and M-mode recordings were captured in single-page format and displayed as full screen images.

#### *Reporting and Analysis Methodology*

Two cardiologists (LHL and KKP) reported the

echocardiograms in consensus. These readers had been routinely reporting digital studies for at least 3 months prior to this study. To minimise potentially significant observer variability,<sup>8</sup> the digital echocardiogram was read first, followed immediately by the videotaped study.

Each echocardiogram was categorised by the amount of experience of the sonographer (<4 years, ≥4 years), image quality (good, fair, poor), cardiac rhythm (regular, AF, other irregular), principal diagnosis (valvular heart disease, ischaemic heart disease, hypertensive heart disease/hypertrophic cardiomyopathy, congenital heart disease, others), number of abnormal findings per study (0 to 4, 5 to 8, ≥9), severity of disease (normal or borderline, mild, moderate, severe) classified according to severity of the most abnormal pathology, and complexity of interpretation (low, intermediate, high) based on the opinion of the reporting echocardiologists. Low complexity studies included those with minor abnormalities or single valvular disease, intermediate complexity studies were those with multivalvular disease or mixed pathologies and high complexity studies were those deemed particularly challenging to interpretation, including complicated congenital heart anomalies and constrictive pericarditis.

Using the videotape as the reference standard, the importance of any discrepant finding was assessed from both imaging and clinical standpoints. Particular attention was focused on common but important abnormalities such as regional wall motion (RWM) deficits, left ventricular (LV) function, LV thrombi and valvular disease. RWM analysis was scored using the 16-segment model recommended by the American Society of Echocardiography<sup>9</sup> and the RWM score index was derived from the sum of all scores divided by the number of segments. LV ejection fraction was evaluated visually, taking into account all segmental wall motion as previously validated.<sup>10-12</sup> All measurements and quantifications were accepted at face value since these were made in real time on digital preview by sonographers. Any "error" noted on subsequent review of either digital or videotape images cannot therefore be attributed to intrinsic differences between these media. For valvular lesions in particular, severity was judged using a constellation of semiquantitative signs routinely employed in clinical practice including chamber, colour jet and vena contracta size, rather than quantitative data which had not been systematically obtained.<sup>13</sup>

All differences were qualitatively categorised from an imaging perspective as none or minor, moderately significant, or highly significant. Discrepancies deemed moderately significant included discrepancies in grading RWM or degree of valvular regurgitation. Highly significant differences included under-appreciation or misinterpreta-

Table 1. Digital Acquisition Protocol at National University Hospital, Singapore

View	Echocardiographic modality						Total images	
	M-mode frame	2D loop	Colour loop	PWD loop	CWD loop	TVI frame		
1	Parasternal LAX		✓				2	
2	Parasternal LAX (MV zoom)		✓				2	
3	Parasternal LAX (AV zoom)		✓				2	
4	Parasternal LAX (Ascending Ao)		✓				1	
5	RV inflow		✓				2	
6	Doppler TV				✓		4	
7	Parasternal SAX (AV)		✓				2	
8	Parasternal SAX (AV zoom)		✓				2	
9	RV outflow		✓				2	
10	Doppler pulmonary valve				✓		4	
11	M-mode (Ao-LA)	✓					1	
12	Parasternal SAX at MV		✓				2	
13	E-point septal separation	✓					1	
14	Parasternal SAX at papillary muscle		✓				1	
15	M-mode (LV)	✓					1	
16	Parasternal SAX at apex		✓				1	
17	Apical 4Ch (2D, MV/TV colour)		✓				2	
18	Apical 4Ch (LV zoom)		✓				1	
19	Apical 4Ch (MV zoom)		✓				2	
20	Doppler MV				✓		2	
21	Doppler pulmonary vein				✓		2	
22	Apical 4Ch (TV zoom)		✓				2	
23	TVI lateral mitral annulus					✓	2	
24	TVI septal annulus					✓	2	
25	TVI RV annulus					✓	2	
26	Apical 2Ch		✓				2	
27	Apical 2Ch (LV zoom)		✓				1	
28	Apical LAX		✓				2	
29	Apical LAX (LV zoom)		✓				1	
30	Apical LAX (MV zoom)		✓				2	
31	Apical LAX (AV zoom)		✓				2	
32	Doppler LV outflow and AV				✓		4	
33	Isovolumic relaxation time					✓	2	
34	Subcostal 4Ch		✓				2	
35	Subcostal 4Ch (atrial septum zoom)		✓				2	
36	Subcostal SAX (inferior vena cava)		✓				2	
37	Doppler hepatic vein				✓		2	
38	Subcostal SAX (Abdominal Ao)		✓				1	
39	Suprasternal (Ao arch)		✓				2	
	Total loops and frames	3	26	19	6 x 2	4 x 2	3 x 2	74

2Ch: 2-chamber; 2D: two-dimensional imaging; 4Ch: 4-chamber; Ao: aorta; AV: aortic valve; CWD: continuous wave Doppler; LA: left atrial; LAX: long axis; LV: left ventricular; MV: mitral valve; PWD: pulse wave Doppler; RV: right ventricular; TV: tricuspid valve; TVI: tissue velocity imaging; Sax: short axis

tion of pathology during digital review, e.g., failure to diagnose LV thrombus. Additionally, the impact of these differences on subsequent clinical management was assessed specific to the clinical scenario and triaged as being of no, possible, or definite importance. For example, failure to diagnose mild mitral valve prolapse during digital review was deemed possibly important if endocarditis prophylaxis was recommended. Conversely, failure to diagnose mild tricuspid valve prolapse in a patient with known mitral valve prolapse was considered not clinically important, as the need for antibiotic prophylaxis was already evident.

### Statistics

Analysis was done with SPSS version 11.5 (SPSS Inc., Chicago, Illinois). Using univariate logistic regression, the variables that accounted for discrepancy between digital and videotape recordings, and which in turn impacted clinical decision-making, were identified. A multivariate model was computed, adjusting for all parameters to determine independent predictors. Odd ratios and 95% confidence intervals (CIs) were calculated in the usual manner. Statistical significance was attributed at  $P < 0.05$ .

### Results

Each of the 12 sonographers acquired between 3% and 14% of all studies. The spectrum of major diagnoses is shown in Figure 1. Cardiac abnormalities were absent or of borderline significance in 8%, considered mild in 54%, moderate in 18% and severe in 20% of the studies. The number of abnormal findings per study ranged from 0 to 14. Irregular cardiac rhythm was present in 72 studies (14%). This consisted of AF in 58 cases (11%), frequent ventricular ectopic beats in 9 (2%), frequent atrial ectopy in 3 (0.6%) and second-degree atrioventricular conduction block in 2 cases (0.4%). Study complexity was deemed low in 404 patients (78%), intermediate in 101 (19%) and high in 15 patients (3%). Image quality was good in 325 cases (62%), fair in 159 (31%) and suboptimal in 36 cases (7%).

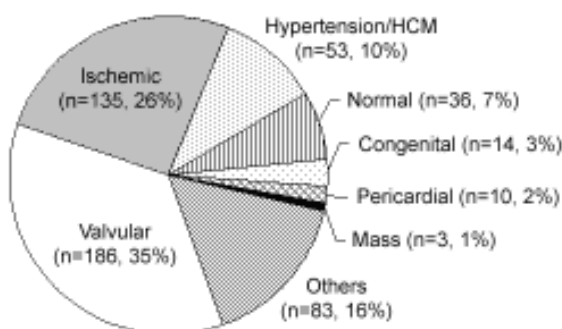


Fig. 1. Main echocardiographic diagnoses of the study population (n = 520).

### Discrepancies in Reported Findings

Complete or near-complete concordance between digital and videotaped echocardiographic images was present in 459 patients (88%), moderately significant differences were found in 55 (11%) and highly significant differences in 6 patients (1%). Specific differences of interest are summarised in Table 2. These include under- or over-detection of valve prolapse or RWM abnormality, particularly inferior wall, and under- or overestimation of valvular regurgitant severity. LV thrombus was not appreciated on the digitised study in 1 of 8 cases. LV ejection fraction was concordant in the majority of cases, differed by  $\leq 5\%$  in 33 cases (6%) and  $> 5\%$  in 1 case (0.2%). In this last case, ejection fraction was revised from 50% to 40% after appreciation of more severe inferior RWM abnormalities on videotape.

Observed differences were attributable to: a failure to obtain the most representative images (96 studies, 65%), an insufficient number of cardiac cycles leading to under-appreciation of transient or subtle abnormality, including valvular prolapse and RWM deficit (36 studies, 24%), suboptimal image quality (8 studies, 5%) and miscellaneous reasons such as irregular rhythm (predominantly AF), image artifacts and observer error (9 studies, 6%).

Of the 58 studies acquired in AF, significant discrepancies were observed in 6 cases (10%), of which 2 (3%) were attributable to the irregular rhythm. AF led to discrepant RWM assessment and underestimation of tricuspid regurgitation severity in these cases, both deemed moderately significant. Observed differences in the remaining 4 cases were due to failure to obtain optimal views, which was also the most common reason for discordance regardless of prevailing rhythm during image acquisition. Overall, compared to studies recorded in regular rhythm, significant interpretive differences (moderate or greater) were not more frequently observed during AF [odds ratio (OR), 0.9; 95% CI, 0.4 to 2.1;  $P = 0.74$ ].

### Clinical Implications of Discrepant Findings

Of the 55 patients with moderately significant differences between videotaped and digital echocardiograms, these were considered to merit no, possible and definite additional clinical recommendations in 35, 16 and 4 cases, respectively. Of the 6 patients in whom highly significant differences were documented, possible changes in management were warranted in 2 and definite change in 4 cases. Overall, digital echocardiographic findings resulted in concordant management recommendations for the vast majority of patients (491/520 or 94%), while in 4% (21/520) and 2% (8/520) of cases, possible and definite changes in clinical approach were recommended respectively after reviewing

Table 2. Discrepancies in Selected Echocardiographic Measures or Diagnoses Noted During Review of Digital Images, Using Videotape as the Reference Standard

Echocardiographic measures or diagnoses	Total cases*	Nature of discrepancy	n (%)
Left ventricular ejection fraction	520	Underestimation†	0 (0)
		Overestimation†	1 (0.2)
Regional wall motion score	520	Underestimation	23 (4)
		Overestimation	12 (2)
Left ventricular thrombus	8	Underdetection	1 (13)
		Overdetection	0 (0)
Mitral valve prolapse			
Anterior leaflet	131	Underdetection	13 (10)
		Overdetection	2 (2)
Posterior leaflet	97	Underdetection	10 (10)
		Overdetection	2 (2)
Tricuspid valve prolapse	86	Underdetection	3 (3)
Mitral regurgitation	423	Severity underestimated	5 (1)
		Severity overestimated	0 (0)
		Underdetection	1 (0.2)
Aortic regurgitation	138	Severity underestimated	3 (2)
		Severity overestimated	1 (1)
		Underdetection	3 (2)
Tricuspid regurgitation	370	Severity underestimated	2 (1)
		Severity overestimated	0 (0)
		Underdetection	1 (0.3)

\* Based on diagnoses documented in final report

† Discrepancy in left ventricular ejection >5%

videotaped images. Synopses of these last 8 patients are detailed in Table 3.

Mitral valve prolapse was the condition most frequently under-diagnosed following digital image review. In total, there were 19 such cases, 4 bileaflet, 9 isolated anterior and 6 isolated posterior leaflet prolapse (Table 2). Under-diagnosis did not alter management recommendations in 10 patients who had coexisting conditions mandating antibiotics prophylaxis, such as obvious prolapse and regurgitation of other valves. The remaining 9 cases, which were “missed”, were considered to merit possible or definite antibiotics prophylaxis, depending on leaflet morphology and degree of associated regurgitation.

#### Predictors of Discrepancy

Table 4 shows univariate and multivariate analyses of candidate predictors of discrepancy between digitised and videotaped studies. In univariate analyses, principal diagnosis (congenital, valvular and ischaemic heart disease) and study complexity were predictive of moderately or highly significant differences. After adjusting for all variables in the multivariate model, the only independent

predictor of discrepancy in echocardiographic diagnosis was study complexity (adjusted OR, 7.8; 95% CI, 1.7 to 35.7;  $P = 0.008$ , compared to “simple” cases). Complexity was again the only variable independently predictive of revised management recommendations arising from discrepancies in echocardiographic diagnoses (adjusted OR, 14.5; 95% CI, 1.8 to 111.1;  $P = 0.011$ ) although a strong trend was also evident for the number of abnormal findings per study (Table 5).

#### Discussion

Although there is no doubt that digital echocardiography confers logistical advantages and all infrastructural components required to build a digital laboratory are readily available,<sup>1</sup> progress towards sole digital storage and review has been slow. Recently published consensus guidelines<sup>14</sup> and accounts of successful migration to a digital laboratory<sup>15</sup> should encourage more institutions to make this transition. However, digital echocardiography poses new and considerable challenges with respect to operating expenses, compatibility with existing infrastructure, implementation and staff training. Physician inertia may also stem from

Table 3. Synopses of Studies where Discrepancies Identified after Videotape Review Mandated Additional Recommendations in Clinical Management

Case indications	Final diagnoses	Case complexity	“Errors” during digital review	Reason(s) for discrepancy	Recommendations made after videotape review
1 Pre-CABG assessment	Chronic IHD; severe LV dysfunction; scarred LV apex; 12-mm sessile thrombus	Simple	LV thrombus not confidently diagnosed	Most diagnostic image not digitised	Thrombectomy or deferment of CABG for anticoagulation
2 Atrial fibrillation; heart failure	Concentric LV remodelling, thickened epicardium, small pericardial effusion; constrictive physiology	Complex	HCM misdiagnosed	Observer error; inadequate acquisition of views and cardiac cycles	CT scan to image pericardium
3 Down syndrome; murmur	Gerbode VSD; ventricular septal aneurysm; primum ASD; cleft MV; bileaflet MV prolapse	Complex	ASD and cleft MV not diagnosed	Inadequate acquisition of views; observer error	Additional surgical repair
4 RBBB; chest pain	TV and MV prolapse; dilated aortic root; mildly dilated right heart chambers; no evidence of ASD	Intermediate	Right heart dilatation undiagnosed	Inadequate views	TEE to evaluate possible dilated right heart chambers and its aetiology
5 Dilated aortic root; serial study	Dilated aortic root; bileaflet MV prolapse; mild MR	Simple	MV prolapse undiagnosed	Inadequate cycles	Antibiotics prophylaxis
6 Preoperative assessment	Dilated cardiac chambers; MV prolapse with severe MR; TV prolapse with moderately severe TR	Intermediate	Unable to diagnose severity of TR	TR colour Doppler jet not recorded	Tricuspid annuloplasty
7 Murmur	VSD with left-to-right shunt; anomalous LV papillary muscle	Intermediate	VSD not evident; wrong impression of apical HCM	Inadequate views; suboptimal images	Antibiotics prophylaxis
8 Murmur; RBBB	Anterior MV prolapse; mildly thickened mitral leaflet	Simple	MV prolapse undiagnosed	Inadequate views	Antibiotics prophylaxis

ASD: atrial septal defect; CABG: coronary artery bypass grafting; CT: computed tomography; HCM: hypertrophic cardiomyopathy; IHD: ischaemic heart disease; LV: left ventricle; MR: mitral regurgitation; MV: mitral valve; RBBB: right bundle branch block; TEE: transoesophageal echocardiography; TR: tricuspid regurgitation; TV: tricuspid valve; VSD: ventricular septal defect

personal bias about accuracy compared to more familiar, conventional methods of review and legal liability arising from misdiagnosis.

Previous studies comparing the interpretation of digitised and videotaped echocardiograms<sup>16-23</sup> were small,<sup>16,18,21</sup> recruited non-consecutive subjects,<sup>19</sup> limited to specific referral populations,<sup>17</sup> or confined to analysis of specific disorders<sup>22</sup> or echocardiographic measurements.<sup>21</sup> In contrast, the present study includes a large number of consecutive referrals for echocardiography (excluding only cases performed by junior or trainee sonographers) and is therefore representative of the real-world utility and limitations of digital echocardiography. Arising from an unselected population, referral from non-cardiologists, and high threshold for attributing complexity, only 3% of

studies were deemed highly complex.

Unlike previous studies,<sup>18,19,24</sup> digital and videotaped echocardiograms were sequentially reviewed and immediately compared to limit the introduction of intraobserver variability, albeit at the expense of some training effect. Readings were also conducted in consensus to minimise subjectivity. Uniquely, any reported differences were immediately appraised in the clinical context to ascertain potential impact on management. To limit operator dependency, a standardised digital acquisition protocol was used and only sonographers with more than 1 year of experience participated in this study. This achieved the desired end since interpretative differences were attributable neither to individual sonographers nor to sonographer groups.

Table 4. Predictors of Discrepancy in Reported Findings Between Digital and Videotaped Examinations

	Discrepancy		Unadjusted OR (95% CI)	P value	Adjusted OR (95% CI)	P value
	None or minor (n = 459)	Moderate or major (n = 61)				
Sonographer experience						
<4 years	212 (46%)	34 (56%)	1.0	-	1.0	-
≥4 years	247 (54%)	27 (44%)	0.7 (0.4-1.2)	0.16	0.8 (0.5-1.5)	0.51
Image quality				0.23		0.074
Good	293 (64%)	32 (53%)	1.0	-	1.0	-
Fair	135 (29%)	24 (39%)	1.6 (0.9-2.9)	0.092	1.9 (1.02-3.4)	0.042
Poor	31 (7%)	5 (8%)	1.5 (0.5-4.1)	0.45	2.3 (0.8-6.8)	0.13
Cardiac rhythm				0.91		0.72
Regular	395 (86%)	53 (87%)	1.0	-	1.0	-
Atrial fibrillation	52 (11%)	6 (10%)	0.9 (0.4-2.1)	0.74	0.7 (0.3-1.8)	0.44
Other irregular	12 (3%)	2 (3%)	1.2 (0.3-5.7)	0.78	1.2 (0.2-5.8)	0.86
Principal diagnosis				0.008		0.051
Congenital HD	10 (2%)	4 (7%)	8.4 (2.0-34.7)	0.003	3.8 (0.7-20.4)	0.12
Hypertensive HD	50 (11%)	3 (5%)	1.3 (0.3-5.2)	0.75	1.4 (0.3-6.3)	0.65
Ischaemic HD	116 (25%)	19 (31%)	3.4 (1.3-8.9)	0.011	3.5 (1.2-10.2)	0.020
Valvular HD	157 (34%)	29 (48%)	3.9 (1.6-9.6)	0.003	4.0 (1.5-10.6)	0.007
Others	126 (28%)	6 (10%)	1.0	-	1.0	-
Number of abnormal findings				0.59		0.27
0 to 4	206 (45%)	25 (41%)	1.0	-	1.0	-
5 to 8	179 (39%)	23 (38%)	0.7 (0.3-1.4)	0.32	0.6 (0.3-1.2)	0.14
≥9	74 (16%)	13 (21%)	0.7 (0.4-1.5)	0.40	0.5 (0.2-1.3)	0.16
Severity of disease				0.14		0.59
Normal/Borderline	42 (9%)	1 (1%)	1.0	-	1.0	-
Mild	251 (55%)	30 (49%)	5.0 (0.7-37.8)	0.12	3.0 (0.4-25.0)	0.30
Moderate	78 (17%)	15 (25%)	8.1 (1.03-63.3)	0.047	4.4 (0.5-41.7)	0.20
Severe	88 (19%)	15 (25%)	7.1 (0.9-56.0)	0.061	3.5 (0.3-34.5)	0.29
Study complexity				0.005		0.030
Complex	9 (2%)	6 (10%)	5.9 (2.0-17.5)	0.001	7.8 (1.7-35.7)	0.008
Intermediate	86 (19%)	14 (23%)	1.4 (0.7-2.8)	0.27	1.4 (0.6-3.4)	0.40
Simple	364 (79%)	41 (67%)	1.0	-	1.0	-

CI: confidence intervals; HD: heart disease; OR: odds ratio

### Computer and Clinical Compression

In this study, image degradation was not a concern as all images were stored using a non-DICOM, lossless algorithm. The DICOM (Digital Imaging and Communications in Medicine) image formatting standard does, however, permit JPEG (Joint Photographic Expert Group) lossy compression for archival of echocardiograms.<sup>25</sup> Our findings are likely to be valid even with JPEG-compressed images since only compression ratios >20:1<sup>26</sup> and MPEG (Moving Pictures Expert Group) compression ratios >200:1 are reported to compromise image resolution.<sup>27</sup> “Clinical compression” was performed according to a standard protocol, which for

irregular rhythms mandated capture of an additional cardiac cycle. While this may still not be fully representative in patients with highly irregular cardiac rhythm, acquisition of an excessive number of loops increases storage requirements and examination time and bottlenecks data transmission. In a recent study evaluating valvular regurgitation, capture of multiple digital loops did not provide incremental value.<sup>22</sup>

### Concordance and Predictors of Discrepancy

In this study, there was complete or near-complete concordance between digital and videotape reporting in

Table 5. Predictors of Either Possible or Definite Clinical Impact of Discrepant Digital and Videotape Echocardiographic Diagnoses

	Clinical impact		Unadjusted OR (95% CI)	P value	Adjusted OR (95% CI)	P value
	No (n = 491)	Possible or definite (n = 29)				
Sonographer experience						
<4 years	229 (47%)	17 (59%)	1.0	-	1.0	-
≥4 years	262 (53%)	12 (41%)	0.6 (0.3-1.3)	0.21	0.7 (0.3-1.5)	0.33
				0.67		0.29
Image quality						
Good	309 (63%)	16 (55%)	1.0	-	1.0	-
Fair	148 (30%)	11 (38%)	1.4 (0.6-3.2)	0.37	1.9 (0.8-4.4)	0.15
Poor	34 (7%)	2 (7%)	1.1 (0.3-5.1)	0.87	2.2 (0.4-11.1)	0.33
				0.44		0.21
Cardiac rhythm						
Regular	421 (86%)	27 (93%)	1.0	-	1.0	-
Atrial fibrillation	57 (11%)	1 (3%)	0.3 (0.04-2.1)	0.21	0.1 (0.01-1.2)	0.076
Other irregular	13 (3%)	1 (3%)	1.2 (0.2-9.5)	0.86	1.0 (0.1-10.1)	1.00
				0.11		0.16
Principal diagnosis						
Congenital HD	12 (2%)	2 (7%)	4.2 (0.7-24.2)	0.11	1.2 (0.1-11.0)	0.85
Hypertensive HD	52 (11%)	1 (3%)	0.5 (0.1-4.3)	0.52	0.6 (0.1-6.0)	0.68
Ischaemic HD	130 (27%)	5 (17%)	0.9 (0.3-3.5)	0.97	1.0 (0.2-4.4)	0.97
Valvular HD	170 (35%)	16 (55%)	2.4 (0.9-6.7)	0.097	3.0 (0.9-9.6)	0.061
Others	127 (26%)	5 (17%)	1.0	-	1.0	-
				0.71		0.050
Number of abnormal findings						
0 to 4	216 (44%)	15 (52%)	1.0	-	1.0	-
5 to 8	192 (39%)	10 (35%)	0.7 (0.3-1.7)	0.49	0.4 (0.1-1.2)	0.099
≥9	83 (17%)	4 (14%)	0.7 (0.2-2.1)	0.53	0.1 (0.02-0.7)	0.014
				0.74		0.61
Severity of disease						
Normal/Borderline	42 (9%)	1 (3%)	1.0	-	1.0	-
Mild	266 (54%)	15 (52%)	2.4 (0.3-18.4)	0.41	2.1 (0.2-18.5)	0.51
Moderate	87 (18%)	6 (21%)	2.9 (0.3-24.8)	0.33	4.1 (0.3-50.0)	0.27
Severe	96 (20%)	7 (24%)	3.1 (0.4-25.7)	0.30	4.7 (0.3-62.5)	0.25
				0.006		0.035
Study complexity						
Complex	11 (2%)	4 (14%)	7.4 (2.2-25.3)	0.001	14.5 (1.8-111.1)	0.011
Intermediate	94 (19%)	6 (21%)	1.3 (0.5-3.3)	0.59	1.7 (0.5-6.3)	0.43
Simple	386 (79%)	19 (66%)	1.0	-	1.0	-

CI: confidence intervals; HD: heart disease; OR: odds ratio

88% of cases, with major differences in only 1%. Even in patients with AF, significant discrepancies were directly attributable to arrhythmia in only 3% of cases. To our knowledge, no previous study has systematically evaluated digital echocardiography in the setting of irregular rhythm. It has been suggested that digital studies may yield a false impression of LV function when there is frequent ectopy or AF;<sup>28</sup> in these patients with beat-to-beat heterogeneity in contraction, more digital information should be recorded.<sup>19</sup> In this study, where a significant 14% of echocardiograms were recorded during irregular rhythm, the acquisition of additional loops and representative cycles appears to have

helped minimise erroneous calls. Additionally, the tomographic nature of echocardiographic imaging, which permits cross-verification of colour Doppler jets, RWM and relevant cardiac structures in multiple planes, reduces the likelihood of missing important information, regardless of prevailing rhythm. Overall, our findings are in agreement with previous reports documenting high concordance rates of between 83% to 99%.<sup>16-19</sup>

Following videotape review, a change in clinical approach was deemed absolutely indicated in only 2% of the overall population. This outcome was independently predicted by the complexity of the examination. Acquisition of additional

loops or unconventional views in complicated cases should therefore improve diagnostic accuracy. This should not imply that less complex studies do not merit careful digitisation. Although less liable to misinterpretation, these still represented a significant source of error because of their overwhelming frequency, as evident from Table 3. Regardless of case complexity, most of the clinically relevant discrepancies encountered were attributable to technical failures in acquisition rather than observer error, emphasising again the importance of a methodical approach to digital echocardiography.

Mitral valve prolapse was most often responsible for apparent discrepancies between digital and videotaped images. This is not surprising given its ubiquity, frequently focal and occasionally transient nature, and the arbitrary criteria used to define prolapse.<sup>29</sup> This diagnosis often poses a management conundrum since the requirement for antibiotic prophylaxis for different subsets of prolapse is not firmly evidence-based.<sup>30</sup> Our results reflect a generally cautious approach, considering prophylaxis possibly important whenever prolapse is diagnosed, and definitely important in the presence of thickened leaflets and significant regurgitation.

#### Limitations

We have used videotaped images as the reference standard. The resolution of uncompressed digital images, however, exceeds that of videotape, while compressed digital images appear comparable or even superior.<sup>26</sup> Thus in theory, a liberal approach to digital image acquisition should yield superior information to analogue recordings. Digital images are also more amenable to frame-by-frame analysis. However, videotape review is familiar to a majority of echocardiographers and is the only accessible method in many institutions worldwide. Furthermore, while digital image storage is not theoretically constrained, the cost of long-term archival is still an important consideration in many developing countries.

Although detailed quantitative and semi-quantitative data were captured, this study was designed to highlight major, clinically relevant differences in echocardiographic diagnoses arising from review of digital and videotaped images rather than to compare differences in measurements made on these images. Such comparisons are also limited by the absence of a reference standard. In theory, digital echocardiography should afford more accurate quantitation on account of its superior resolution and easier frame-by-frame analysis. One study of patients with valvular disease did not, however, demonstrate significant differences in this respect.<sup>24</sup>

The review sequence (digital followed immediately by videotape) was intended to minimise spurious differences

arising from observer variability inherent to staggered reads.<sup>8</sup> This necessarily entails a training effect, as is evident in the high rates of agreement for LV ejection fraction. A follow-up study randomising or reversing the order of reading may yield additional insights but is again limited by the absence of blinding. Our study also does not permit comparisons of time economy between the 2 methods. This was, however, not the aim of our study, having been addressed elsewhere.<sup>20</sup>

Our findings pertain to transthoracic echocardiograms, and not necessarily to transoesophageal and stress studies. The benefits of digitisation may be less readily confirmed for transesophageal echocardiograms, where non-conventional views are often required. On the other hand, digital stress echocardiography is now routinely performed in many laboratories, although there remains concern that a single digitised cine loop may not provide optimal diagnostic accuracy.<sup>31</sup>

#### Conclusions

Any potential for mismanagement arising from exclusive review of clinically compressed digital echocardiographic studies is small, and can be further minimised by attention to technical training. Digital echocardiography, as practiced in a routine clinical environment, offers a patient-safe alternative to conventional videotape review.

*Competing interests: None declared*

#### REFERENCES

1. Thomas JD, Greenberg NL, Garcia MJ. Digital echocardiography 2002: now is the time. *J Am Soc Echocardiogr* 2002;15:831-8.
2. Feigenbaum H. A digital echocardiographic laboratory. *J Am Soc Echocardiogr* 1994;7:105-6.
3. Thomas JD. Digital storage and retrieval: the future in echocardiography. *Heart* 1997;78 Suppl 1:19-22.
4. Main ML, Thomas JD. Digital echocardiography. *Curr Opin Cardiol* 1998;13:404-8.
5. Ehler D, Vacek JL, Bansal S, Gowda M, Powers KB. Transition to an all-digital echocardiography laboratory: a large, multi-site private cardiology practice experience. *J Am Soc Echocardiogr* 2000;13:1109-16.
6. Bansal S, Ehler D, Vacek JL. Digital echocardiography: its role in modern medical practice. *Chest* 2001;119:271-6.
7. Tajik AJ, Seward JB, Hagler DJ, Mair DD, Lie JT. Two-dimensional real-time ultrasonic imaging of the heart and great vessels. Technique, image orientation, structure identification, and validation. *Mayo Clin Proc* 1978;53:271-303.
8. Bolger AF. Do you see what I see? Agreeing to disagree. *J Am Coll Cardiol* 2006;47:129-30.
9. Schiller NB, Shah PM, Crawford M, DeMaria A, Devereux R, Feigenbaum H, et al. Recommendations for quantitation of the left ventricle by two-dimensional echocardiography. American Society of Echocardiography Committee on Standards, Subcommittee on Quantitation of Two-Dimensional Echocardiograms. *J Am Soc Echocardiogr* 1989;2:358-67.
10. Shih T, Lichtenberg R, Jacobs W. Ejection fraction: subjective visual

- echocardiographic estimation versus radionuclide angiography. *Echocardiography* 2003;20:225-30.
11. Lavine SJ, Salacata A. Visual quantitative estimation; semiquantitative wall motion scoring and determination of ejection fraction. *Echocardiography* 2003;20:401-10.
  12. Rich S, Sheikh A, Gallastegui J, Kondos GT, Mason T, Lam W. Determination of left ventricular ejection fraction by visual estimation during real-time two-dimensional echocardiography. *Am Heart J* 1982;104:603-6.
  13. Zoghbi WA, Enriquez-Sarano M, Foster E, Grayburn PA, Kraft CD, Levine RA, et al. Recommendations for evaluation of the severity of native valvular regurgitation with two-dimensional and Doppler echocardiography. *J Am Soc Echocardiogr* 2003;16:777-802.
  14. Thomas JD, Adams DB, Devries S, Ehler D, Greenberg N, Garcia M, et al. Guidelines and recommendations for digital echocardiography. *J Am Soc Echocardiogr* 2005;18:287-97.
  15. Hansen WH, Gilman G, Finnesgard SJ, Wellik TJ, Nelson TA, Johnson MF, et al. The transition from an analog to a digital echocardiography laboratory: the Mayo experience. *J Am Soc Echocardiogr* 2004;17:1214-24.
  16. Mobarek SK, Gilliland YE, Bernal A, Murgu JP, Cheirif J. Is a full digital echocardiography laboratory feasible for routine daily use? *Echocardiography* 1996;13:473-82.
  17. Mohler ER 3rd, Ryan T, Segar DS, Sawada SG, Fineberg NS, Feigenbaum H. Comparison of digital with videotape echocardiography in patients with chest pain in the emergency department. *J Am Soc Echocardiogr* 1996;9:501-7.
  18. Soble JS, Yurow G, Brar R, Stamos T, Neumann A, Garcia M, et al. Comparison of MPEG digital video with super VHS tape for diagnostic echocardiographic readings. *J Am Soc Echocardiogr* 1998;11:819-25.
  19. Segar DS, Skolnick D, Sawada SG, Fitch G, Wagner D, Adams D, et al. A comparison of the interpretation of digitized and videotape recorded echocardiograms. *J Am Soc Echocardiogr* 1999;12:714-9.
  20. Badano LP, Dall'Armellina E, Bordin P, Di Chiara A, Popiel M, Werren M, et al. Feasibility and clinical value of "intelligent" compression and digital storage of transthoracic echocardiograms in day-to-day practice. *Ital Heart J* 2001;2:782-8.
  21. Garcia MJ, Thomas JD, Greenberg N, Sandelski J, Herrera C, Mudd C, et al. Comparison of MPEG-I digital videotape with digitized sVHS videotape for quantitative echocardiographic measurements. *J Am Soc Echocardiogr* 2001;14:114-21.
  22. Shah DJ, Diluzio S, Ambardekar AV, Smulevitz B, Smith GL, Nagaraj A, et al. Evaluation of valvular regurgitation severity using digital acquisition of echocardiographic images. *J Am Soc Echocardiogr* 2002;15:241-6.
  23. Harris KM, Schum KR, Knickelbine T, Hurrell DG, Koehler JL, Longe TF. Comparison of diagnostic quality of motion picture experts group-2 digital video with super VHS videotape for echocardiographic imaging. *J Am Soc Echocardiogr* 2003;16:880-3.
  24. Haluska B, Wahi S, Mayer-Sabik E, Roach-Isada L, Baglin T, Marwick TH. Accuracy and cost- and time-effectiveness of digital clip versus videotape interpretation of echocardiograms in patients with valvular disease. *J Am Soc Echocardiogr* 2001;14:292-8.
  25. Thomas JD. The DICOM image formatting standard: its role in echocardiography and angiography. *Int J Card Imaging* 1998;14 Suppl 1:1-6.
  26. Karson TH, Chandra S, Morehead AJ, Stewart WJ, Nissen SE, Thomas JD. JPEG compression of digital echocardiographic images: impact on image quality. *J Am Soc Echocardiogr* 1995;8:306-18.
  27. Spencer K, Solomon L, Mor-Avi V, Dean K, Weinert L, Gulati M, et al. Effects of MPEG compression on the quality and diagnostic accuracy of digital echocardiography studies. *J Am Soc Echocardiogr* 2000;13:51-7.
  28. Thomas JD, Main ML. Digital echocardiographic laboratory: where do we stand? *J Am Soc Echocardiogr* 1998;11:978-83.
  29. Freed LA, Levy D, Levine RA, Larson MG, Evans JC, Fuller DL, et al. Prevalence and clinical outcome of mitral-valve prolapse. *N Engl J Med* 1999;341:1-7.
  30. Dajani AS, Taubert KA, Wilson W, Bolger AF, Bayer A, Ferrieri P, et al. Prevention of bacterial endocarditis: recommendations by the American Heart Association. *Clin Infect Dis* 1997;25:1448-58.
  31. Attenhofer CH, Pellikka PA, Oh JK, Roger VL, McCully RB, Shub C, et al. Is review of videotape necessary after review of digitized cine-loop images in stress echocardiography? A prospective study in 306 patients. *J Am Soc Echocardiogr* 1997;10:179-84.
-