

Late Complications Following Tetralogy of Fallot Repair: The Need for Long-term Follow-Up

Kay Woon Ho,¹MBBS, MRCP, MMed, Ru San Tan,¹MBBS, MRCP, FAMS, Keng Yean Wong,²MBBS, MMed (Paed), FAMS, Teng Hong Tan,² MBBS, MMed (Paed), Sriram Shankar,³MBBS, FRCS (UK), FAMS, Ju Le Tan,¹MBBS, MRCP, FAMS

Abstract

Introduction: We report a series of operated tetralogy of Fallot (TOF) patients focusing on complications and outcomes. **Materials and Methods:** Data from TOF patients seen at our centre's adult congenital heart disease clinic was analysed. **Results:** There were 21 patients; the mean age was 32.2 ± 12.4 years; the age at first operation was 9.0 ± 7.9 years; the mean postoperative follow-up duration was 23.5 ± 12.1 years; and the current New York Heart Association (NYHA) status: I, 82%; II, 4%; III, 14%. Fourteen patients had complete operative notes. All these patients underwent total TOF correction; 2 had staged aortopulmonary shunt with total correction at a mean of 3.2 years later, pulmonary artery patch augmentation in 8 patients and pulmonary valvotomy in 8 patients. Three patients required pulmonary valve homograft replacement for severe pulmonary regurgitation (PR) at 13, 28 and 36 years after the initial corrective operation. Current investigations: RBBB on ECG (91%), QRS duration 137 ± 29 ms. Echocardiography showed dilated right ventricular end-diastolic (RVED) diameters (3.2 ± 0.8 cm); severe PR (67%), residual right ventricular outflow tract obstruction (RVOTO) (42%) and VSD patch leakage (9%). Cardiac magnetic resonance (CMR) (8 patients) showed dilated RVED volumes 252.6 ± 93.8 mL, indexed RV volume 165.7 ± 34.8 mL; RV systolic function was preserved in most patients with a RV ejection fraction of $49.5 \pm 5.7\%$. One patient had atrial tachycardia and another had frequent non-sustained ventricular tachycardia that required radiofrequency ablation. **Conclusion:** Patients with TOF who had full corrective surgery during childhood are now surviving into adulthood. Many challenges arising from complications in the postoperative period remain. It is imperative that adult TOF patients should have regular follow-up to monitor development and subsequent management of these complications.

Ann Acad Med Singapore 2007;36:947-53

Key words: Cardiovascular abnormalities, Congenital, Heart defects

Introduction

Tetralogy of Fallot (TOF) is the most common cyanotic congenital heart disease with an incidence of approximately 0.5/1000 live births (5% to 7% of congenital heart lesions). In Singapore with a live birth of over 37, 000 per year,¹ the expected number of new TOF cases will be approximately 19 per year. Based on data obtained from the National Birth Defects Registry, there were 164 TOF cases amongst all live and stillbirths between 1994 and 2000.² In classical TOF, an anterior and cephalic displacement of the infundibular septum results in a large ventricular septal defect (VSD) and the development of infundibular pulmonary stenosis. Right ventricular (RV) hypertrophy is associated with both pulmonary stenosis and VSD (Fig. 1). Without surgical intervention, most patients die in childhood

with a rate of survival of 66% at 1 year of age, 40% at 3 years, 11% at 20 years and 3% at 40 years.³ The advent of surgical repair which includes closure of the VSD and relief of RV outflow tract (RVOT) obstruction has greatly improved the long-term survival of TOF patients. Complete repair of TOF in early childhood is now routinely available in tertiary centres in Singapore. High survival rates in TOF patients who underwent complete repair have been reported.^{4,5}

Nevertheless, a myriad of potential complications have been reported in operated TOF patients that underlie the importance of long-term follow-up after surgery even if they remain asymptomatic. These complications include rhythm and conduction disorders such as sudden cardiac deaths,⁶⁻¹⁰ pulmonary regurgitation (PR) with RV dilatation

¹ Department of Cardiology, National Heart Centre, Singapore

² Department of Paediatric Cardiology, KK Women's and Children's Hospital, Singapore

³ Department of Paediatric Cardiothoracic Surgery, KK Women's and Children's Hospital, Singapore

Address for Correspondence: Dr Ju Lee Tan, National Heart Centre, 17 Third Hospital Avenue, Singapore 167852.

Email: Tan_Ju_Le@nhc.com.sg

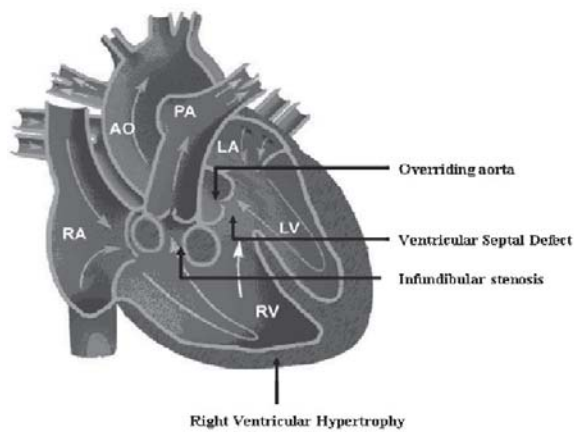


Fig. 1. Tetralogy of Fallot.

Table 1. Documented Operative Procedures (n = 14)

Procedure	No. of patients (%)
VSD closure	14 (100%)
Closure of previous palliative shunt	2 (14%) (1 Blalock-Taussig shunt and 1 Waterston shunt)
Infundibulectomy only	6 (43%)
Infundibulectomy and valvotomy	8 (57%)
Valvotomy only	0
Pulmonary outflow patch	8 (57%) (Patch up to pulmonary valve annulus in 2 patient and through pulmonary valve annulus in 6 patients)
No patch	6 (43%)

VSD: ventricular septal defect

and dysfunction,^{11,12} aneurysm formation and rupture at the site of RV outflow tract repair,¹³ residual or recurrent obstruction of the RVOT, VSD patch leakage¹⁴ and aortic regurgitation (AR).¹⁵

We report a case series of 21 patients followed-up in our centre's adult congenital heart disease clinic to evaluate the incidence and significance of complications after total corrective surgery.

Materials and Methods

Data from surgically corrected TOF patients seen at our centre's adult congenital heart disease clinic were obtained from patient records using a predetermined data collection form. Information collected from the records include patients' demographics, operative details, postoperative functional status, electrocardiogram (ECG), Holter, transthoracic echocardiogram and cardiac magnetic resonance (CMR) imaging results as well as data on

subsequent hospitalisations, repeat operations, arrhythmias, heart failure as well as death following initial corrective surgery. Data collated were analysed using SPSS version 13, SPSS Inc., Chicago, IL.

Electrocardiography

ECG parameters were obtained prior to operation (if available) and during follow-up. These include the averaged QRS duration, determination of QRS axis, presence of intraventricular conduction delay or bundle branch blocks and presence or absence of atrial or ventricular arrhythmias. ECG was obtained using Marquette ECG machines.

Holter Recordings

Holter recordings were conducted for patients with symptoms suggestive of arrhythmias such as palpitation and syncope. Holter parameters were obtained if the patients had undergone such recordings post-repair. These include the presence of arrhythmias and the duration of pauses.

Echocardiography

The latest available transthoracic echocardiographical data from each patient was analysed. Parameters obtained included dimensions of the aortic root, ascending and descending thoracic aorta; presence and severity of valvular regurgitation (especially pulmonary and tricuspid regurgitation) using Doppler and colour flow quantifications, right and left ventricular dimensions, left ventricular ejection fraction (LVEF) as well as presence of any residual VSD or RVOT obstruction. Right and left ventricular end diastolic dimensions were measured from endocardial surface to endocardial surface using M-mode echocardiography based on American Society of Echocardiography guidelines.¹⁶ From the continuous-wave Doppler, duration of pulmonary regurgitation as well as duration of total diastole were measured and the ratio between the 2 was defined as the pulmonary regurgitation index (PRi). Doppler-measured PRi was previously found to correlate closely with CMR regurgitant fraction. A PRi <0.77 had 100% sensitivity and 84.6% specificity for identifying patients with pulmonary regurgitant fraction >24.5%, with a predictive accuracy of 95%.¹⁷ Pulmonary pressure halftime <100 ms is useful in identifying haemodynamically significant regurgitation.¹⁸ Tricuspid annular plane systolic excursion (TAPSE) is a measurement of right ventricular long axis function previously found to correlate closely with right ventricular ejection fraction measure using radionuclide angiography.¹⁹ TAPSE measurement of ≥ 20 mm is normal. Right ventricular dilatation index (RVDi) (ratio of RV end diastolic dimension and LV end diastolic dimension) was previously reported to correlate with severity of pulmonary regurgitation. RVDi ≤ 0.5 is normal.²⁰

Table 2. Transthoracic Echocardiography Parameters (n = 21)

Parameter	No. (%)
Pulmonary regurgitation	
1) Colour flow mapping	
Mild	5 (23%)
Moderate	2 (10%)
Severe	14 (67%)
Mean (\pm SD)	
2) PR pressure half time (ms)	63.1 (\pm 29.8)
3) PR index	0.59 (\pm 0.19)
Right ventricular	
1) RV end diastolic dimension (cm)	
	3.2 (\pm 0.8)
2) Tricuspid annular plane systolic excursion (TAPSE) (mm)	
	20.7 (\pm 4.9)
3) RV inlet dimension (cm)	
	4.1 (\pm 0.9)
4) Right ventricle dilatation index (RVDi)	
	0.77 (\pm 0.22)
Left ventricular	
1) LV inlet dimension (cm)	
	3.7 (\pm 0.3)
2) LV ejection fraction (%)	
	59.6 (\pm 6.0)

LV: left ventricular; PR: pulmonary regurgitation; RV: right ventricular; RVDi: right ventricular dilatation index

Cardiac Magnetic Resonance Imaging

CMR imaging were performed in patients postoperatively especially for patients with moderate-to-severe PR and parameters obtained included biventricular ejection fraction, end systolic and end diastolic volumes, stroke volumes, ventricular mass, presence and severity of valvular regurgitation as well as complications of residual VSD and RVOT obstruction. CMR imaging were performed using Magnetom Avanto, Siemens.

Results

Data were obtained from 21 patients who underwent operative correction for TOF who were followed-up in the adult congenital heart disease clinic.

Demographics

The mean age of the cohort was 32.2 ± 12.4 years. There were 9 female patients. All patients were Chinese except 3, who were Malay.

Operative Details

Complete operation notes at the time of reparative surgery were available for 14 patients (Table 1). The age of first operation was 9.0 ± 7.9 years. The oldest age of complete repair was 32 years. The operative procedures performed included repair of VSD, infundibulectomy with or without

valvotomy, patch augmentation of the infundibulum up to the annulus or through the annulus. In all but 2 patients, VSD repair was done using the transatrial or transpulmonary approach. The remaining 2 patients had repair done via right ventriculotomy. The transatrial or transpulmonary approach has replaced the earlier method of repair via right ventriculotomy as there is less direct myocardial damage and reduced initial postoperative PR prolongation. Associated cardiac defects in 7 patients were repaired at the same time, including atrial septal defect (ASD), patent foramen ovale (PFO) closure in 6 patients and ligation of patent ductus arteriosus (PDA) in 2 patients. The mean postoperative follow-up duration was 23.5 ± 12.1 years. Most of the patients were in New York Heart Association (NYHA) class I (82%) during the last follow-up consultation; 4% were in NYHA II and 14% in NYHA III.

Electrocardiography and Holter Recordings

ECG showed RBBB on 91% of the patients; mean QRS duration 137 ± 29 ms (>180 ms in 1 patient). Three patients underwent 24-hour Holter monitoring for persistent palpitation. Atrial tachycardia and frequent premature ventricular complexes were found in 1 patient. In another, frequent episodes of non-sustained ventricular tachycardia were detected. The 24-hour Holter study was normal in the third patient.

Echocardiography

Transthoracic echocardiography was conducted in all 21 patients postoperatively. The last follow-up echocardiogram was done 21.2 ± 8.8 years after the initial operation (Table 2). Aortic measurements were normal except for a mild increase in the diameter at the level of the sinus of Valsalva. Measurements for sinus of Valsalva, sinotubular junction and ascending aorta were 3.6 ± 0.6 cm, 3.1 ± 0.7 cm and 3.1 ± 0.6 cm respectively. Only trivial or mild degrees of aortic regurgitation were found for all patients. The measurement of the main pulmonary artery, right pulmonary artery and left pulmonary artery were 2.3 ± 0.6 cm, 1.5 ± 0.3 cm and 1.5 ± 0.4 cm respectively. One patient had a narrowed main pulmonary artery, 2 had a narrowed left pulmonary artery and 1 had a narrowed right pulmonary artery. Narrowed right and left pulmonary arteries measured from 0.6 cm to 1.0 cm. Two-thirds of the patients had severe PR assessed using colour flow mapping. In our study the mean PRi was 0.59 ± 0.19 and the mean TAPSE was 20.7 ± 4.9 mm. Patients with mild PR had a mean TAPSE of 27.0 ± 7.1 mm while those with severe PR had a mean TAPSE of 18.5 ± 3.2 mm. The average RVDi was 0.77 ± 0.22 . Patients with mild PR had a mean RVDi of 0.55 ± 0.22 while those with severe PR had a mean RVDi of 0.86 ± 0.18 . None of the patients had RVDi >2 . The right ventricular systolic pressure was 34.9 ± 9.5 mm Hg.

Table 3. CMR Parameters for Patients With Moderate-to-severe PR (n = 8)

Parameter	Right ventricular Mean (\pm SD) [Normal range]	Left ventricular Mean (\pm SD) [Normal range]
Ejection fraction (%)	49.5 (\pm 5.7) [47-80%]	57.6 (\pm 6.5) [56-87%]
End diastolic volume (cm ³)	252.6 (\pm 93.8) [58-227 cm ³]	115.4 (\pm 27.9) [52-195 cm ³]
Indexed end diastolic volume (mL/m ²)	165.7 (\pm 34.8)	67.5 (\pm 13.8)
End systolic volume (cm ³)	148.4 (\pm 21.5) [12-103 cm ³]	49.9 (\pm 18.1) [13-72 cm ³]
Indexed end systolic volume (mL/m ²)	88.0 (\pm 22.0) [<95 mL/m ²]	30.6 (\pm 6.5) [<50 mL/m ²]
Stroke volume (cm ³)	124.6 (\pm 19.2) [35-138 cm ³]	63.5 (\pm 12.7) [33-133 cm ³]
Mass	–	69.9 (\pm 24.6)
RV/LV Indexed volume		
RV/LV end diastolic volume index (RVEDV/LVEDV)		2.2 (\pm 0.8)
RV/LV end systolic volume index (RVESV/LVESV)		3.2 (\pm 0.9)

CMR: cardiac magnetic resonance; LV: left ventricular; PR: pulmonary regurgitation; RV: right ventricular

Two patients were found to have VSD patch leakage during follow-up echocardiogram examination post-repair. The degree of leakage was found to be small in both cases.

Nine patients had residual or recurrent RVOT obstruction. Of these, 4 had residual pulmonary valve stenosis while the rest had supra-ventricular stenosis. The degree of stenosis was mild in 6 patients with a peak systolic pressure gradient (PPG) across the stenosis of between 11 and 30 mm Hg. Two patients had moderately severe pulmonary stenosis with PPG 73 and 76 mm Hg respectively. The remaining patient with severe pulmonary stenosis had PPG of 99 mm Hg.

Cardiac Magnetic Resonance Imaging

CMR was done in 8 patients 22.5 ± 9.6 years after the initial operation. Patients who underwent CMR had moderate-to-severe PR on echocardiography. Table 3 lists the findings on CMR. Left ventricular size and function were generally normal. Measurements of the right ventricular dimensions showed dilated RV in all patients. Two patients had mild RV dilatation with indexed end diastolic RV volume measuring 97 and 119 mL/m² respectively. The rest of the patients had severe RV dilatation with indexed end diastolic RV volume ranging from 148 to 218 mL/m². RV systolic function was still preserved in most patients with

a mean RV ejection fraction of $49.5 \pm 5.7\%$ (normal range, 47% to 80%). One patient with severe residual severe pulmonary valvular stenosis, free pulmonary regurgitation and mild VSD leakage had reduced RV ejection of 40%. All the other patients had RVEF of at least 47%.

Complications Following TOF Repair

The number and types of complications following TOF repair are listed in Table 4. Three patients required repeat operations after the initial complete correction of TOF. All had pulmonary valve replacement using homografts at a mean of 29 years after total correction due to progressive right ventricular dilatation and severe reduction of exercise tolerance. One of the 3 patients underwent subendocardial resection of RVOT obstruction in the same operation. Another patient had resection of residual pulmonary stenosis 3 years after initial corrective TOF surgery followed by pulmonary valvular homograft implantation 4 years later and balloon dilatation of suprapulmonary stenosis 1 year later.

One patient had atrial tachycardia that required radiofrequency ablation. Another had non-sustained ventricular tachycardia initially treated medically, but then underwent electrophysiological study and radiofrequency ablation 12 years after the corrective operation.

Table 4. Incidence of Complications Post-repair (n = 21)

Complication	No. (%)
Pulmonary regurgitation	
Mild	4 (19%)
Moderate	3 (14%)
Severe	15 (71%)
Residual or recurrent RVOT obstruction	9 (42%)
RV dilatation	21 (100%)
VSD patch leakage	2 (10%)
Reoperation	3 (14%)
Pulmonary valve replacement (homograft)	
Persistent atrial arrhythmias	1 (5%)
Persistent atrial tachycardia requiring electrophysiological study and radiofrequency ablation (EPS/RFA)	
Persistent ventricular arrhythmias	1 (5%)
Non sustained ventricular tachycardia requiring EPS/RFA	

EPS: electrophysiological study; RFA: radiofrequency ablation; RV: right ventricular; RVOT: residual right ventricular outflow tract; VSD: ventricular septal defect

Discussion

Complications of varying severity occur almost invariably after TOF repair leading to considerable morbidity and even mortality. In our cohort of TOF patients, the most commonly occurring complications were pulmonary regurgitation, residual RVOT obstruction, VSD patch leakage and arrhythmias.

Pulmonary Regurgitation/Right Ventricular Dilatation

PR complicating surgical repair of TOF is common in all patients, with over 80% having at least moderate-to-severe PR. PR has been shown to be related to the use of transannular patch during RVOT reconstruction and aggressive infundibulectomy involving the pulmonary valve annulus.¹¹ Four out of 5 patients in our series with mild PR had infundibulectomy only without the involvement of the pulmonary valve annulus. Although PR has been reported to be well-tolerated in several clinical studies,^{21,22} long-term follow-up has shown that this can lead to considerable disability. The adverse effects of PR include progressive dilatation of RV, reduced exercise capacity, arrhythmia and sudden death.¹¹

PR is known to be exacerbated by concomitant conditions that elevate pulmonary systolic pressure. These include branch pulmonary artery stenosis, left ventricular dysfunction and acquired bronchopulmonary diseases. In our series, all patients with branch pulmonary artery stenosis had severe PR.

Investigations for PR include the use of ECG, echocardiography, CMR and exercise treadmill. QRS prolongation with rSr morphology in the right precordial lead reflect right ventricular volume overload. Although the presence of RBBB in post TOF repair is extremely common (91% in our study) and may mask the presence of RV hypertrophy, progressive lengthening of QRS duration with time reflects RV enlargement and potential RV failure.¹¹ Comparing patients with PRi ≥ 0.77 (mild PR) and those with PRi < 0.77 (significant PR), the mean QRS duration was 115 ± 29 ms and 142 ± 27 ms respectively. Three patients who underwent PVR had a mean QRS duration of 156 ms. Progressive lengthening of the QRS duration over time can help identify patients who have progressive right ventricular dilatation and timing of PVR.

Echocardiography can detect and quantify the severity of PR and the corresponding degree of RV dilatation. The mean RV end diastolic dimension (RVEDD) measured on echocardiography between patients with mild PR to those with severe PR was found to be 2.7 ± 1.0 cm and 3.5 ± 0.7 cm respectively. Severe PR results in volume overload of the RV and progressive dilatation over time. Serial measurements can help identify patients who may require PVR.

Late pulmonary valve replacement (PVR) has been shown to reduce RV dimension and improve RV systolic function as well as functional status.²³⁻²⁶ In our study, 3 patients underwent PVR 13, 28 and 36 years after complete repair. All 3 patients were in NYHA class III prior to PVR but improved dramatically post-replacement to NYHA class I. All patients documented a reduction of RV end diastolic dimension from 3.8 ± 0.7 cm to 2.9 ± 0.7 cm on echocardiography.

The timing of pulmonary valve replacement is crucial especially in young patients as these valve replacements have a limited lifespan. The decision regarding the timing of pulmonary valve replacement is based on a combination of both clinical as well as investigational features. Factors determining the decision for valvular replacement include clinical deterioration of functional status, serial deterioration of exercise capacity on treadmill testing, serial prolongation of QRS duration on ECG, echocardiographic evidence of severe PR as suggested by PRi < 0.77 ,¹⁷ pulmonary pressure half time < 100 ms,¹⁸ right ventricular dilatation index, RVDi (ratio of RV end diastolic dimension and LV end diastolic dimension) > 2 ²⁰ and right ventricular dysfunction suggested by TAPSE < 20 mm; CMR evidence of severe or free PR is suggested by measurement of pulmonary regurgitant fraction $> 40\%$,¹¹ significant RV dilatation as suggested by index right ventricular end diastolic volume (RV end diastolic volume/BSA) > 150 mL/m^{2.27} and RV systolic dysfunction (RV ejection fraction $< 40\%$).

Residual RVOT Obstruction

Residual RVOT obstruction can persist after initial corrective surgery due to hypertrophied muscle in the subvalvular region, annular hypoplasia, pulmonary valve stenosis, or branch pulmonary artery stenosis.²⁸ Mild obstruction is usually well tolerated, but significant obstruction may require reoperation or catheter-based intervention. In our study, 6 out of 9 patients with recurrent or residual RVOT obstruction had mild degree of stenosis and were treated expectantly. Two patients with moderate degree of RVOT obstruction were functionally asymptomatic (NYHA I) and did not require surgical intervention. The remaining patient with severe pulmonary stenosis had PPG of 99 mm Hg measured on transthoracic echocardiogram 23 years after initial total correction for which he underwent reparative surgery in 2000. This patient also had severe pulmonary regurgitation and due to deteriorating NYHA class status, received a pulmonary homograft in 2004. A year later, he developed significant suprapulmonary stenosis with PPG of 70 mm Hg. He underwent subsequent balloon dilatation of the suprapulmonary artery stenosis with residual mild stenosis of 48 mm Hg.

The use of shunts, such as the Blalock Taussig shunt, is associated with pulmonary artery hypoplasia and pulmonary artery distortion.²⁹ However, the 2 patients who had prior shunt operations before complete repair in our series did not have pulmonary artery stenosis.

VSD Patch Leakage

VSD patch leakage was detected in 2 patients 22 and 26 years after complete repair during echocardiography and CMR examinations respectively. The leakage was detected by echocardiography in 1 patient and by CMR in the other. In both cases, the residual leak was small and did not require repeat operation.

Arrhythmias

Arrhythmias and sudden cardiac death remain the most common cause of death after repair of TOF.²² Risk factors for sudden cardiac death post-TOF repair include older age at the time of surgical repair,⁷ those with moderate-to-severe PR,⁹ systolic and diastolic dysfunction or prolongation of QRS duration (to >180 ms).¹⁰ Other arrhythmias including atrial tachyarrhythmias or rarely complete heart block may also be present.

In our study, 1 patient had non-sustained ventricular tachycardia documented on Holter. This patient had undergone complete repair at the age of 8 years but had severe PR postoperatively that eventually required PVR. ECG showed a pre-PVR QRS duration of 155 ms. She was initially treated with sotalol but had persistent symptoms of palpation. Electrophysiological study and radiofrequency

ablation (EPS/RFA) of VT was eventually done with cessation of palpitation and no further documentation of non-sustained VT on subsequent Holter studies.

Another patient who had non-sustained atrial tachycardia documented on Holter study and persistent symptoms despite medication underwent successful radiofrequency ablation. She remained asymptomatic after EPS/RFA.

Conclusion

Patients with TOF who had full corrective surgery during childhood are now surviving into adulthood. Many challenges remain arising from complications such as severe pulmonary regurgitation, right ventricular dilatation, RVOT obstruction, VSD patch leakage, arrhythmias and sudden cardiac death. It is imperative that adult TOF patients should have regular follow-up to monitor development and subsequent management of these complications.

REFERENCES

1. Population Trends 2005. Singapore: Department of Statistics.
2. Tan KH, Tan TY, Tan J, Tan I, Chew SK, Yeo GS. Birth defects in Singapore: 1994-2000. *Singapore Med J* 2005;46:545-52.
3. Bertranou EG, Blackstone EH, Hazelrig JB, Turner ME, Kirklind JW. Life expectancy without surgery in tetralogy of Fallot. *Am J Cardiol* 1978;42:458-66.
4. Murphy JG, Gersh BJ, Mair DD, Fuster V, McGoon MD, Ilstrup DM, et al. Long-term outcome in patients undergoing surgical repair of tetralogy of Fallot. *N Engl J Med* 1993;329:593-9.
5. Knott-Craig CJ, Elkins RC, Lane MM, Holz J, McCue C, Ward KE. A 26-year experience with surgical management of tetralogy of Fallot: risk analysis for mortality or late reintervention. *Ann Thorac Surg* 1998;66:506-11.
6. Roos-Hesselink J, Perloff MG, McGhie J, Spitaels S. Atrial arrhythmias in adults after repair of tetralogy of Fallot: correlations with clinical, exercise, and echocardiographic findings. *Circulation* 1995;91:2214-9.
7. Chandar JS, Wolff GS, Garson A Jr, Bell TJ, Beder SD, Bink-Boelkens M, et al. Ventricular arrhythmias in postoperative tetralogy of Fallot. *Am J Cardiol* 1990;65:655-61.
8. Vaksman G, Fournier A, Davignon A, Ducharme G, Houyel L, Fournon JC. Frequency and prognosis of arrhythmias after operative "correction" of tetralogy of Fallot. *Am J Cardiol* 1990;66:346-9.
9. Zahka KG, Horneffer PJ, Rowe SA, Neill CA, Manolio TA, Kidd L, et al. Long-term valvular function after total repair of tetralogy of Fallot: relation to ventricular arrhythmias. *Circulation* 1988;78:Suppl III:III-14-III-19.
10. Gatzoulis MA, Till JA, Somerville J, Redington AN. Mechano-electrical interaction in tetralogy of Fallot: QRS prolongation relates to right ventricular size and predicts malignant ventricular arrhythmias and sudden death. *Circulation* 1995;92:231-7.
11. Bouzas B, Kilner PJ, Gatzoulis MA. Pulmonary regurgitation: not a benign lesion. *Eur Heart J* 2005;26:433-9.
12. Davlouros PA, Karatza AA, Gatzoulis MA, Shore DF. Timing and type of surgery for severe pulmonary regurgitation after repair of tetralogy of Fallot. *Int J Cardiol* 2004;97Suppl1:91-101.
13. Seybold-Epting W, Chiariello L, Hallman GL, Cooley DA. Aneurysm of

- pericardial right ventricular outflow tract patches. *Ann Thorac Surg* 1977;24:237-40.
14. Rosenthal A. Adults with tetralogy of Fallot – repaired, yes; cured, no. *N Engl J Med* 1993;329:655-6.
 15. Niwa K, Siu SC, Webb GD, Gatzoulis MA. Progressive aortic root dilatation in adults late after repair of tetralogy of Fallot. *Circulation* 2002;106:1374-8.
 16. Schiller NB, Shah PM, Crawford M, DeMaria A, Devereux R, Feigenbaum H, et al. Recommendations for quantitation of the left ventricle by two-dimensional echocardiography. American Society of Echocardiography Committee on Standards, Subcommittee on Quantitation of Two-Dimensional Echocardiograms. *J Am Soc Echocardiogr* 1989;2:358-67.
 17. Li W, Davlouros PA, Kilner PJ, Pennell DJ, Gibson D, Henein MY, et al. Doppler-echocardiographic assessment of pulmonary regurgitation in adults with repaired tetralogy of Fallot: comparison with cardiovascular magnetic resonance imaging. *Am Heart J* 2004;147:165-72.
 18. Silversides CK, Veldtman GR, Crossin J, Merchant N, Webb GD, McCrindle BW, et al. Pressure half-time predicts hemodynamically significant pulmonary regurgitation in adult patients with repaired tetralogy of fallot. *J Am Soc Echocardiogr* 2003;16:1057-62.
 19. Kaul S, Tei C, Hopkins JM, Shah PM. Assessment of right ventricular function using two-dimensional echocardiography. *Am Heart J* 1984;107:526-31.
 20. Borowski A, Ghodsizad A, Litmathe J, Lawrenz W, Schmidt KG, Gams E. Severe pulmonary regurgitation late after total repair of tetralogy of Fallot: surgical considerations. *Pediatr Cardiol* 2004;25:466-71.
 21. Shimazaki Y, Blackstone EH, Kirklin JW. The natural history of isolated congenital pulmonary valve incompetence: surgical implications. *Thorac Cardiovasc Surg* 1984;32:257-9.
 22. Kirklin JK, Kirklin JW, Blackstone EH. Effect of transannular patching on outcome after repair of tetralogy of Fallot. *Ann Thorac Surg* 1989;48:783-91.
 23. Bove EL, Kavey RE, Byrum CJ, Sondheimer HM, Blackman MS, Thomas FD. Improved right ventricular function following late pulmonary valve replacement for residual pulmonary insufficiency or stenosis. *J Thorac Cardiovasc Surg* 1985;90:50-5.
 24. Eyskens B, Reybrouck T, Bogaert J, Dymarkowsky S, Daenen W, Dumoulin M. Homograft insertion for pulmonary regurgitation after repair of tetralogy of fallot improves cardiorespiratory exercise performance. *Am J Cardiol* 2000;85:221-5.
 25. Yemets IM, Williams WG, Webb GD, Harrison DA, McLaughlin PR, Trusler GA, et al. Pulmonary valve replacement late after repair of tetralogy of Fallot. *Ann Thorac Surg* 1997;64:526-30.
 26. Nollert G, Fischlein T, Bouterwek S, Bohmer C, Klinner W, Reichart B. Long-term survival in patients with repair of tetralogy of Fallot: 36-year follow-up of 490 survivors of the first year after surgical repair. *J Am Coll Cardiol* 1997;30:1374-83.
 27. Dave HH, Buechel ER, Dodge-Khatami A, Kadner A, Rousson V, Bauersfeld U, et al. Early insertion of a pulmonary valve for chronic regurgitation helps restoration of ventricular dimensions. *Ann Thorac Surg* 2005;80:1615-20.
 28. Hennein HA, Mosca RS, Urcelay G, Crowley DC, Bove EL. Intermediate results after complete repair of tetralogy of Fallot in neonates. *J Thorac Cardiovasc Surg* 1995;109:332-42.
 29. Gladman G, McCrindle BW, Williams WG, Freedom RM, Benson LN. The modified Blalock-Taussig shunt: clinical impact and morbidity in Fallot's tetralogy in the current era. *J Thorac Cardiovasc Surg* 1997;114:25-30.