

The Role of Electrophysiology in the Diagnosis and Management of Cervical Spondylotic Myelopathy

Yew-Long Lo,¹ MBBS, MMed (Int Med), FAMS

Abstract

Background: Cervical spondylotic myelopathy (CSM) is managed by conservative or surgical measures. While surgery is often performed in cases of longstanding or severe CSM, there is a lack of evidence concerning its efficacy. Transcranial magnetic stimulation (TMS) is a quick, safe, painless and non-invasive technique to study conduction in the descending corticospinal pathways in the spinal cord. The conduction time from the motor cortex to the anterior horn cell [central motor conduction time (CMCT)] is a measure of the integrity of corticospinal pathways. We have previously established the role of TMS in diagnosis and screening of CSM. In this study, we further investigate the use MEPs obtained with TMS in the outcome prediction of severe CSM patients requiring operative intervention. **Methods:** We prospectively evaluated 46 consecutive patients (mean age, 57.6 years; range, 36 to 84 years; 28 men) presenting with clinical features of CSM over a 2-year period. Disease duration ranged from 6 to 24 months. A total of 45 healthy controls were studied for comparison. All patients underwent clinical scoring. Patients' initial clinical score (S1) and postoperative scoring at 6 months (S2) were based on a modified Japan Orthopedic Association Scoring Scale. A Modified Recovery Rate (MRR) was calculated based on the formula: $(S2 - S1/17 - S1) \times 100$. We regarded a good surgical outcome as MRR of 50 or above. This was depicted as MRR50. The patients were separated into 4 groups according to the degree of cord compression by degenerative osteo-cartilaginous elements at the most significant level on MRI. TMS studies were performed before surgery. Each investigator was blinded to the results of the other investigators. **Results:** The upper limb (UL) CMCT ($r = -0.507, P < 0.0005$) and lower limb (LL) CMCT ($r = -0.452, P = 0.002$) were significantly and negatively correlated with S1. Similarly, UL MEP amplitude ($r = 0.494, P < 0.0005$) and LL MEP amplitude ($r = 0.305, P = 0.039$) were significantly correlated with S1. Surgery consisted of anterior or posterior decompression with cervical laminoplasty, performed by an experienced team of orthopaedic surgeons. No significant intraoperative or postoperative complications were documented. Surgery resulted in significantly improved clinical scoring (unpaired t test, $P < 0.0005$). No correlation between clinical scoring with patients' age, disease duration, severity or levels of cord compression on MRI was found. ULCMCT and MEP amplitude abnormality were significantly associated with improvement in clinical scoring after surgery (Mann-Whitney test, $P < 0.05$). The UL CMCT was the independent predictor of a good clinical outcome after surgery (odds ratio, 9.09; $P = 0.011$). **Conclusions:** In early CSM, lateral corticospinal tracts are first to be affected. It is thus possible that UL CMCT abnormality reflect more severe affection of the corticospinal tracts placed relatively more medially in the cervical cord. Surgical intervention may have then effectively relieved the clinically significant compression, leading to a better outcome. This was further corroborated by our finding of negative correlation of S1 with UL CMCT, suggesting that patients who were clinically more severe were also electrophysiologically more abnormal, and subsequently benefited more from surgical decompression relative to patients with normal UL CMCT. This the largest series, to our knowledge, showing for the first time that UL CMCT abnormality obtained with TMS is an independent predictor of good surgical outcome in severe CSM.

Ann Acad Med Singapore 2007;36:886-93

Key words: Cervical spondylosis, Surgery, Severe, Outcome, Transcranial magnetic stimulation, Motor-evoked potential, Magnetic resonance imaging

¹ Department of Neurology, National Neuroscience Institute, Singapore

Address for Correspondence: A/Prof Yew-Long Lo, Department of Neurology, National Neuroscience Institute, Singapore General Hospital, Outram Road, Singapore 169608.

Email: lo.yew.long@sgh.com.sg

Cervical spondylosis is an extremely common condition managed by both physicians and surgeons in daily clinical practice. Cervical spondylotic myelopathy (CSM), resulting from longstanding degenerative impingement of the spinal cord and nerve roots by osteo-cartilagineous elements, is managed by conservative or surgical methods.¹ While surgery is often performed in cases of longstanding or severe CSM, there is a lack of evidence concerning its efficacy.²

In the surgical management of CSM, careful selection of patients is an important factor affecting clinical outcome.³ Previous studies have utilised somatosensory evoked potentials,^{4,5} magnetic resonance imaging (MRI) changes,⁶ computed tomography (CT) myelogram⁷ and even hyperbaric oxygen,⁸ to correlate with recovery rates, but only after CSM surgery has been performed. However, pre-operative prediction of CSM surgical outcome with transcranial magnetic stimulation (TMS) has not been investigated to date.

TMS is a quick, safe, painless and non-invasive technique to study conduction in the descending corticospinal pathways.^{9,10} It involves motor cortex stimulation by means of magnetic flux. The conduction time from the motor cortex to the anterior horn cell [central motor conduction time (CMCT)] is a measure of the integrity of corticospinal pathways. In a previously published large study of over 100 patients, we showed that TMS findings had good correlation with severity of cord compression seen on MRI.¹¹ This study established the role of TMS for the functional evaluation of CSM in clinical practice. In a follow-up study, we validated our previous findings by showing that motor evoked potentials (MEPs) from the pectoralis major obtained with TMS can increase the diagnostic yield of cord compression in cervical spondylosis.¹² CMCT from MEPs obtained with TMS can thus be a useful adjunct in the electrophysiological evaluation of CSM. With this scientific background, we prospectively evaluated 231 patients with cervical spondylosis in the largest study to date, correlating clinical, electrophysiological and MRI findings. This study showed that TMS had a 98% sensitivity and specificity for cord abnormality, using MRI as the reference standard. The findings pointed to the value of TMS as a rapid, inexpensive and non-invasive technique for screening patients with cervical spondylosis before MRI.¹³ The role of electrophysiology have also been extended into the operating theatre, where we showed that MEPs¹⁴ and somatosensory evoked potentials¹⁵ can be instrumental for monitoring of spinal cord surgery under different anaesthetic regimens.^{14,16}

These published studies provided the motivation to further investigate the role of TMS in cervical spondylosis. In this study, we investigate the use of MEPs as an independent

predictor of surgical outcome in severe CSM and its role in the selection of patients for operative intervention.

Methods

With our institutional review board approval, we prospectively evaluated 46 consecutive patients (mean age, 57.6 years; range, 36 to 84 years; 28 men) presenting with clinical features of CSM over a 2-year period. Disease duration ranged from 6 to 24 months.

MRI

The patients were separated into 4 groups according to the degree of cord compression by degenerative osteo-cartilaginous (intervertebral disc herniation or combinations of herniated disc material accompanied by bony osteophytic lipping) elements at the most significant level on MRI. Specific details have been previously described.¹¹

TMS

All patients had informed consent before TMS was performed. Patients with past history of seizures, heart disease and intracranial operations were excluded. Magnetic stimulation was performed with a Dantec Mag 2 Stimulator (Dantec, Skovlunde, Denmark) by means of a Dantec S100 circular 10-cm diameter coil generating up to 1.9 Tesla in output. MEP recordings were made with adhesive surface electrodes in the first dorsal interosseous (FDI) for upper limb (UL) and abductor hallucis (AH) for lower limb (LL) muscles. The coil centre was positioned over the vertex to obtain consistent MEPs of maximum amplitude with the relevant muscle in slight (20%) contraction. For AH recordings, the coil centre was displaced 2-cm frontally from the vertex.¹⁷

Patients had multiple cortical stimulations, sometimes more than 10 for each muscle, to obtain distinctly recordable MEPs of consistent morphology. The average latency of the shortest of 10 most consistent responses was accepted. The minimum latency of 20 'F' responses was obtained. CMCT was calculated with the formula: MEP latency – PMCT (peripheral motor conduction time). PMCT was calculated as (F latency + M latency – 1)/2 in ms,¹⁸ where M represents the compound muscle action potential obtained from ulnar or tibial nerve electrical stimulation at the wrist and ankle respectively. MEP responses were considered absent if 10 consecutive stimulations up to 100% stimulator output consistently failed to elicit a reproducible MEP. For most trials, stimulator output of 80% was adequate to elicit consistent MEPs of similar waveform. MEPs included should be distinctly recordable and reproducible. Mean baseline to negative peak amplitudes based on an average of 10 highest amplitude MEPs trials were accepted from each limb.¹⁹

We performed CMCT and measurements on 45 healthy

age-matched volunteers with informed consent using the above technique. The ages ranged from 26 to 84 years and included 26 males and 19 females. Controls were screened strictly for cervical disease and other neurological problems by the authors.

Data Analysis

Patients' initial clinical score (S1) and postoperative scoring at 6 months (S2) were based on a modified Japan Orthopedic Association Scoring Scale (Table 1). A Modified Recovery Rate (MRR) was calculated based on the formula: $(S2 - S1) / (17 - S1) \times 100$. We regarded a good surgical outcome as MRR of 50 or above. This was depicted as MRR50.^{20,21} The clinical scoring was documented by an independent investigator blinded to the MRI and TMS findings. Postoperative scoring was documented by another investigator who did not perform the surgical procedure. Both the radiologist and electrophysiologist were blinded to patients' clinical status during MRI or TMS testing. All the findings were collated at the end of the study period for analysis.

Statistical analysis was separately performed by a biostatistician using SPSS for Windows Version 10.1. The level of statistical significance was set at $P < 0.05$. As some of the data normally distributed, for example, S1 and S2 values, which departed from normality (Shapiro-Wilk test, $P = 0.005$ for S1 and $P = 0.003$ for S2), it was decided that non-parametric methods be employed for statistical computation. However, despite this, further analysis of skewness for all 8 parameters bilaterally i.e. UL CMCT and MEP amplitudes, LL CMCT and MEP amplitudes, showed that skewness were < 1 . Thus, mean and standard deviations were quoted in our calculations. The Wilcoxon test was used specifically to compare paired data of S1 and S2 before and after surgery only.

Results

Controls

All controls and patients tolerated TMS well. This routine procedure in our laboratory took an average of 14 minutes to complete.

Mean and standard deviations (SDs) for UL and LL CMCTs in control subjects were 5.5 (1.11) ms and 12.26 (1.88) ms respectively. The upper limit of normal at 2SDs were 7.72 and 16.02 ms. All control subject's upper and lower limb MEPs were easily obtained and reproducible with stimulator outputs of 70% to 80%.

For UL studies, mean amplitude (SD) was 6.54 (1.46) mV. For LL studies, mean amplitude (SD) was 1.84 (0.71) mV respectively. Hence, the lower limits of normality at 2SDs were 3.62 mV and 0.42 mV for UL and LL respectively, provided the M amplitudes were above 6 mV

Table 1. Modified Cervical Spondylotic Myelopathy Score

UL Motor
4. No motor deficit
3. Mild difficulty using spoon or buttoning shirt
2. Great difficulty using spoon or buttoning shirt
1. Unable to do both but can move UL
0. No UL voluntary movement
LL Motor
5. No motor deficit
4. Walks unaided with mild difficulty
3. Walks unaided with great difficulty
2. Walks with aid
1. Cannot walk but moves legs
0. No LL voluntary movement
UL Sensory
3. No sensory loss
2. Mild sensory disturbance
1. Severe sensory disturbance with pain
0. Complete sensory loss
LL Sensory
3. No sensory loss
2. Mild sensory disturbance
1. Severe sensory disturbance with pain
0. Complete sensory loss
Sphincter Function
2. No dysfunction
1. Mild difficulty with micturition
0. Unable to micturate voluntarily

LL: lower limb; UL: upper limb
(Total, 17; Range, 0 to 17)

and 2 mV for upper (FDI) and lower limbs (AH) respectively. None of the patients studied had M amplitudes below these values.

Patients

All patients had severe cord compression and were classified into Group 3 (29 patients) and Group 4 (17 patients). The number of patients (in brackets) had 1 to 4 levels of cord compression on MRI: 1 (13), 2 (19), 3 (8) and 4 (6).

Surgery consisted of anterior or posterior decompression with cervical laminoplasty, performed by an experienced team of orthopedic surgeons. No significant intraoperative or postoperative complications were documented. There was significant difference (Wilcoxon Signed Rank test, $P < 0.0005$) between S1 (mean, 10.5; SD, 1.83; range, 7 to 14) and S2 (mean, 13.9; SD, 1.17; range, 12 to 16). The mean MRR was 51.5 (SD, 17.5; range, 16.7 to 85.7). None of the patients had scores of $S2 < S1$ after operation.

The patient's age (Pearson's correlation coefficient (r) = -0.012, $P = 0.935$), disease duration (mean, 11.4 months; range, 6 to 24 months; $r = 0.195$; $P = 0.194$), MRI group (Mann-Whitney test, $P = 0.697$) and MRI levels of

cord compression (Spearman’s correlation coefficient $r_s = 0.024, P = 0.873$) were not significantly correlated with MRR.

For CMCT and MEP amplitude analysis, data of the worse side were utilised for UL or LL. In patients with absent MEPs, CMCT was regarded as 23 ms for statistical calculations. This was derived from observation that the maximum CMCT obtained was 22.95 ms in our patient data. Absent MEP amplitude was entered as 0 mV. CMCT and MEP amplitude were regarded as abnormal if the respective values exceeded that of control subjects.

Table 2. Summary of Clinical Symptoms and Signs of 46 Patients

Symptoms	No. of patients (%)
Neck pain	16 (35)
UL numbness	38 (83)
LL numbness	30 (65)
Hand clumsiness	33 (72)
Leg stiffness	28 (61)
Sphincter disturbances	3 (7)
Signs	
UL hyperreflexia	39 (85)
LL hyperreflexia	44 (96)
Spastic gait	23 (50)
Reduced pain sensation	24 (52)
Reduced touch sensation	26 (57)
UL weakness	25 (54)
LL weakness	12 (26)
Positive Babinski’s sign	26 (57)

LL: lower limb; UL: upper limb

The UL CMCT ($r = -0.507, P < 0.0005$) and LL CMCT ($r = -0.452, P = 0.002$) were significantly and negatively correlated with S1. Similarly, UL MEP amplitude ($r = 0.494, P < 0.0005$) and LL MEP amplitude ($r = 0.305, P = 0.039$) were significantly correlated with S1.

The right UL CMCT was found to be significantly negatively correlated with right UL MEP amplitude (Pearson’s correlation coefficient $r = -0.651, P < 0.005$), as was the left UL CMCT with left UL MEP amplitude ($r = -0.593, P < 0.0005$).

There was significant association of MRR only with UL MEP amplitude abnormality (Mann-Whitney test, $P = 0.018$) and UL CMCT abnormality (Mann-Whitney test, $P = 0.012$). Using multiple stepwise linear regression analysis with MRR as dependent variable, and UL MEP abnormality and UL CMCT abnormality as independent variables, only UL CMCT abnormality was found to be the independently associated with MRR ($P = 0.011$).

Further analysis with the chi-square test showed that MRR50 was significantly higher for patients with UL CMCT abnormality (patients with MRR at 50 or above vs below: 69.4% vs 20%) and UL MEP amplitude abnormality (patients with MRR at 50 or above vs. below: 66.7% vs. 14.3%). Using multiple stepwise logistic regression with MRR50 as the dependent variable and the above 2 parameters as independent variables, UL CMCT abnormality was found to be the independent predictor for MRR50 [odds ratio (OR), 9.09; confidence limits for OR, 1.65 to 49.96; $P = 0.011$]. Figures 1 and 2 depict these findings graphically.

Table 2 provides a summary of patients’ clinical symptoms and signs. Table 1 shows the detailed clinical scoring scale used in this study. Tables 3, 4 and 5 show numerical data of TMS parameters before surgery, MRR with UL CMCT

Table 3. Summary of TMS Parameters of 46 Patients

TMS parameter	Mean	Median	Minimum	Maximum	25 th percentile	75 th percentile
RUL CMCT	11.35	11.68	4.95	23.00	6.48	15.03
LUL CMCT	11.51	9.98	5.15	23.00	7.64	15.38
RLL CMCT	19.24	20.95	9.20	23.00	14.95	23.00
LLL CMCT	18.39	19.05	8.70	23.00	14.66	23.00
RUL MEP amplitude	2.69	2.35	A	9.40	1.16	3.93
LUL MEP amplitude	2.51	2.10	A	10.10	1.07	3.30
RLL MEP amplitude	0.75	0.60	A	2.65	A	1.26
LLL MEP amplitude	0.57	0.47	A	2.20	A	0.94

A: absent responses; CMCT: central motor conduction time; L: left; LL: lower limb; MEP: motor evoked potential; R: right; TMS: transcranial magnetic stimulation; UL: upper limb
 All CMCT values in ms
 All MEP amplitudes in mV

Table 4. Summary of UL CMCT Abnormality in 46 Patients

	UL CMCT abnormality	
	Normal	Abnormal
No. of patients	10	36
MRR		
Mean	39.3	54.8
Median	33.3	58.6
Minimum	20.0	16.7
Maximum	66.7	85.7
25 th percentile	33.3	44.4
75 th percentile	46.7	66.7

MRR: Modified Recovery Rate; UL CMCT: upper limb central motor conduction time

Table 5. Summary of UL MEP Abnormality in 46 Patients

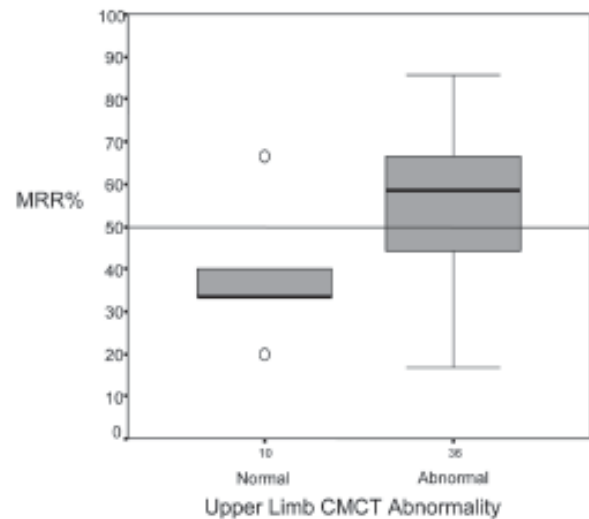
	UL MEP amplitude abnormality	
	Normal	Abnormal
No. of patients	7	39
MRR		
Mean	38.4	53.8
Median	33.3	57.1
Minimum	33.3	16.7
Maximum	62.5	85.7
25 th percentile	33.3	40.0
75 th percentile	40.0	66.7

MRR: Modified Recovery Rate; UL MEP: upper limb central motor evoked potential

abnormality and MRR with UL MEP amplitude abnormality respectively.

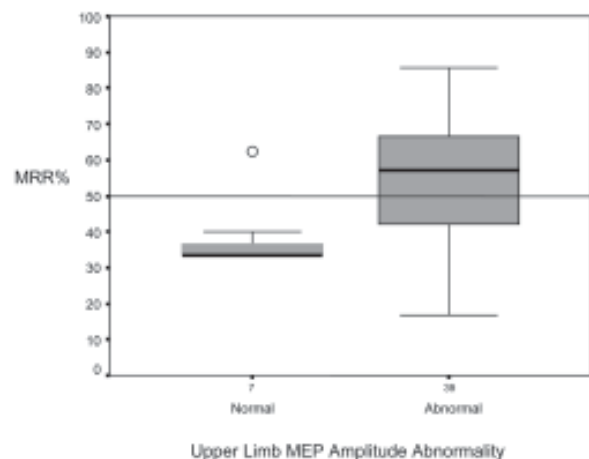
Discussion

CSM is a commonly encountered condition worldwide, but its management still harbours various controversial aspects. Patients with severe cord compression justify surgery,² but selection of patients is an important consideration. Previous studies have suggested that age and disease duration may be contributory factors to surgical outcome, but this was not evident in our findings. There were also no differences in surgical outcome in terms of MRI grading of severity or levels of cord compression. The levels of high T2 signals in the spinal cord did not correlate directly with the most significant levels of cord compromise in our previous study.¹¹ This suggests that other factors, including oedema, gliosis, ischaemia or disturbed blood flow may play a role in addition to mechanical factors.^{22,23} In addition, the presence of T2 signal change in the cord may not necessarily be directly related to the degree of cord



MRR: Modified Recovery Rate; UL CMCT: upper limb central motor conduction time

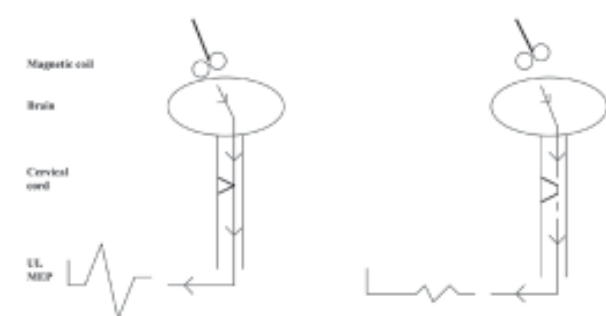
Fig. 1. Graphical illustration depicting number of patients with UL CMCT abnormality and MRR. The horizontal line indicates MRR50. Thick horizontal lines in each bar indicate median values, and the top and bottom boundaries are the 75th and 25th percentiles respectively. Error bars show range of values.



MRR: Modified Recovery Rate; UL MEP: upper limb motor evoked potential

Fig. 2. Graphical illustration depicting number of patients with UL MEP amplitude abnormality and MRR. The horizontal line indicates MRR50. Thick horizontal lines in each bar indicate median values, and the top and bottom boundaries are the 75th and 25th percentiles respectively. Error bars show range of values.

compression. A mild disc herniation may occasionally cause intramedullary cord T2 signal change if this was complicated mechanically by direct trauma or cord contusion against the disc.²⁴ Significant mechanical tension has also been shown to occur within the cervical cord during neck flexion, which may be clinically relevant for patients with CSM.²⁵ It is thus possible that our patients already had severe CSM clinically and on MRI, rendering these factors less important in influencing surgical outcome. However, significant improvement of clinical scoring at 6 months after surgery supports the use operative management in patients with severe CSM.



MEP: motor evoked potential; TMS: transcranial magnetic stimulation

Fig. 3. Schematic representation of MEP recording with TMS. In the left diagram, mild myelopathy with minimal cord compromise results in an MEP with normal latency, amplitude and morphology. In the right diagram, severe cord compression results in an MEP with delayed latency, reduced amplitude and dispersed morphology.

The use of TMS in the evaluation of CSM is well described.¹² We preferred the use of MEPs over somatosensory evoked potentials as the latter was known to be less sensitive for CSM evaluation.²⁶ Significant correlation of S1 with MEP amplitudes of both UL and LL, as well as negative correlation of CMCT of both UL and LL with S1, all suggest that severity of corticospinal dysfunction was directly related to clinical features. This finding further supports our choice of TMS for corticospinal functional evaluation pre-surgically.

Several underlying reasons may explain our findings. Firstly, CMCT abnormality provides direct evidence of corticospinal tract dysfunction.²⁷ This parameter has also been shown to be of value in functional electrophysiological evaluation of CSM.¹¹ CMCT reflects function in the fast conducting pyramidal fibres and prolonged CMCT may be secondary to desynchronisation, temporal dispersion, conduction block or even axonal degeneration in the fastest conducting fibres.²⁸ Intraoperative studies have documented prolonged CMCT with only a minor degree of conduction slowing in the corticospinal tract in compressive CSM, likely contributed by impaired summation of multiple descending potentials after TMS.²⁹

Secondly, the pathogenic factors of CSM are often multiple and interactive. They include congenital spinal narrowing, spondylotic bars, discs, hypertrophic facets, disturbed blood flow and demyelination.³⁰ Pathological studies suggest that the corticospinal tracts are affected early.³¹ Corticospinal fibres to the UL muscles are placed medially in the somatotopic arrangement of the cervical cord.³² In early CSM, lateral corticospinal tracts are first to be affected. It is thus possible that UL CMCT abnormality reflect more severe affection of the corticospinal tracts placed relatively more medially in the cervical cord. Surgical intervention may have then effectively relieved the clinically significant compression, leading to a better outcome. This

was further corroborated by our finding of negative correlation of S1 with UL CMCT, suggesting that patients who were clinically more severe were also electrophysiologically more abnormal, and subsequently benefited more from surgical decompression relative to patients with normal UL CMCT. Indeed, computer-assisted myelography has shown that clinical features in anterior cord compression were more marked, and removal of compression was followed by cord re-expansion and clinical improvement, in comparison with more lateral type compressions.³³

Thirdly, blood flow supply changes to the cervical cord are dynamic vascular factors that cannot be excluded. The role of ischaemia in the pathogenesis of CSM is well recognised,^{34,35} and rat models of cord ischaemia have demonstrated secondary demyelination and axon loss.³⁶ Abnormal UL CMCT may be contributed by these vascular factors. Surgical decompression may have facilitated blood flow to the anterior cord, leading to improved clinical outcomes observed.

Fourthly, we have shown that UL CMCT and MEP amplitude were highly correlated. This is consistent with the contribution of both demyelination and axon loss to either parameter.³⁷ The lower predictive value for a good outcome of UL MEP amplitude as compared to UL CMCT suggests that the former may reflect more axon loss (less favourable) than demyelination (more favourable), which may play a larger role in affecting changes in the latter parameter.

Finally, LL CMCT and MEP amplitude obtained with TMS may be more variable intrinsically³⁸ and technically,³⁹ rendering it difficult to show significant predictive value of surgical outcomes in comparison with UL MEP parameters. Use of more technically challenging methods, such as the triple stimulation technique,⁴⁰ may overcome some of these obstacles and would be of interest in future studies.

Two previous studies have addressed the role of MEPs in surgical outcome of CSM. One study described 39 patients who underwent CSM surgery and found that UL MEP parameters were most sensitive in detecting CSM, but no predictive values of MEPs were demonstrated.⁴¹ However, the patients included all had intramedullary high signal intensity on MRI, corresponding with MRI Group 4 in our classification. This group formed the minority compared with MRI Group 3 in our study. Moreover, the presence of T2 signals did not correlate with the MRR. Thus, we feel that our study reflected a realistic clinical situation, where patients were consecutively entered for surgery, regardless of intramedullary MRI changes. In addition, this study found that only median somatosensory potential N9-20 correlated with surgical outcome, but not MEPs. It is well known that MEPs are more sensitive in detecting myelopathy than SSEPs, and it was also shown in this same study that

arm MEPs were the most sensitive. This study also found that none of their patients had abnormal SSEPs with normal MEPs. Thus, it is possible that the lack of correlation of surgical outcome may be due to inclusion of patients with only intramedullary high T2 signals, which represent a chronic irreversible state of myelopathy. Chronic axon loss may also be contributory, as shown by our finding of the superior value of upper limb CMCT over MEP amplitude in surgical outcome correlation. Another study of 30 patients who underwent CSM surgery measured thoracolumbar spinal cord motor conduction velocity with TMS before and after intervention. Only patients with mild neurological dysfunction had improvement in conduction velocity at or after 6 months.⁴² We have chosen to utilise preoperative parameters with aims to explore their value as adjuncts in selection of surgical candidates, but further studies are in progress to address postoperative MEP findings.

This the largest series, to our knowledge, showing for the first time that UL CMCT abnormality obtained with TMS is an independent predictor of good surgical outcome in severe CSM. While TMS may not be the sole criterion, we advocate the use of this simple, rapid and safe technique as an adjunct in the preoperative selection of patients with severe cord compression resulting from cervical spondylosis. While our novel findings point to the value of CMCT as an adjunct in presurgical patient selection, larger trials would be needed to validate the techniques.

In conclusion, the value of electrophysiological techniques in cervical spondylosis has been shown not only for diagnosis and screening, but also for outcome prediction in surgical management. Future studies, such as those pertaining to outcomes in specific subgroups of intrinsic/ extrinsic cord compression from various aetiologies, will be of interest to both clinicians and researchers.

Acknowledgement

The author would like to acknowledge the following for their help: S Fook-Chong, Department of Clinical Research, Singapore General Hospital; WM Yue, CT Tan, JLT Chen and SB Tan, Department of Orthopaedic Surgery, Singapore General Hospital; LL Chan, Department of Diagnostic Radiology, Singapore General Hospital; S Raman, Department of Anaesthesiology, Singapore General Hospital.

This study was supported in part by the Spinal Cord Program Grant funded by the National Medical Research Council.

REFERENCES

1. Sampath P, Bendebba M, Davis JD, Ducker TB. Outcome of patients treated cervical myelopathy. A prospective, multicenter study with independent clinical review. *Spine* 2000;25:670-6.
2. Kaminsky SB, Clark CR, Traynelis VC. Operative treatment of cervical spondylotic myelopathy and radiculopathy. A comparison of laminectomy and laminoplasty at five year average follow-up. *Iowa Orthop* 2004;24:95-105.
3. Epstein NE. Laminectomy for cervical myelopathy. *Spinal Cord* 2003;41:317-27.
4. Morishita Y, Hida S, Naito M, Matsushima U. Evaluation of cervical spondylotic myelopathy using somatosensory evoked potentials. *Int Orthop* 2005;18:1-4.
5. Bednarik J, Kandanka Z, Vohanka S, Stejskal L, Vlach O, Schroder R. The value of somatosensory and motor evoked potentials in predicting and monitoring the effect of therapy in spondylotic cervical myelopathy. Prospective randomized study. *Spine* 1999;24:1593-8.
6. Chen CJ, Lyu RK, Lee ST, Wong YC, Wang LJ. Intramedullary high intensity on T2-weighted MR images in cervical spondylotic myelopathy: prediction of prognosis with type of intensity. *Radiology* 2001;221:789-94.
7. Fujiwara K, Yonenobu K, Ebara S, Yamashita K, Ono K. The prognosis of surgery for cervical compression myelopathy. An analysis of the factors involved. *J Bone Joint Surg Br* 1989;71:293-8.
8. Ishihara H, Matsui H, Kitagawa H, Yonezawa T, Tsuji H. Prediction of the surgical outcome for the treatment of cervical myelopathy by using hyperbaric oxygen therapy. *Spinal Cord* 1997;35:763-7.
9. Barker AT, Jalinous R, Freeston H. Non-invasive magnetic stimulation of the human motor cortex. *Lancet* 1985;1:1106-7.
10. Hess CW, Mills KR, Murray NMF. Measurement of central motor conduction in multiple sclerosis by magnetic brain stimulation. *Lancet* 1986;2:355-8.
11. Lo YL, Chan LL, Lim W, Tan SB, Tan CT, Chen JLT, et al. Systematic correlation of transcranial magnetic stimulation and magnetic resonance imaging in cervical spondylotic myelopathy. *Spine* 2004;10:1137-45.
12. Lo YL, Chan LL, Tan CT, Chen JLT, Tan SB. Pectoralis motor evoked potentials in cervical spondylosis. *J Neurol Sci* 2005;235:55-9.
13. Lo YL, Chan LL, Lim W, Tan SB, Tan CT, Chen JLT, et al. Transcranial magnetic stimulation screening for cord compression in cervical spondylosis. *J Neurol Sci* 2006;244:17-21.
14. Lo YL, Dan YF, Tan YE, Fook-Chong S, Tan SB, Tan CT, et al. Intraoperative monitoring study of ipsilateral motor evoked potentials in scoliosis surgery. *Eur Spine J* (in press).
15. Lo YL, Dan YF, Tan YE, Tan SB, Tan CT, Raman S. A prospective study of the utility of preoperative somatosensory evoked potentials in spinal surgery. *Eur Spine J* 2005;14:521-2.
16. Lo YL, Dan YF, Tan YE, Nurjannah S, Tan SB, Tan CT, et al. Intraoperative motor evoked potential monitoring in scoliosis surgery: comparison of desflurane/ nitrous oxide with propofol total intravenous anesthetic regimens. *J Neurosurg Anesth* 2006 (in press).
17. Hess CW, Mills KR, Murray NMF. Magnetic brain stimulation: central motor conduction studies in multiple sclerosis. *Ann Neurol* 1987;22:744-60.
18. Rossini PM, Pauri F. Central motor conduction time studies. In: Paulus W, Hallett M, Rossini PM, Rothwell JC, editors. *Transcranial Magnetic Stimulation*. Amsterdam: Elsevier, 1999:199-211.
19. Kiers L, Cros D, Chiappa KHL. Variability of motor potentials evoked by transcranial magnetic stimulation. *Electroencephalogr Clin Neurophysiol* 1993;89:415-25.
20. Kohno K, Kumon Y, Oka Y, Matsui S, Ohue S, Sasaki S. Evaluation of prognostic factors following expansive laminoplasty for cervical stenotic myelopathy. *Surg Neurol* 1997;48:237-45.
21. Nagano A, Miyamoto K, Hosoe H, Inuma N, Nishimoto H, Sakaeda H, et al. Surgical treatment for cervical myelopathy in patients aged > 80 years. *Orthopedics* 2004;27:45-8.
22. Mair WGP, Druckman R. The pathology of spinal cord lesions and their relation to clinical features in protrusions of intervertebral discs (a report of four cases). *Brain* 1953;76:70-91.
23. Taylor AR. Vascular factors in myelopathy associated with cervical spondylosis. *Neurology* 1964;14:62-8.
24. Leite CC, Escobar BE, Bazan C 3rd, Jinkins JR. MRI of cervical facet dislocations. *Neuroradiology* 1997;39:583-8.
25. Koschorek F, Jensen HP, Terwey B. Dynamic studies of cervical spinal

- canal and spinal cord by magnetic resonance imaging. *Acta Radiol Suppl* 1986;369:727-9.
26. Veilleux M, Daube J. The value of ulnar somatosensory evoked potentials (SEP) in cervical myelopathy. *Electroencephalogr Clin Neurophysiol* 1987;68:415-23.
 27. Lo YL, Ratnagopal P. Transcranial magnetic stimulation studies in the Miller Fisher syndrome: evidence of corticospinal tract abnormality. *J Neurol Neurosurg Psychiatry* 2001;71:210-4.
 28. Mills KR, Murray NMF. Corticospinal tract conduction time in multiple sclerosis. *Ann Neurol* 1985;18:601-5.
 29. Kaneko K, Taguchi T, Morita H, Yonemura H, Fujimoto H, Kawai S. Mechanism of prolonged central motor conduction time in compressive cervical myelopathy. *Clin Neurophysiol* 2001;112:1035-40.
 30. Hayashi H, Okada K, Hashimoto J, Tada K, Ueno R. Cervical spondylotic myelopathy in the aged patient. A radiographic evaluation of the aging changes in the cervical spine and etiologic factors of myelopathy. *Spine* 1988;13:618-25.
 31. Ogino H, Tada K, Okada K. Canal diameter, antero-posterior compression ratio and spondylotic myelopathy of the cervical spine. *Spine* 1983;8: 1-15.
 32. Brunzholzl C, Claus D. Central motor conduction time to upper and lower limbs in cervical cord lesions. *Arch Neurol* 1994;51:245-9.
 33. Yu YL, de Boulay GH, Stevens JM, Kendall BE. Computer-assisted myelography in cervical spondylotic myelopathy and radiculopathy. Clinical correlations and pathogenetic mechanisms. *Brain* 1986;109: 259-78.
 34. Fehlings MG, Skaf G. A review of the pathophysiology of cervical spondylotic myelopathy with insights for potential novel mechanisms drawn from traumatic spinal cord injury. *Spine* 1998;23:2730-7.
 35. Gooding MR, Wilson CB, Hoff JT. Experimental cervical myelopathy: effects of ischemia and compression in the canine cervical cord. *J Neurosurg* 1975;43:9-17.
 36. Blisard KS, Follis F, Wong R, Miller KB, Wernly JA, Seremin OU. Degeneration of axons in the corticospinal tract secondary to spinal cord ischemia in rats. *Paraplegia* 1995;33:136-40.
 37. Thickbroom GW, Byrnes ML, Archer SA, Kermode AG, Mastaglia FL. Corticomotor organization and motor function in multiple sclerosis. *J Neurol* 2005;252:765-71.
 38. Brouwer B, Qiao J. Characteristics and variability of lower limb motorneuron responses to transcranial magnetic stimulation. *Electroencephalogr Clin Neurophysiol* 1995;97:49-54.
 39. Lo YL, S Fook-Chong. A transcranial magnetic stimulation of the ipsilateral silent period in lower limb muscles. *Neurosci Lett* 2004;360:337-40.
 40. Magistris MR, Rosler KM, Truffert A, Landis T, Hess CW. A clinical study of motor evoked potentials using a triple stimulation technique. *Brain* 1999;122:265-79.
 41. Lyu RK, Tang LM, Chen CJ, Chen CM, Chang HS, Wu YR. The use of evoked potentials for surgical correlation and surgical outcome in cervical spondylotic myelopathy with intramedullary high signal intensity on MRI. *J Neurol Neurosurg Psychiatry* 2004;75:256-61.
 42. Chang CW, Lin SM. Measurement of motor conduction in the thoracolumbar cord. A possible predictor of surgical outcome in cervical spondylotic myelopathy. *Spine* 1996;21:485-91.