

Role of Ultrasound Biomicroscopy (UBM) in the Detection and Localisation of Anterior Segment Foreign Bodies*

Sujata Guha,¹MD, FRCS (Edin), Muna Bhende,¹MD, Mani Baskaran,¹MD, Tarun Sharma,¹MD, FRCS (Edin)

Abstract

Introduction: The aim of this study was to investigate the role of ultrasound biomicroscopy (UBM) in imaging anterior segment foreign bodies and compare it with conventional B-scan ultrasound and computed tomography (CT). **Materials and Methods:** The charts of 18 eyes with anterior segment foreign bodies were reviewed. The rates of detection of foreign bodies using ultrasound, CT scan and UBM were compared. **Results:** The foreign body detection rates were 36.5% by ultrasound, 88.9% by CT scan, and 94.4% by UBM. The diagnosis of presence of a foreign body using UBM was made based on high reflective echoes causing shadowing or reverberations. In 7 eyes, UBM detected injury to the zonules, guiding the operative procedure. In the 8 eyes for which all tests were performed, rates of detection of foreign bodies were 25% (2/8) with ultrasound, 87.5% (7/8) with CT, and 100% (8/8) with UBM. **Conclusion:** UBM is a valuable adjunct for the accurate localisation of small foreign bodies, including cilia. It offers a higher detection rate than that provided by ultrasound and CT scan.

Ann Acad Med Singapore 2006;35:536-40

Key words: B-scan ultrasonography, Computed tomography, Ocular trauma, Retained foreign bodies

Introduction

The presence of an intraocular foreign body (IOFB) is a common complication of ocular trauma. For surgical planning, the localisation of IOFBs has to be accurate. Posterior segment foreign bodies are detected by clinical examination and imaging techniques such as computed tomography (CT) and low-frequency (5 MHz to 10 MHz) ultrasonography.¹⁻³ However, accurate localisation of anterior segment IOFBs is difficult when conventional imaging techniques are employed.⁴

Ultrasound biomicroscopy (UBM), a high-frequency (50 MHz), high-resolution imaging technique, offers cross-sectional images of the anterior segment to a depth of 5 mm.⁵⁻⁷ We report our experience using UBM in the evaluation of 18 eyes with anterior segment IOFBs.

Materials and Methods

Between August 1995 and March 2002, 30 consecutive eyes with suspected anterior segment IOFBs were imaged with UBM, B-scan or CT scan, or a combination of all three. Using these imaging tests, no IOFBs were detected in 12 of these 30 eyes. Therefore, 18 eyes were included for

further analysis. All eyes underwent complete eye examination, including CT and B-scan ultrasonography, when indicated. UBM was performed in all patients using the Humphrey Ultrasound Biomicroscope model 840 (Humphrey Instruments, San Leandro, CA). Using a fixation target for the unaffected eye, scanning was performed with the patient supine. Under topical anaesthesia, a polymethyl methacrylate (PMMA) eyecup was positioned between the lids and filled with sterile methylcellulose, a coupling agent. The scanner probe was carefully placed 2 mm to 3 mm away from the ocular surface. The machine was set at a gain of 80 dB, a time-gain control of 5 dB per mm and delay of 2.24 mm; at each clock hour, multiple cross-sectional scans perpendicular to the limbus were performed.

Eighteen eyes of 18 patients with anterior segment IOFBs were included in the study. The mean age of patients was 28.9 years (range, 14 to 53 years). Seventeen (94.4%) patients were male and the right eye was involved in 12 cases. The results are summarised in Table 1.

Injury had been sustained in industrial settings in 10 patients, in road accidents in 5 patients and in domestic settings (household environment) in 3. The time interval

¹ Sankara Nethralaya, Vision Research Foundation, Chennai, Tamil Nadu, India

Address for Reprints: Dr Sujata Guha, Sankara Nethralaya, 18, College Road, Chennai – 600 006, Tamil Nadu, India.

Email: drsg@snmail.org

* Presented as a scientific poster at the Annual Meeting of the American Academy of Ophthalmology 2002, Orlando, Florida, USA

Table 1. Clinical Characteristics of Patients with Anterior Segment IOFB

Case no.	Age/Sex/Eye	Nature of injury	Trauma/primary repair to UBM interval	Visual acuity		Anterior segment status	FB location with UBM	Foreign body detection			Type of FB	
				Preop	Postop			On ocular examination	CT	US		FB removal by surgery
1	22/M/OD	RTA	60 days	LP	20/20	Hypaema	Iris	No	-	No	Yes	Glass
2	40/M/OS	I	75 days	5/200	20/20	Localised corneal scar, PS, iris atrophy	Pars plana	No	Yes	No	Yes	Metallic
3	53/M/OD	D	11 months	20/20	20/30	Normal, Pars plana exudate	Pars plana	No	-	-	Yes	Cilia
4	22/M/OD	D	6 days	20/30	20/20	Caterpillar hair in cornea	Cornea	Yes	-	-	No	Cilia
5	36/F/OS	RTA	13 days	HM	20/20	Corneal sutures, FB seen in AC	AC	Yes	No	No	Yes	Glass
6	24/M/OD	I	5 months	20/60	20/20	Localised corneal/lens opacity, iris hole	Pars plana	No	Yes	Yes	Yes	Metallic
7	21/M/OS	I	3 years	20/80	20/20	Localised corneal opacity, iris hole	Intraocular	No	Yes	No	Yes	Metallic
8	45/M/OD	RTA	6 years	HM	LP	Corneal opacity	Intraocular	No	Yes	Yes	No	Glass
9	31/M/OS	I	4 years	20/120	20/80	Corneal opacity	Pars plana	No	Yes	No	No	Metallic
10	34/M/OD	RTA	4 months	20/120	20/20	Corneal oedema, Glass FB in AC	AC	Yes	-	Yes	Yes	Glass
11	22/M/OD	I	7 months	20/30	20/30	Corneal haze	Pars plana	No	Yes	No	Yes	Metallic
12	27/M/OD	RTA	3 years	CF	20/20	Corneal opacity, Glass FB in AC	AC	Yes	-	Yes	Yes	Glass
13	25/M/OD	I	45 days	CF	20/20	Localised corneal/intraocular opacity	Intraocular	No	-	Yes	Yes	Metallic
14	30/M/OD	D	15 days	20/20	20/20	Cilia embedded in cornea	Cornea and angle	Yes	-	-	No	Cilia
15	26/M/OS	I	10 days	20/20	-	Localised corneal scar, iris nodule	Iris	No	-	-	Yes	Metallic
16	25/M/OS	I	5 days	20/20	-	Localised corneal wound, FB embedded in iris	Iris	Yes	-	No	Yes	Metallic
17	23/M/OD	I	3 months	20/40	20/120	Corneal scar, lenticular opacity	Ciliary body	No	Yes	No	Yes	Metallic
18	14/M/OD	I	2 years	20/20	20/20	Localised iris prolapse under intact conjunctiva	Not localised	No	Yes	-	Yes	Glass

AC: anterior chamber; CF: counting fingers closed to face; CT: computed tomography; CB: ciliary body; D: domestic; FB: foreign body; HM: hand motion; I: industrial; IOFB: intraocular foreign body; LP: light perception; PAS: peripheral anterior synechiae; PP: pars plana; PS: posterior synechiae; RTA: road traffic accident; UBM: ultrasound biomicroscopy; US: ultrasound B-scan

from injury/primary wound repair to UBM ranged from 5 days to 6 years. The time interval was less than 15 days in 5 eyes, between 15 days and 60 days in 2 eyes, between 2 and 6 months in 3 eyes, and more than 6 months in 8 eyes. Anterior segment findings are enumerated in Table 1; these findings included hyphema, corneal oedema/opacity, caterpillar hair in the cornea, foreign body in the anterior chamber, iris hole/nodule, posterior synechiae, and lenticular opacity. As per the classification proposed by the International Society of Ocular Trauma,⁸ all cases belonged to the category of penetrating injury and intraocular foreign body; none of the patients had perforating injury. Based on clinical settings, gonioscopy was performed in 5 eyes, of which caterpillar hair could be visualised in one.

Results

Case One

A 21-year-old man (case 7) had sustained a penetrating injury with a metallic IOFB about 3 years prior. He had been treated conservatively, without any surgical intervention. He had subsequently suffered recurrent attacks of redness and progressive decrease in vision. Conventional B-scan ultrasound did not show any evidence of IOFB. However, CT scan provided evidence of IOFB in the inferonasal quadrant of the vitreous cavity. UBM localised the IOFB adjacent to the lens equator at the 7 o'clock position (Fig. 1); it also picked up overlying dehiscence of the lens capsule and localised zonular damage. The patient underwent phacoemulsification with intraocular lens implantation, along with IOFB removal and anterior vitrectomy. Two months postoperatively, his visual acuity was 20/20.

Case Two

A 36-year-old lady (case 5) had presented at our institution after meeting with road traffic accident, and the surgeon who had carried out primary repair (corneo-scleral wound) had referred the case to us for further management. No foreign body was detected with conventional ultrasound and CT. She underwent pars plana lensectomy, vitrectomy and an encircling band procedure. In the postoperative period, the presence of a shiny glass piece in the inferior angle was suspected. Although the piece of glass was visible through the cornea, UBM was performed (Fig. 2). UBM showed high reflective echoes with shadowing. The foreign body was removed making a stab incision at the inferior corneo-scleral junction. At one-year follow-up, her best-corrected visual acuity was 20/30.

Case Three

A 24-year-old man (case 6) had sustained an injury with a metallic IOFB 5 months earlier and showed evidence of clinical siderosis. The presence of a tiny IOFB was detected

on CT and B-scan ultrasound (anteriorly placed), in addition to a possible IOFB detected by UBM. Initial vitrectomy did not reveal a foreign body; a repeat CT detected it and a repeat UBM (Fig. 3) precisely localised it over the pars plana area. A revision of vitrectomy, cataract removal with intraocular lens (IOL), and the removal of IOFB were performed. Two months later, his visual acuity was 20/20.

Location and Nature of IOFB and Concomitant Damage to Adjacent Structures

The foreign body was in the pars plana area in 6 eyes, in the anterior chamber in 3, in the lens in 3, in the iris in 3, in the cornea in 2, and at the vitreous base in 1. The nature of the foreign body was metallic in 9 eyes, glass in 6 (Figs. 4 & 5), and caterpillar hair in 3. Concomitant damage to surrounding structures was observed in 7 eyes: zonular damage occurred in 3, pars plana membrane without tractional detachment in 1, pars plana membrane with traction ciliary body detachment in 1, peripheral anterior synechiae with iris stromal damage in 1, and scleral dehiscence at the limbus in 1 (Table 2).

Detection and Localisation of Foreign Body on Clinical Evaluation, Ultrasonography, Computed Tomography, and UBM

Clinical examination revealed the presence of IOFBs in 6 eyes. These IOFBs were detected in the cornea in 2 eyes, in the anterior chamber in 3 eyes, and in the iris stroma in 1 eye (Fig. 6). Of the 13 eyes that underwent conventional ultrasonography, IOFBs were observed in 5 eyes: 2 in the anterior chamber, 2 in the lens and 1 in the pars plana. CT was performed in 9 cases and IOFBs were seen in 8 eyes: 6 of them in the pars plana region, 1 in the lens, and 1 at the vitreous base. Unlike CT and ultrasound, UBM proved useful in detecting corneal and iris foreign bodies. The precise location of IOFB in 17 out of 18 cases was imaged by UBM.

Surgical Details

Of the 18 eyes with anterior segment IOFBs, surgical procedures were performed in 14. In 2, it was not necessary to remove intracorneal caterpillar hair (Fig. 7) because there was no inflammation, and in the other 2, the patients

Table 2. Damage to Surrounding Structures

Damage	No. of cases
Zonular damage	3
Pars plana membrane, no traction	1
Pars plana membrane, traction on ciliary body	1
Peripheral anterior synechiae with iris stromal damage	1
Scleral dehiscence at the limbus	1

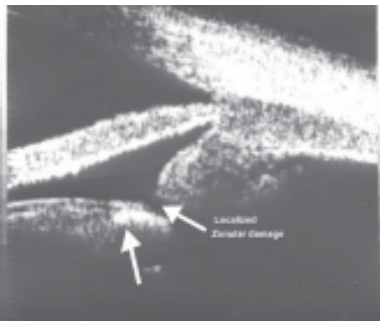


Fig. 1. UBM photograph showing intralenticular foreign body plus localised zonular damage.

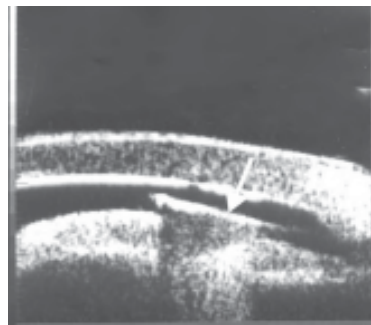


Fig. 2. UBM photograph showing a glass foreign body in the anterior chamber (arrow) with shadowing behind it.

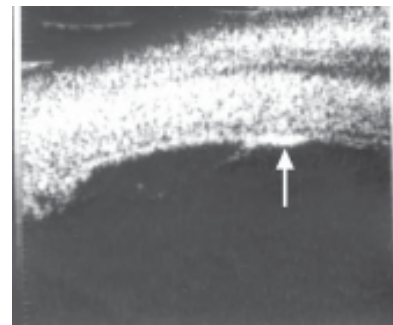


Fig. 3. UBM photograph showing a foreign body (arrow) in the pars plana.

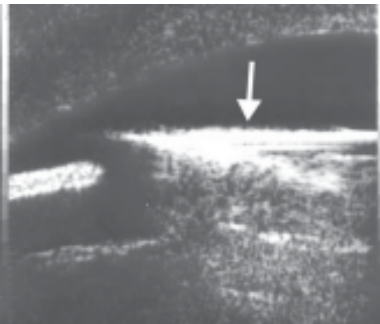


Fig. 4. UBM photograph showing a glass foreign body (arrow) in the pupillary area with reverberation echoes behind it.

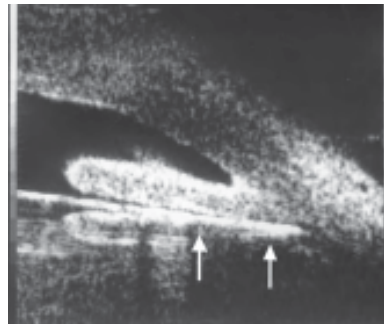


Fig. 5. UBM photograph showing a glass foreign body (arrow), located in the retroiridal space, just anterior to anterior lens surface; reverberation echoes are also seen.

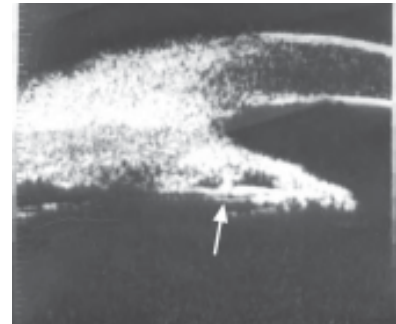


Fig. 6. UBM photograph showing a foreign body (arrow) embedded in the posterior iris stroma.

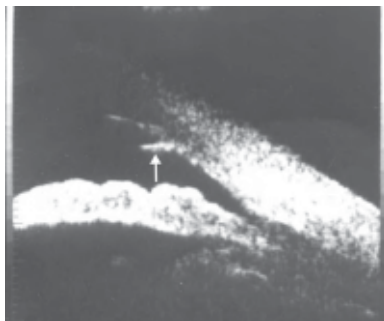

Fig. 7. UBM photograph showing a caterpillar hair (arrow), which is jutting out of the posterior corneal stroma into the anterior chamber.

did not want surgery. Of the patients who underwent surgical procedures, preoperative Snellen visual acuity was between 20/20 and 20/30 in 5 eyes, between 20/40 and 20/120 in 4, 5/200 in 1, and less than 5/200 in 4. At the last follow-up, post-surgery visual acuity was 20/20 in 9 eyes, 20/30 in 2 eyes, and 20/120 in 1 eye. Two patients did not return for further evaluation (cases 15 and 16).

Discussion

When IOFBs are retained, their precise localisation is important in surgical decision making. However, the extent to which anterior IOFBs can be clinically identified and accurately localised is limited;⁴ scleral depression may also

be somewhat difficult in recently injured eyes. In eyes with opaque media, most clinicians rely on conventional ultrasonography, CT and now, UBM.⁹⁻¹¹

Conventional ultrasonography is a valuable imaging modality in evaluating injured eyes in that it not only detects and localises IOFBs of the posterior segment, but is also useful in demonstrating associated posterior ocular damage such as retinal detachment and retinal incarceration.³ However, B-scan ultrasound cannot be used to assess anterior segment structures as its resolution is not sufficiently high.⁴ CT can detect IOFBs more than 1.5 mm in size but its use is constrained by eye movements and the poor quality of reconstructed computer images.¹²

This paper highlights our findings that anteriorly placed IOFBs could be detected in 6/18 eyes on clinical evaluation, 5/13 eyes on conventional ultrasonography, 8/9 eyes on CT scan, and 17/18 on UBM. Of the 8 eyes in which all imaging tests were performed, IOFB detection rate was 25% (2/8) with conventional ultrasound, 87.5% (7/8) with CT scan, and 100% (8/8) with UBM. In cases 13, 15 and 16, CT scan was avoided as the IOFB had already been localised by B-scan ultrasound and UBM (intralenticular IOFB in case 13, and iris stromal IOFB in case 15 and 16).

Ultrasonography and CT did not detect foreign bodies located in the cornea and iris stroma. UBM, however,

provided the precise locations of IOFBs and additional information on damaged structures of anterior segment. In case 12, scleral-fixated lens was planned because of extensive damage to zonular apparatus, and in case 7, phacoemulsification with IOL in the capsular bag could be performed because damage to zonules was localised. In 5 cases (cases 4, 5, 10, 12 and 14), though the foreign body was seen on clinical examination, UBM was considered in order to detect concomitant damage to surrounding structures. In 1 eye, zonular and capsular damage was noted (case 12), and in another (case 5), peripheral anterior synechiae plus damage to iris stroma was evident. In case 10 and 12, foreign bodies were present in the anterior chamber and therefore conventional B-scan technique would not have been appropriate.

In the eyes with caterpillar hair, UBM helped (case 3) in indicating that hair had migrated across the ciliary body into the vitreous cavity, causing recurrent inflammation. Their removal through the pars plana route rendered the eye quiet.¹³ After follow-up of more than 2 years, the patient maintained a visual acuity of 20/30.

In eyes with ocular siderosis, when routine imaging modalities did not reveal any foreign body, UBM was helpful in detecting and localising it. In case 17, if UBM had been performed in the initial evaluation, the second surgical intervention could have been avoided. On the other hand, if 360-degree radial scans are not performed in a meticulous fashion, one might fail to image anteriorly located IOFB, as in case 6.

Most IOFBs produce a high reflective echo similar to that produced by iris tumour or peripheral anterior synechiae. However, high reflective echoes produced by IOFBs result in a complete shadowing of all structures behind them. Also, glass foreign bodies produce characteristic reverberations posterior to them. Furthermore, shadowing observed with high-frequency UBM is more prominent than that observed using low-frequency B-scan ultrasound. Nonetheless, the detection of anterior segment foreign bodies and associated ocular damage is best achieved with UBM and in this, an experienced operator is crucial. In summary, high-frequency (50 MHz) and high-resolution UBM is a useful adjunct for the accurate localisation of small anterior segment IOFBs.

Acknowledgement

Supported by the Vision Research Foundation, 18, College Road, Chennai – 600 006, Tamil Nadu, India.

Competing Interest: None identified

REFERENCES

1. Coleman DJ, Rondeau MJ. Diagnostic imaging of ocular and orbital trauma. In: Shingleton BJ, Herssh PS, Kenyon KR, editors. *Eye Trauma*. St Louis: Mosby-Year Book, 1991:25-40.
2. Coleman DJ. Reliability of ocular and orbital diagnosis with B-scan ultrasound. 2. Orbital diagnosis. *Am J Ophthalmol* 1972;74:704-18.
3. Das T, Namperumalsamy P. Ultrasound in ocular trauma. *Indian J Ophthalmol* 1987;35:121-5.
4. Nouby-Mahmoud G, Silverman RH, Coleman DJ. Using high-frequency ultrasound to characterize intraocular foreign bodies. *Ophthalmic Surg* 1993;24:94-9.
5. Pavlin CJ, Harasiewicz K, Sherar MD, Foster FS. Clinical use of ultrasound biomicroscopy. *Ophthalmology* 1991;98:287-95.
6. Deramo VA, Shah GK, Bauman CR, Fineman MS, Correa ZM, Benson WE, et al. Ultrasound biomicroscopy as a tool for detecting and localizing occult foreign bodies after ocular trauma. *Ophthalmology* 1999;106:301-5.
7. Looi ALG, Gazzard G, Tan DTH. Surgical exploration minimised by ultrasound biomicroscopy localization of intraocular foreign body. *Eye* 2001;2:234-5.
8. Kuhn F, Morris R, Witherspoon C D, Heimann K, Jeffers JB, Treister G. A standardized classification of ocular trauma. *Ophthalmology* 1996;103:240-3.
9. Laroche D, Ishikawa H, Greenfield D, Liebmann JM, Ritch R. Ultrasound biomicroscopic localization and evaluation of intraocular foreign bodies. *Acta Ophthalmologica Scand* 1998;76:491-5.
10. Barash D, Goldenberg-Cohen N, Tzadok D, Lifshitz T, Yassur Y, Weinberger D. Ultrasound biomicroscopic detection of anterior ocular segment foreign body after trauma. *Am J Ophthalmol* 1998;126:197-202.
11. Berinstein DM, Gentile RC, Sidoti PA, Stegman Z, Tello C, Liebmann JM, et al. Ultrasound biomicroscopy in anterior ocular trauma. *Ophthalmic Surg Lasers* 1997;28:201-7.
12. Topilow HW, Ackerman AL, Zimmerman RD. Limitations of computerised tomography in the localisation of intraocular foreign bodies. *Ophthalmology* 1984;91:1086-91.
13. Bhende M, Biswas J, Sharma T, Chopra SK, Gopal L, Shroff CM. Ultrasound biomicroscopy in the diagnosis and management of pars planitis caused by caterpillar hairs. *Am J Ophthalmol* 2000;130:125-6.