

Clinical Report: A Case of Williams Syndrome and Klinefelter Syndrome

Le Ye Lee,¹ Swee Chye Quek,^{1,2} Samuel S Chong,^{1,2}
Arnold SC Tan,² Josephine MS Lum,¹ Denise Li-Meng Goh,^{1,2}

Abstract

Introduction: Williams syndrome (WS) is a rare but well recognised neurodevelopmental disease affecting the connective tissue and the central nervous system. Many patients are identified through the presence of dysmorphic features and associated cardiac abnormalities. Klinefelter syndrome (KS) is associated with gynaecomastia, small testes, azoospermia and elevated gonadotropin levels. They are recognised in the second decade of life by their tall stature and delay in pubertal development. A combination of constitutive WS and KS has yet to be described. **Clinical Picture:** We report a child with these genetic aberrations, highlighting the clinical characteristics of such an individual. **Conclusion:** The manifestations and interactions of both conditions are also discussed.

Ann Acad Med Singapore 2006;35:901-4

Key words: Developmental disability, Gynaecomastia, Pulmonary valve stenosis

Introduction

Williams syndrome (WS) is a rare but well recognised neurodevelopmental disease affecting the connective tissue and the central nervous system. The syndrome was first described in 1961 and the phenotype was subsequently expanded in 1972.^{1,2} The condition has an estimated incidence of 1 in 20,000 live births and most are due to spontaneous mutations, although rare familial (autosomal dominant) cases have been reported. The underlying molecular mechanism is a submicroscopic chromosomal deletion involving the elastin gene (ELN) at 7q11.23.³

Klinefelter syndrome (KS), which was first described by Klinefelter et al in 1942, refers to men with gynaecomastia, small testes, azoospermia and elevated gonadotropin levels.⁴ The chromosomal abnormality was identified in 1956 when staining for the dense sex chromatin became available.⁵ KS remains a common disorder and affects as many as 1 in 500 male patients. The diagnosis is frequently not made until the second decade of life because of the subtle and marked variability in clinical expression.

To date, there is only 1 documented case of mosaic Klinefelter syndrome in a child with Williams syndrome.⁶ We now describe the first patient with constitutive Williams

and Klinefelter syndromes and discuss the manifestations and interactions between these 2 conditions.

Case Report

The patient was a 4-year-old Chinese boy with congenital heart defects, global developmental delay, short stature and dysmorphism. He is the first child of non-consanguineous Chinese parents who had no medical or family history of note. The antenatal period was uneventful and he was born at 38 weeks of gestation with a birth weight of 2.5 kg (third to tenth percentile). The diagnosis of a large ventricular septal defect was made after a cardiac murmur was detected at day 3 of life. He subsequently developed cardiac failure and required treatment with oral diuretics. He was referred at 4 months of age to our hospital for further management. Trans-thoracic 2D echocardiography confirmed the presence of a large (7 mm) perimembranous ventricular septal defect but also detected severe bilateral pulmonary artery branch stenosis. Surgical closure was deferred in view of his small size and severe pulmonary artery stenosis. Anti-failure medication was continued and he was followed at regular intervals. Cardiac catheterisation performed at 23 months of age demonstrated the presence of bilateral pulmonary branch artery stenosis, a small ventricular septal

¹The Children's Medical Institute, National University Hospital, Singapore

²The Department of Paediatrics, National University of Singapore

Address for Reprints: Dr Le Ye Lee, Department of Paediatrics, The Children Medical Institute, National University Hospital, 5 Lower Kent Ridge Road, Singapore 119074.

defect and insignificant left to right shunt (Qp/Qs ratio was 1.3:1). Anti-failure medication was stopped and surgical correction was offered.

Global developmental delay was first detected at 7 months of age. This was further confirmed by a Bayley Scale of Infant Development performed at 2 years 9 months, which showed that he had a development age of only 16 months. Early intervention education was commenced with good results. He gained milestones but was still significantly behind his peers. At the age of 4 years, our patient remained developmentally delayed, especially in the intellectual and speech faculties, and was functioning at a developmental age of 2.

He had short stature and dysmorphism that became more obvious over time. At 4 years of age, his height and weight were both less than the third percentile. He has frontal prominence, bitemporal narrowness, periorbital fullness, short nose, full cheeks, long philtrum, full lips, wide mouth and a small jaw; features suggestive of WS. There was no stellate iris noted. Serum calcium and the urine calcium/

creatinine ratio were normal and there was no nephrocalcinosis seen on renal ultrasound.

Methods

Informed consent was obtained from the patient’s mother. The karyotype analysis was performed using standard trypsin-Wright (GTW) banding methods. Fluorescence *in situ* hybridisation (FISH) analysis was performed using a probe hybridising to the Williams syndrome chromosome region on 7q11.23 and a control probe hybridising to the 7q22 region (Qbiogene, Calsbad, CA; cat# PDEL5155).

Results

GTW-banded chromosome analysis revealed the presence of an extra copy of the X chromosome in all the cells analysed, with no microscopic evidence of a deletion or translocation detected on chromosome 7 (Fig. 1). In addition, FISH analysis demonstrated a submicroscopic deletion of the Williams syndrome chromosome region on 1 chromosome 7 in all 20 metaphase spreads. (Fig. 2). His karyotype was thus 47,XXY.ish del17q11.23q11.23 (WBSR-). His parents’ karyotypes were normal.

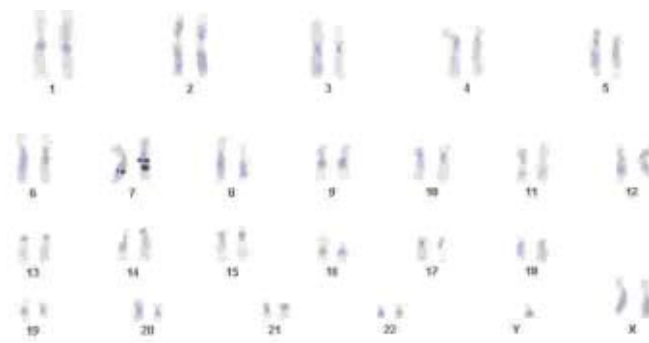


Fig. 1. GTW-banded chromosomes.

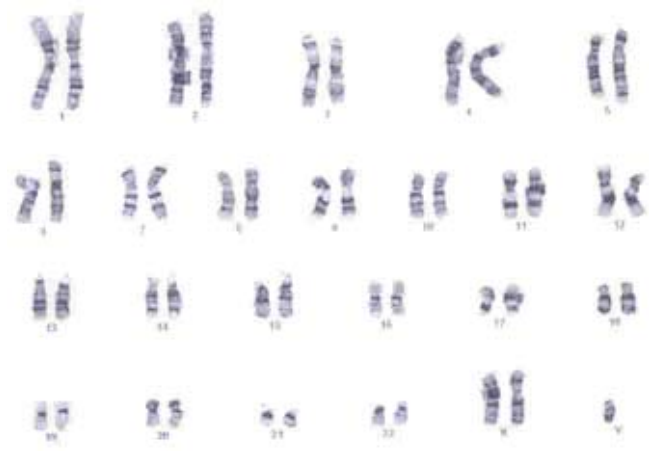


Fig. 2. Metaphase FISH showing 47,XXY and hemizygosity at the Williams Critical Region. Green signal: control probe. Red signal: WBSR probe. Chromosome 7 on the left has the deletion. Chromosome 7 on the right does not have the deletion.

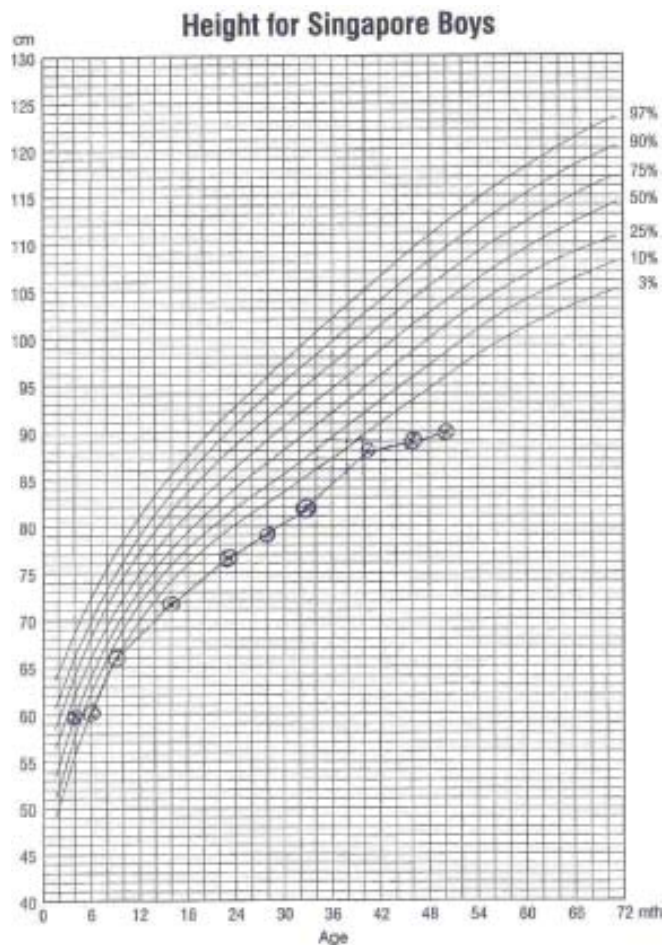


Fig. 3. Growth chart of patient (height).

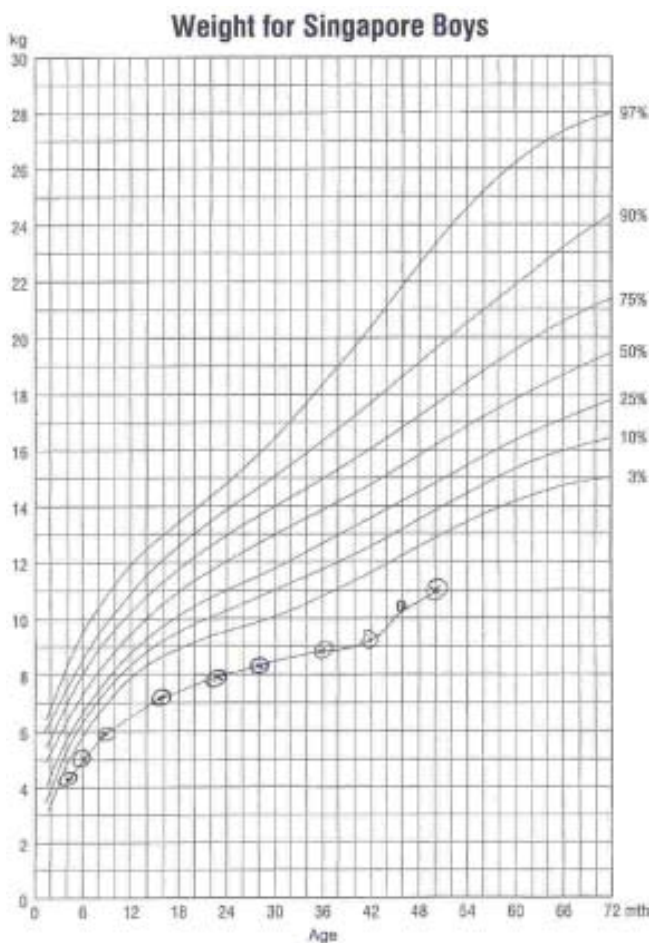


Fig. 4. Growth chart of patient (weight).

Discussion

A patient with both WS and KS was described and found to have more manifestations of the former than the latter. His facial features were characteristic of WS. However, stellate iris, a diagnostic feature, was not seen in his dark brown iris. The growth pattern of the patient resembled that of WS rather than KS. The height and weight were at the third percentile on the WS growth charts (Figs. 3 and 4), despite adequate dietary intake and good control of his cardiac failure.⁷ There was no excessive vomiting, a symptom frequently seen in WS. It remains to be seen if the effect of KS on his height velocity or body proportions will manifest at a later age. The combined effect of both the syndromes remains unclear and we need to follow-up on his growth especially when he enters puberty. However, with KS, his puberty may be delayed giving extra years for increased height growth. Though his current height is short but with the above, he may eventually be tall.

Cardiac lesions are commonly seen in WS but not in KS. Elastin-related arteriopathy occurs in about 75% of WS patients and can affect any artery.⁸ Although supravalvular

aortic stenosis (SVAS) is the most common lesion, pulmonary artery branch stenosis and ventricular septal defects, as seen in this patient, are known associations. The natural history of pulmonary artery branch stenosis is difficult to predict though some patients improve during childhood and adolescent.⁹

The eventual intellectual and functional outcome in this patient remained guarded in view of the co-existence of WS and KS. This can have a serious implication as the combined effect of both syndromes might be additive. It is known that all WS individuals and some KS individuals have mental retardation.^{10,11} Both conditions are associated with initial speech delay, as illustrated in our patient who did not speak till 3 years of age. The effects of KS and WS on later speech development are, however, opposite. Individuals with KS have significant problems with expressive language, auditory processing and auditory memory, while children with WS tend to speak more fluently despite limited comprehension, subnormal speech content and inappropriate use of clichés and stereotyped phrases.¹²

The behavioural characteristics of WS and KS individuals are also quite opposite. The older WS child is overfriendly whereas the older KS child has a tendency towards being shy and immature.¹³⁻¹⁵ Our patient was never too overtly friendly but seemed to be developing this trait. Time will reveal which personality will predominate.

The mechanism giving rise to both KS and WS in this individual remained undetermined. Non-disjunction in parental gametogenesis is the main mechanism in the pathogenesis of KS, with paternal non-disjunction accounting for 53.2% of cases, maternal meiosis I errors for 34.4%, and maternal meiosis II errors for 9.3%.¹⁶ Only a very small percentage is due to post-mitotic errors (3.2%). In contrast, spontaneous de novo deletion of the 7q11.23 region is the main cause of WS.³ The parents of our patient were young and had normal karyotypes. This suggested that the constitutive presentation of both chromosomal anomalies in this boy was both spontaneous mutations and pre-mitotic. Hence, his parents were counselled that the risk of recurrence in the next pregnancy was low. The importance of chromosomal culture was pertinent in this case as the clinical dysmorphism is characteristic of WS but the chromosomal culture identified KS as well. Had the chromosomal culture not been done, we will not identify the KS until the child is much older. Having 2 spontaneous de novo mutations makes us wonder if he is genetically predisposed to mutations, however, no other cases of these were noted either in WS or KS.

In conclusion, the first case of an individual with both constitutive WS and KS was described. The individual had more manifestations of WS than KS but this was not

surprising as the features of KS tend to become more obvious only in the second decade of life. He will continue to have regular cardiac follow-up, early intervention education and will be monitored for additional complications noted to occur in both conditions i.e, hypercalcaemia, increased risk of breast cancer, extragonadal germ cell tumours, autoimmune disorders, endocrine disorders, venous thrombosis and infertility.

REFERENCES

1. Beuren AJ. Supravalvular aortic stenosis: a complex syndrome with and without mental retardation. *Birth Defects Orig Art Ser VIII* 1972;45-56.
2. Williams JC, Barratt-Boyes BG, Lowe JB. Supravalvular aortic stenosis. *Circulation* 1961;1311-8.
3. Ewart AK, Morris CA, Atkinson D, Jin W, Sternes K, Spallone P, et al. Hemizyosity at the elastin locus in a developmental disorder, Williams syndrome. *Nat Genet* 1993;5:11-6.
4. Klinefelter HF Jr, Reifenstein EC Jr, Albright F. Syndrome characterized by gynecomastia, aspermatogenesis without aleydigism and increased secretion of follicle-stimulating hormone. *J Clin Endocrinol Metab* 1942;2:615.
5. Bradbury JT, Bunge RG, Boccabella RA. Chromatin test in Klinefelter's syndrome. *J Clin Endocrinol Metab* 1956;16:689.
6. Bzduch V, Lukacova M, Berankova M, Bircak J. The Williams-Beuren syndrome in a boy with mosaic Klinefelter's syndrome [Slovak]. *Cesk Pediatr* 1989;44:622-3.
7. Lashkari A, Smith AK, Graham JM Jr. Williams-Beuren syndrome: an update and review for the primary physician. *Clin Pediatr (Phila)* 1999;38:189-208.
8. Morris Ca, Dempsey SA, Leonard CO, Dilts C, Blackburn BL. Natural history of Williams syndrome; physical characteristics. *J Pediatr* 1988;113:318-26.
9. Wessel A, Pankau R, Kececioglu D, Ruschewski W, Bursch JH. Three decades of follow-up of aortic and pulmonary vascular lesions in the Williams-Beuren syndrome. *Am J Med Genet* 1994;52:297-301.
10. Graham JM Jr, Bashir AS, Stark RE, Silbert A, Walzer S. Oral and written language abilities of XXY boys: implications for anticipatory guidance. *Pediatrics* 1988;81:795-806.
11. Jones KL, Smith DW. The Williams elfin facies syndrome. A new perspective. *J Pediatr* 1975;86:718-23.
12. Udwin O, Yule W. Expressive language of children with Williams syndrome. *Am J Med Genet Suppl* 1990;6:108-14.
13. Mandoki MW, Sumner GS, Hoffman RP, Riconda DL. A review of Klinefelter's syndrome in children and adolescents. *J Am Acad Child Adolesc Psychiatry* 1991;30:162-72. Erratum in *J Am Acad Child Adolesc Psychiatry* 1991;30:516.
14. Ratcliffe SG, Bancroft J, Axworthy D, McLaren W. Klinefelter's syndrome in adolescence. *Arch Dis Child* 1982;57:6-12.
15. Sarimski K. Behavioural phenotypes and family stress in three mental retardation syndromes. *Eur Child Adolesc Psychiatry* 1997;6:26-31.
16. Jacobs PA, Hassold TJ, Whittington E, Butler G, Collyer S, Keston M, et al. Klinefelter's syndrome: an analysis of the origin of the additional sex chromosome using molecular probes. *Ann Hum Genet* 1988; 52(Pt 2):93-109.