

Retrospective Review of Eyes with Neovascular Age-related Macular Degeneration Treated with Photodynamic Therapy with Verteporfin and Intravitreal Triamcinolone

Tamara K Fackler,¹MD, Shantan Reddy,²MD, MPH, Srilaxmi Bearely,¹MD, Sandra Stinnett,¹DrPH, Sharon Fekrat,¹MD, FACS, Michael J Cooney,³MD, MBA

Abstract

Aim: To review the outcomes of eyes with neovascular age-related macular degeneration (AMD) treated with photodynamic therapy (PDT) with verteporfin and intravitreal triamcinolone acetate injection. **Materials and Methods:** We retrospectively reviewed the outcomes of consecutive eyes with neovascular AMD that received an intravitreal triamcinolone injection within 1 week of their first PDT and had at least 6 months of follow-up. Eyes were retreated with PDT at 3-month intervals if angiographic leakage was present. **Results:** Twenty-six eyes from 24 patients were identified. The mean visual acuity at baseline was 20/118 (median 20/112). The mean visual acuity decreased to 20/138 at 9 months ($P = 0.24$, $n = 15$) and to 20/174 at 12 months ($P = 0.23$, $n = 8$). The change in visual acuity from baseline was not statistically significant at any time point. The mean central foveal thickness by OCT measured 342 μm at baseline and decreased to 296 μm at 12 months ($P = 0.31$). Sixty-two per cent of eyes required no additional PDT at 12 months. Nineteen per cent of 26 eyes had a rise in intraocular pressure that was controlled with topical medication alone. **Conclusion:** Photodynamic therapy with verteporfin combined with intravitreal triamcinolone injection in the treatment of neovascular AMD may be superior to PDT alone by decreasing visual loss and reducing the number or retreatments.

Ann Acad Med Singapore 2006;35:701-5

Key words: Choroidal neovascularisation, Macular degeneration, Photodynamic therapy, Triamcinolone, Verteporfin

Introduction

Among the variety of paradigms implicated in the pathogenesis of choroidal neovascularisation (CNV), an inflammatory component has been a recent focus of interest.¹⁻¹² The findings that complement factor H (CFH) polymorphisms are associated with an increased risk in the development of age-related macular degeneration (AMD) and that the histopathology of choroidal neovascularisation demonstrates inflammatory cells have further supported this theory.¹⁻⁵ Though photodynamic therapy (PDT) with verteporfin does cause an acute regression of the neovascularisation by selective photochemical destruction of vascular endothelial cells, there is a persistent or even therapy-induced inflammatory reaction which may explain the high rate of reactivation and growth of the neovascularisation after treatment.^{6,7}

Given the limitations of PDT therapy and the known anti-

inflammatory and anti-angiogenic properties of corticosteroids, a combination therapy consisting of both modalities may provide a synergistic effect.⁸⁻¹² Several studies have shown a benefit to using intravitreal triamcinolone as an adjunct to photodynamic therapy with verteporfin. Spaide and colleagues¹³ reported an improvement in the mean visual acuity at 12 months compared with baseline in 13 eyes that were treated initially with PDT and intravitreal triamcinolone. Their retreatment frequencies were 1.24. Rechtman and colleagues,¹⁴ in their series of 14 eyes, found that only a small percentage experienced an improvement in visual acuity, while the majority maintained visual acuity from baseline at 1 year or longer. In a prospective, interventional case series of 184 eyes, Augustin and Schmidt-Erfurth¹⁵ reported that the visual acuity improved in the majority of patients treated with combination therapy, though the number of

¹ Duke Eye Center, Albert Eye Research Institute, North Carolina, USA

² Manhattan Eye, Ear, and Throat Hospital, New York, USA

³ Vitreous Retina Macula Consultants of New York, New York, USA

Address for Reprints: Dr Michael J Cooney, Vitreous Retina Macula Consultants of New York, 460 Park Avenue, New York, NY 10022, USA.

Email: m.cooney@vrmny.com

patients who were not previously treated with PDT were not commented on.

In this study, we retrospectively reviewed the visual outcomes, complications, and optical coherence tomography (OCT) data for all eyes that received PDT with intravitreal triamcinolone as the initial treatment for neovascular AMD at the Duke Center for macular diseases.

Patients and Methods

The billing records of all patients who carried a code for PDT and intravitreal triamcinolone were reviewed. The patients were evaluated at the Duke Center for Macular Diseases in Durham or one of the satellite clinics. Eyes with choroidal neovascularisation from any cause other than AMD were excluded. Only eyes that received PDT with intravitreal triamcinolone as the initial treatment for neovascular AMD were included. For all eyes, triamcinolone was injected within 1 week of the initial PDT treatment. Photodynamic therapy with verteporfin was administered in the standardised manner per the Treatment of Age-related Macular Degeneration with Photodynamic Therapy (TAP) protocol.¹⁶ Four milligrams of triamcinolone acetonide (0.1 cc of Kenalog®, 40 mg/mL, Bristol-Myers Squibb, Princeton, NJ) was injected 3.5 to 4.0 mm posterior to the limbus in a standard sterile fashion. Eyes were evaluated at baseline, 3 months, 6 months, 9 months, and 12 months after therapy. Eyes received additional PDT, if angiographic leakage was present, and/or intravitreal triamcinolone at 3-month intervals at the discretion of the treating retinal specialist. Baseline data recorded were age, gender, lesion type as noted on fluorescein angiography, and greatest linear diameter (GLD) of the CNV. Data collected at each visit included the visual acuity using the Early Treatment Diabetic Retinopathy Study (ETDRS) chart, intraocular pressure, lens clarity, and complications. Central foveal thickness and total macular volume using OCT measurements were analysed, when available. Both PDT and intravitreal triamcinolone retreatment rates were recorded. This review was approved by the Duke University Medical Center Institutional Review Board.

Statistical analysis was carried out, when appropriate, using the Wilcoxon signed rank test. The change in visual

acuity from baseline was calculated at the 3-, 6-, 9-, and 12-month time points. The changes in central foveal thickness and total macular volume from baseline were also assessed. The visual acuities were converted to logMar units for statistical analysis, but the corresponding Snellen equivalents are reported here for ease of discussion. The last observation was not carried forward for missing data. An alpha level for statistical significance was set a priori at 0.05.

Results

Twenty-six eyes from 24 patients met our criteria. The mean age was 76.9 years \pm 7.3 years (mean \pm SD). Seventeen patients were female and 9 were male. On fluorescein angiography, 10 eyes were characterised as classic, 8 minimally classic, and 8 as purely occult. The GLD of the CNV lesion at baseline ranged from 1.3 to 6.1 mm, with a mean of 3.6 mm. Six-month follow-up was available for 26 eyes, 9-month follow-up for 16 eyes, and 12-month follow-up for 8 eyes. The mean visual acuity at baseline was 20/118 (median 20/112). The mean visual acuity at 3 months was 20/105 ($P = 0.27$ for change from baseline), and at 6 months was 20/110 ($P = 0.57$). The mean visual acuity decreased to 20/138 at 9 months ($P = 0.24$, $n = 15$), and to 20/174 at 12 months ($P = 0.23$, $n = 8$). There was a trend towards decreasing visual acuity; however, this was not statistically significant for any time point (Table 1). The visual acuity distributions are shown in Figure 1. Sixteen of the 26 eyes (62%) required no additional PDT during the follow-up period of 6 months (Fig. 2). The PDT retreatment rate was 12% at 3 months (3 of 26 eyes) and 27% at 6 months (7 of 26 eyes). Retreatment data were available for 16 eyes at 9 months and 8 eyes at 12 months with retreatment rates of 25% and 13%, respectively. Intravitreal triamcinolone retreatment rates were 4% at 3 months, 8% at 6 months, 19% at 9 months, and 0% at 12 months (Fig. 2). Central foveal thickness by OCT (Fig. 3) measured an average of 342 μ m at baseline, and decreased to 239 μ m at 3 months ($P = 0.0008$), 266 μ m at 6 months ($P = 0.08$), 342 μ m at 9 months ($P = 0.84$), and 296 μ m at 12 months ($P = 0.31$). The total macular volume (TMV) on OCT was similarly analysed (Fig. 4). The TMV was 7.82 mm³ before initial treatment and decreased to 6.65 mm³ at 3 months ($P = 0.0002$). The TMV was 7.45 mm³ at 6 months ($P = 0.21$), 7.94 mm³ at 9 months ($P = 0.49$), and 7.57 mm³ at 12 months ($P = 1.00$).

The lens status was not graded by a formalised method in this study;¹⁷ however, progression of cataract occurred in 2 of the 16 phakic eyes that required cataract extraction. No eyes developed a sterile endophthalmitis or a retinal detachment at any time point. An increase in intraocular pressure beyond 22 mm Hg was noted in 5 eyes (19%), of which all were controlled with topical medication alone.

Table 1. Visual Acuities of Eyes Initially Treated with PDT and Intravitreal Triamcinolone

	Mean	Median	
Baseline	20/118	20/112	n = 26
3 months	20/105	20/100	n = 25, $P = 0.27$
6 months	20/110	20/126	n = 23, $P = 0.57$
9 months	20/138	20/126	n = 15, $P = 0.24$
12 months	20/174	10/178	n = 8, $P = 0.23$

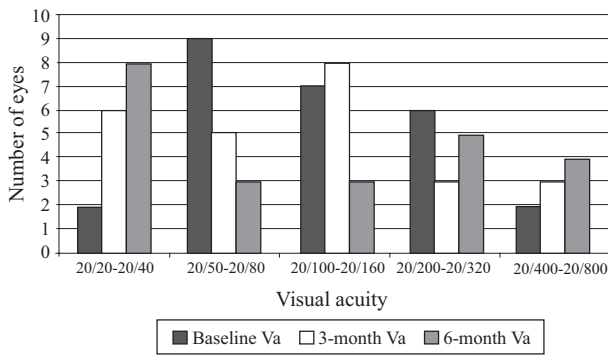


Fig. 1. Visual acuity distribution in eyes initially treated with photodynamic therapy (PDT) and intravitreal triamcinolone.

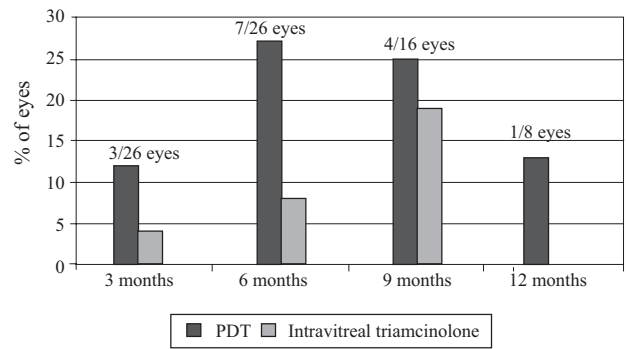


Fig. 2. Percentage of eyes needing retreatment with either photodynamic therapy (PDT) or intravitreal triamcinolone.

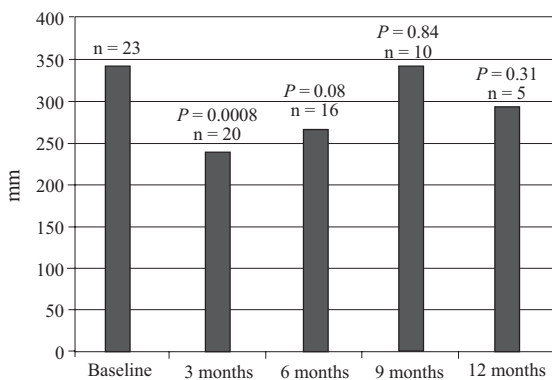


Fig. 3. Central foveal thickness measured by optical coherence tomography (OCT) in eyes initially treated with photodynamic therapy (PDT) and intravitreal triamcinolone.

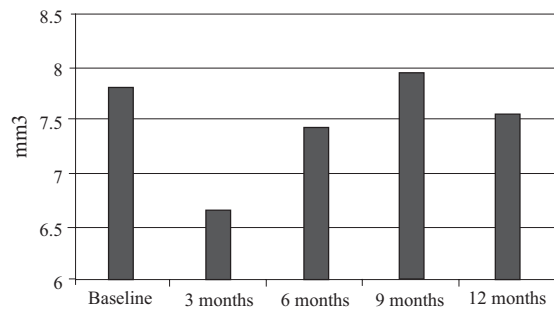


Fig. 4. Total macular volume measured by optical coherence tomography (OCT) in eyes initially treated with photodynamic therapy (PDT) and intravitreal triamcinolone.

Discussion

In this small retrospective case series, intravitreal triamcinolone with PDT for subfoveal CNV from AMD resulted in a short-term visual benefit that was maintained over 12 months. Mean visual acuity did not change in any significant way at the 3-, 6-, 9- and 12-month follow-up. All eyes required fewer than expected repeat treatments during the follow-up as compared with previous studies in which eyes were treated with PDT alone.^{16,18} However, retreatment criteria in the TAP¹⁶ and Verteporfin in Photodynamic Therapy (VIP)¹⁸ trials was based on angiographic criteria, whereas now retreatment criteria is generally based on angiography as well as OCT findings. In our study, OCT measurements showed a statistically significant decrease in foveal thickness and total macular volume at 3 months; however, the difference was not maintained at the 9- and 12-month follow-up visits. A transient rise in intraocular pressure was noted in 5 eyes and was controlled by topical medication. Progression of cataract requiring cataract extraction was noted in 2 of 16 phakic eyes. There were no cases of endophthalmitis or retinal detachment.

AMD is the leading cause of visual loss in people over the age of 50 years in North America, and choroidal neo-

vascularisation is the most common cause of visual loss in this disease.^{19,20} Photodynamic therapy, which is an FDA-approved treatment for predominantly classic CNV, causes a targeted destruction of endothelial membranes and occlusion of choroidal vasculature without significant damage to the overlying retinal structures.²¹⁻²³ However, PDT treatment can induce inflammation and relative ischaemia of the retinal pigment epithelial (RPE) and photoreceptor cells which can lead to an upregulation of vascular endothelial growth factor (VEGF).^{6,7} Furthermore, the inflammatory components of CNV are not targeted by PDT alone, thereby promoting the continued release of VEGF and thus a recurrence of CNV.²⁴

Histopathologic examination of excised choroidal neovascularisation has demonstrated significant numbers of leukocytes and macrophages within the complex.^{25,26} Furthermore, inflammatory cells have been implicated in the pathogenesis of CNV.^{27,28} Intravitreal triamcinolone is believed to impede the development of choroidal neovascularisation through the reduction of VEGF in the rodent,¹⁰ rabbit,¹¹ and primate⁹ models. Previous studies with neovascular AMD treated with triamcinolone have reported a reduction in visual loss in humans.²⁹⁻³¹

Combination therapy with PDT and concomitant intravitreal triamcinolone can decrease the amount of inflammatory cells as well as reduce the amount of VEGF released, limit the permeability of the vasculature, and modulate the expression of adhesion molecules.^{9-12,32}

Recent case series reporting results of combination PDT and intravitreal triamcinolone have been promising but slightly variable. As previously mentioned Spaide and colleagues¹³ reported a visual acuity improvement of 2.5 lines above baseline at 12 months, with a treatment rate of 1.24. Rechtman and colleagues,¹⁴ in their series of 14 eyes, similarly reviewed the outcomes after treatment with intravitreal triamcinolone in conjunction with the first PDT and had a follow-up of 1 year or longer. Overall, 7% gained ≥ 30 ETDRS letters, 50% maintained stable vision, 14% lost 15 to 29 letters, and 29% lost ≥ 30 letters. Augustin and Schmidt-Erfurth,¹⁵ in their series of 184 eyes, found that visual acuity improved by a mean of 1.22 lines using Snellen acuity and 1.43 using laser interferometry. Their mean number of required treatments was 1.21. In our study, the change in visual acuity was not statistically significant at each follow-up visit. Overall, 62% required only 1 PDT retreatment over the 12 months of the study.

Triamcinolone has been shown to be relatively safe when used intravitreally.³³ We report that 19% of our eyes treated with intravitreal triamcinolone experienced a rise in intraocular pressure. This was slightly lower than that reported by Spaide and colleagues¹³ (38.5%), Rechtman and colleagues¹⁴ (28.5%), and Augustin and Schmidt-Erfurth¹⁵ (25%). Our report, in conjunction with others, demonstrates that PDT in combination with intravitreal triamcinolone may be superior to PDT alone in preserving visual acuity in eyes with neovascular macular degeneration.

Our study is limited by the fact that it had a small sample size, was non-randomised and non-masked, although it is the largest published study using PDT and intravitreal triamcinolone in eyes not treated with PDT alone. Randomised controlled clinical trials assessing the efficacy and safety of combined PDT and intravitreal triamcinolone are currently underway. With the advent of new anti-VEGF agents, clinical studies investigating combination PDT with anti-VEGF therapies are on the horizon.

The authors have no financial interest in the subject matter presented in this report. Support: None

REFERENCES

- Klein RJ, Zeiss C, Chew EY, Tsai JY, Sackler RS, Haynes C, et al. Complement factor H polymorphism in age-related macular degeneration. *Science* 2005;308:385-9.
- Haines JL, Hauser MA, Schmidt S, Scott WK, Olson LM, Gallins P, et al. Complement factor H variant increases the risk of age-related macular degeneration. *Science* 2005;308:419-21.
- Dastgheib K, Green WR. Granulomatous reaction to Bruch's membrane in age-related macular degeneration. *Arch Ophthalmol* 1994;112:813-8.
- Killingsworth MC, Sarks JP, Sarks JH. Macrophages related to Bruch's membrane in age-related macular degeneration. *Eye* 1990;4:613-21.
- Oh H, Takagi H, Takagi C, Suzuma K, Otani A, Ishida K, et al. The potential angiogenic role of macrophages in the formation of choroidal neovascular membranes. *Invest Ophthalmol Vis Sci* 1990;40:1891-8.
- Schmidt-Erfurth U, Miller J, Sickenberg M, Bunse A, Laqua H, Gragoudas E, et al. Photodynamic therapy of subfoveal choroidal neovascularization: clinical and angiographic examples. *Graefes Arch Clin Exp Ophthalmol* 1998;236:365-74.
- Schmidt-Erfurth U, Michels A, Barbazetto I, Laqua H. The photodynamic effects of choroidal neovascularization and physiological choroids. *Invest Ophthalmol Vis Sci* 2002;43:830-41.
- Wilson CA, Berkowitz BA, Sato Y, Ando N, Handa JT, de Juan E Jr. Treatment with intravitreal steroids reduces blood-retinal barrier breakdown due to retinal photocoagulation. *Arch Ophthalmol* 1992;110:1155-9.
- Ishibashi T, Miki K, Sorgente N, Patterson R, Ryan SJ. Effects of intravitreal administration of steroids on experimental subretinal neovascularization in the subhuman primate. *Arch Ophthalmol* 1985;103:708-11.
- Ciulla TA, Criswell MH, Danis RP, Hill TE. Intravitreal triamcinolone acetate inhibits choroidal neovascularization in a laser-treated rat model. *Arch Ophthalmol* 2001;119:399-404.
- Antoszyk AN, Gottlieb JL, Machemer R, Hatchell DL. The effects of intravitreal triamcinolone acetate on experimental pre-retinal neovascularization. *Graefes Arch Clin Exp Ophthalmol* 1993;231:34-40.
- Penfold PL, Wen L, Madigan MC, King NJ, Provis JM. Modulation of permeability and adhesion molecule expression by human choroidal endothelial cells. *Invest Ophthalmol Vis Sci* 2002;43:3125-30.
- Spaide RF, Sorenson J, Maranan L. Photodynamic therapy with verteporfin combined with intravitreal injection of triamcinolone acetate for choroidal neovascularization. *Ophthalmology* 2005;112:301-4.
- Rechtman W, Danis RP, Pratt LM, Harris A. Intravitreal triamcinolone with photodynamic therapy for subfoveal choroidal neovascularization in age-related macular degeneration. *Br J Ophthalmol* 2005;88:344-7.
- Augustin AJ, Schmidt-Erfurth U. Verteporfin therapy combined with intravitreal triamcinolone in all types of choroidal neovascularization due to age-related macular degeneration. *Ophthalmology* 2006;113:14-22.
- Treatment of Age-Related Macular Degeneration with Photodynamic Therapy (TAP) Study Group. Photodynamic therapy of subfoveal choroidal neovascularization in age-related macular degeneration with verteporfin: one year results of 2 randomized clinical trials-TAP report 1. *Arch Ophthalmol* 1999;117:1329-45.
- Chylack LT Jr, Leske MC, Khu P, McCarthy D, Wu SY. Strategies for measuring the rate of age-related cataract formation in vivo. *Lens Eye Toxic Res* 1989;6:515-22.
- Verteporfin in Photodynamic Therapy Study Group. Verteporfin therapy of subfoveal choroidal neovascularization in age-related macular degeneration: two year-results of a randomized clinical trial including lesions with occult with no classic choroidal neovascularization-verteporfin in photodynamic therapy report 2. *Am J Ophthalmol* 2001;131:541-60.
- Klein R, Wang Q, Klein BE, Moss SE, Meuer SM. The relationship of

- age-related maculopathy, cataract, and glaucoma to visual acuity. *Invest Ophthalmol Vis Sci* 1995;36:182-91.
20. Ferris FL 3rd, Fine SL, Hyman L. Age-related macular degeneration and blindness due to neovascular maculopathy. *Arch Ophthalmol* 1984;102:1640-1.
 21. Miller JW, Walsh AW, Kramer M, Hasan T, Michaud N, Flotte TJ, et al. Photodynamic therapy of experimental choroidal neovascularization using lipoprotein delivered benzoporphyrin. *Arch Ophthalmol* 1995;12:810-8.
 22. Schmidt-Erfurth U, Hassan T, Gragoudas E, Michaud N, Flotte TJ, Birngruber R. Vascular targeting in photodynamic occlusion of subretinal vessels. *Ophthalmology* 1994;101:1953-61.
 23. Schmidt-Erfurth U, Hassan T, Schomacker K, Flotte T, Birngruber R. In vivo uptake of liposomal benzoporphyrin derivative and photothrombosis in experimental corneal neovascularization. *Laser Surg Med* 1995;17:178-88.
 24. Kvant A, Algvere PV, Berglin L, Seregard S. Subfoveal fibrovascular membranes in age-related macular degeneration express vascular endothelial growth factor. *Invest Ophthalmol Vis Sci* 1996;37:1929-34.
 25. Gehrs KM, Heriot WJ, de Juan E Jr. Transmission electron microscopic study of subretinal choroidal neovascular membrane due to age-related macular degeneration. *Arch Ophthalmol* 1992;110:833-7.
 26. Lopez PF, Grossiklaus HE, Lamber JM, Aaberg TM, Capone A Jr, Sternberg P Jr, et al. Pathological features of surgically excised subretinal neovascular membranes in age-related macular degeneration. *Am J Ophthalmol* 1991;112:647-56.
 27. Penfold PL, Provis JM, Billson FA. Age-related macular degeneration: ultrastructural studies of the relationship of leukocytes to angiogenesis. *Graefes Arch Clin Exp Ophthalmol* 1987;225:70-6.
 28. Penfold PL, Killingsworth M, Sarks SH. An ultrastructural study of the role of leukocytes and fibroblasts in the breakdown of Bruch's membrane. *Aust J Ophthalmol* 1984;12:23-31.
 29. Penfold PL, Gyory JF, Hunyor AB, Billson FA. Exudative macular generation and intravitreal triamcinolone. A pilot study. *Aust N Z J Ophthalmol* 1995;23:293-9.
 30. Challa JK, Gillies MC, Penfold PL, Gyory JF, Hunyor AB, Billson FA. Exudative macular degeneration and intravitreal triamcinolone: 18 month follow up. *Aust N Z J Ophthalmol* 1998;26:277-81.
 31. Danis RP, Ciulla TA, Pratt LM, Anliker W. Intravitreal triamcinolone acetonide in exudative age-related macular degeneration. *Retina* 2000;20:244.
 32. Penfold PL, Wong JG, Gyory J, Billson FA. Effects of triamcinolone acetonide of microglial morphology and quantitative expression on MHC II in exudative age-related macular degeneration. *Clin Exp Ophthalmol* 2001;29:188-92.
 33. McCuen BW II, Bessler M, Tano Y, Chandler D, Machermer R. The lack of toxicity of intravitreally administered triamcinolone acetonide. *Am J Ophthalmol* 1981;91:785-8.
-